

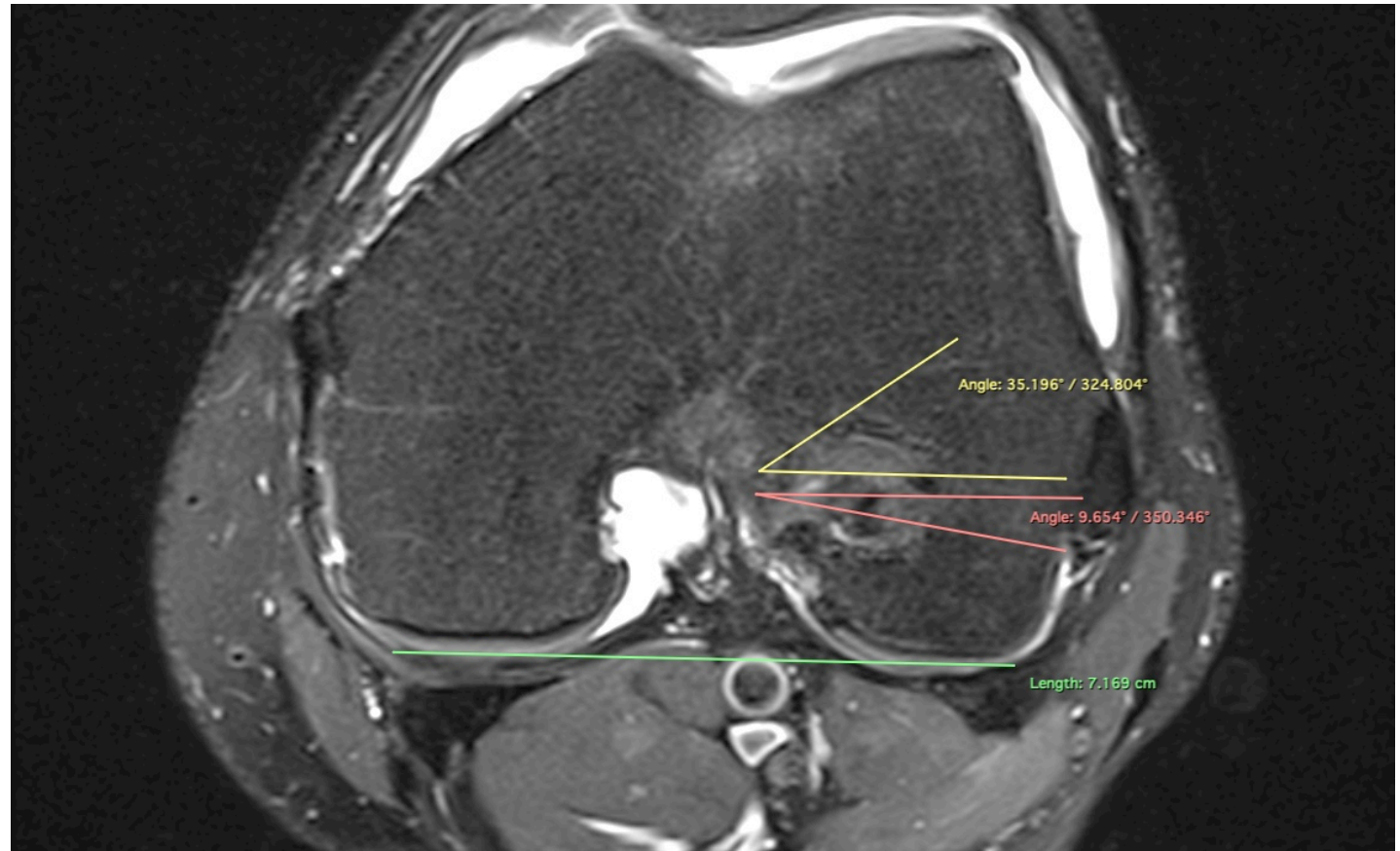
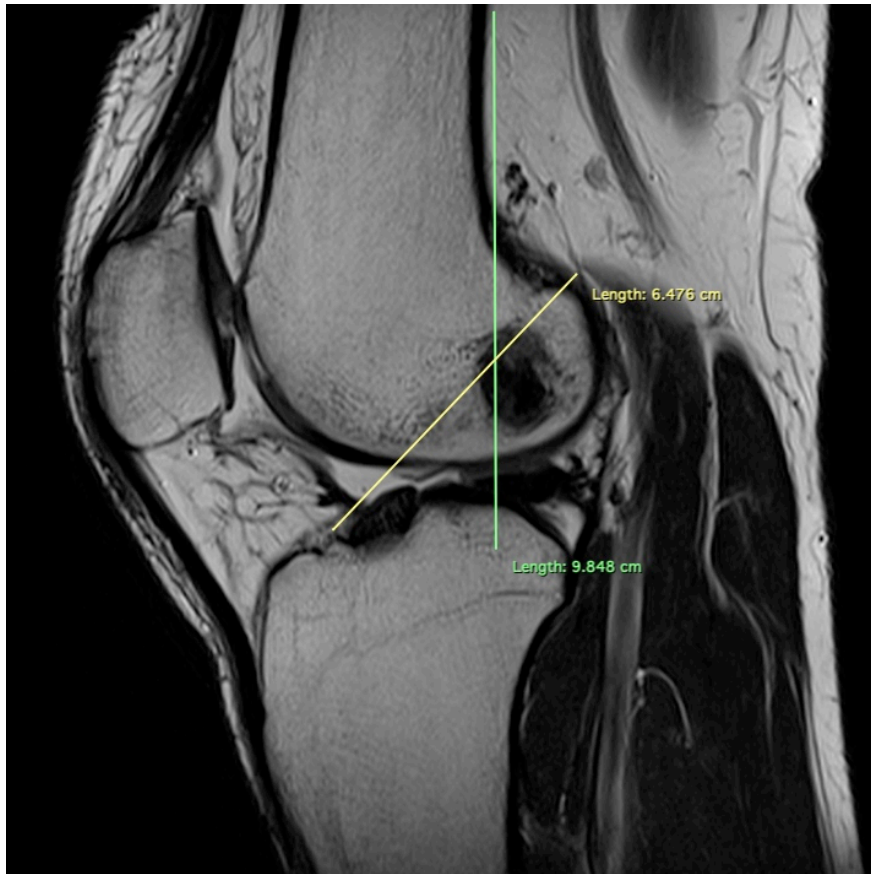
*ACL och PCL
graftbedömning*

PAWEŁ SZARO

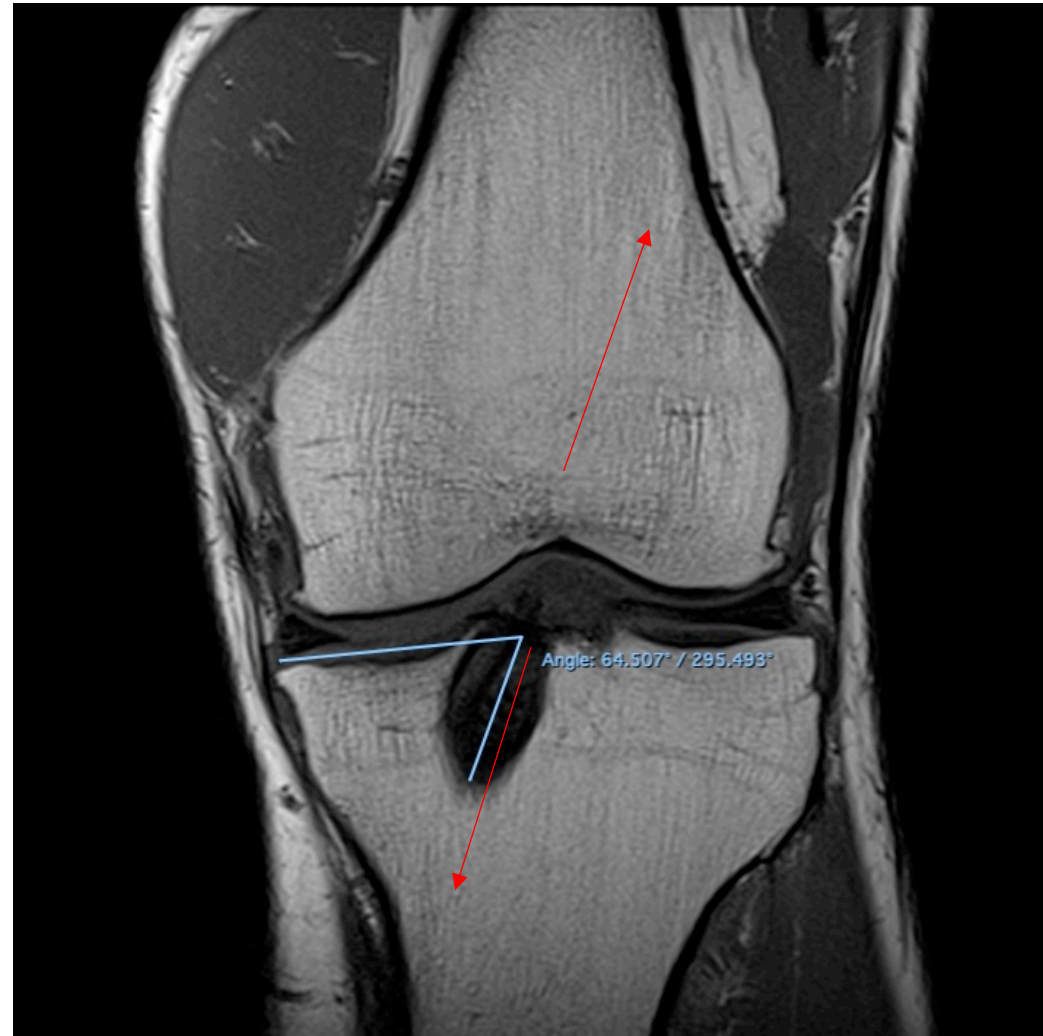
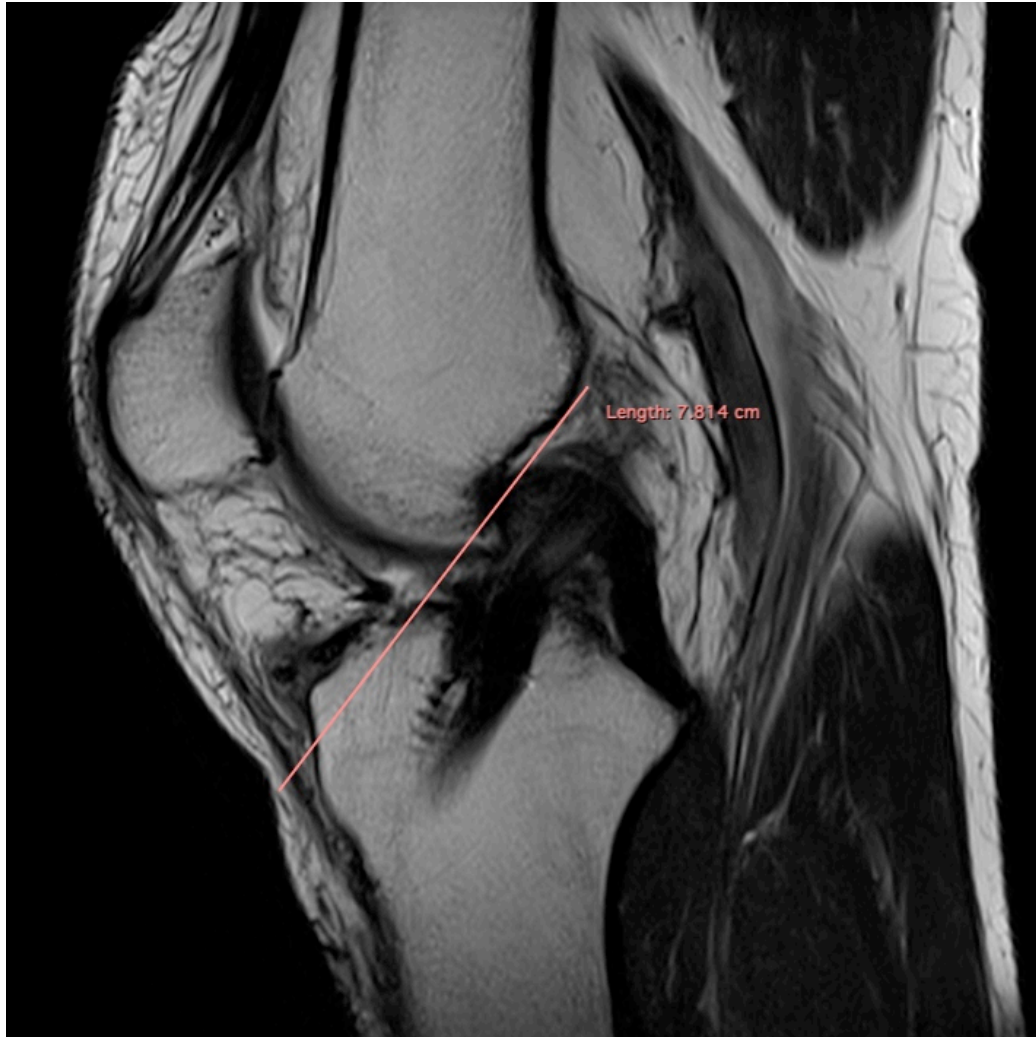Systematisk graftbedömning

- **G** Graft - remodeling och kontinuitet
- **T** Tunnel - läge, diameter?
- **D** Devices - läge?
- **D** Donor site - ganglion, infection?
- **M** Joint morphology - tibial slope?

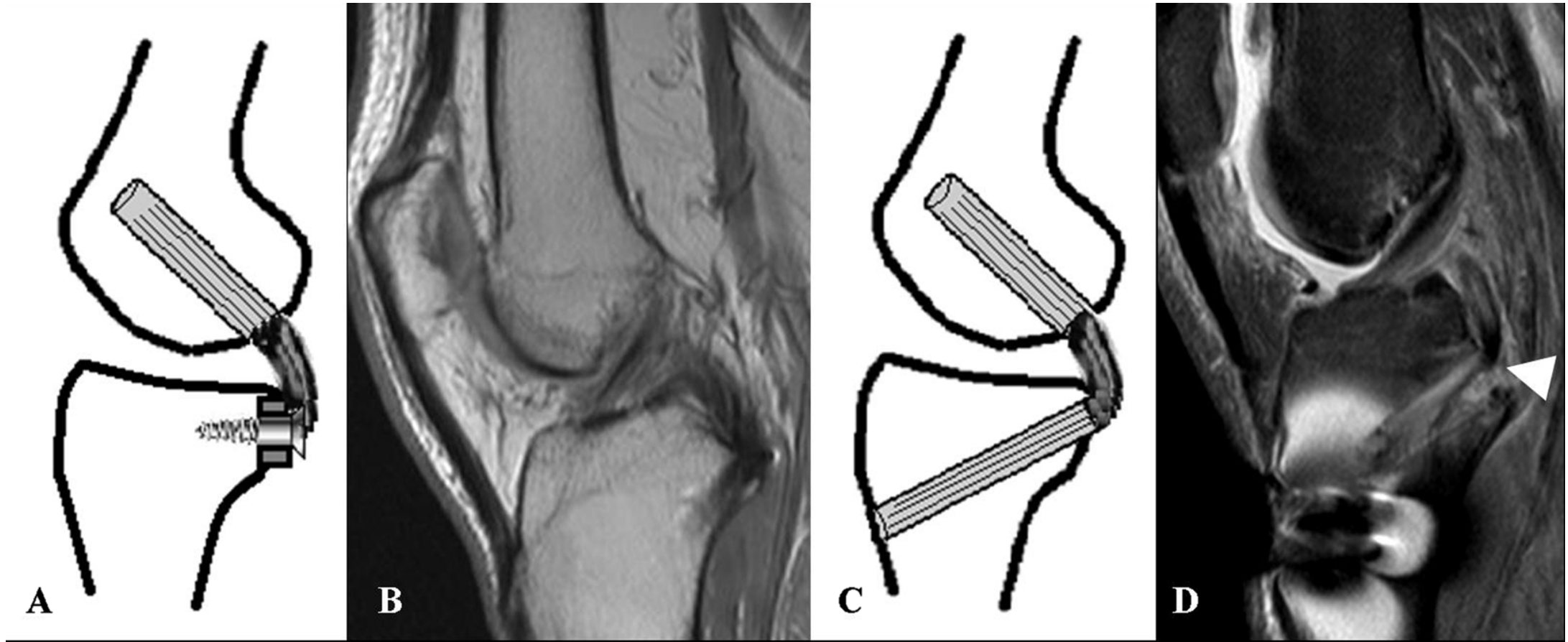
Graft ACL (femur)



Graft ACL (tibia)



GRAFT PCL



A

B

C

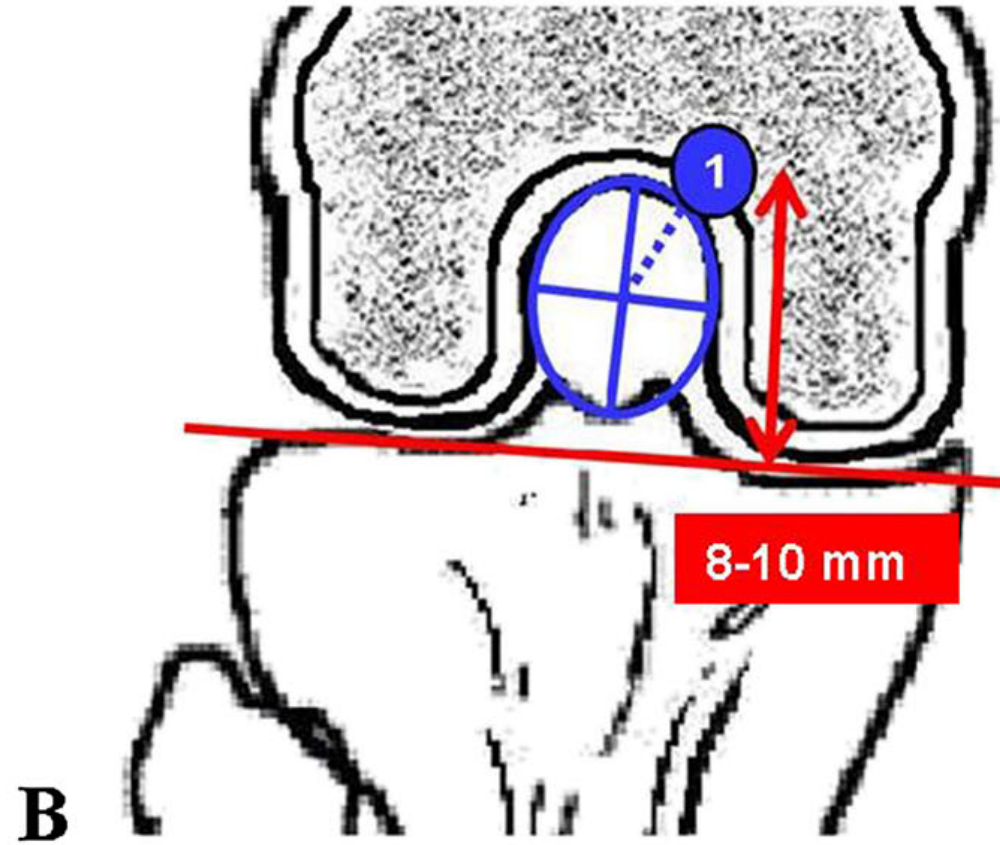
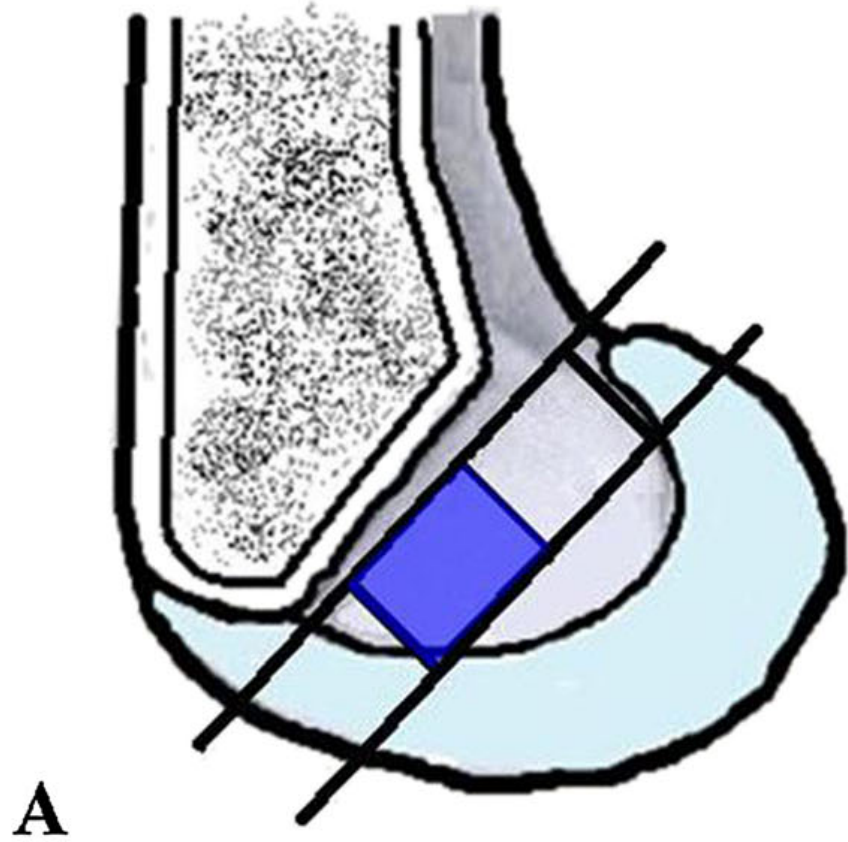
D

INLAY

TRANSTIBIAL
KILLER TURN!

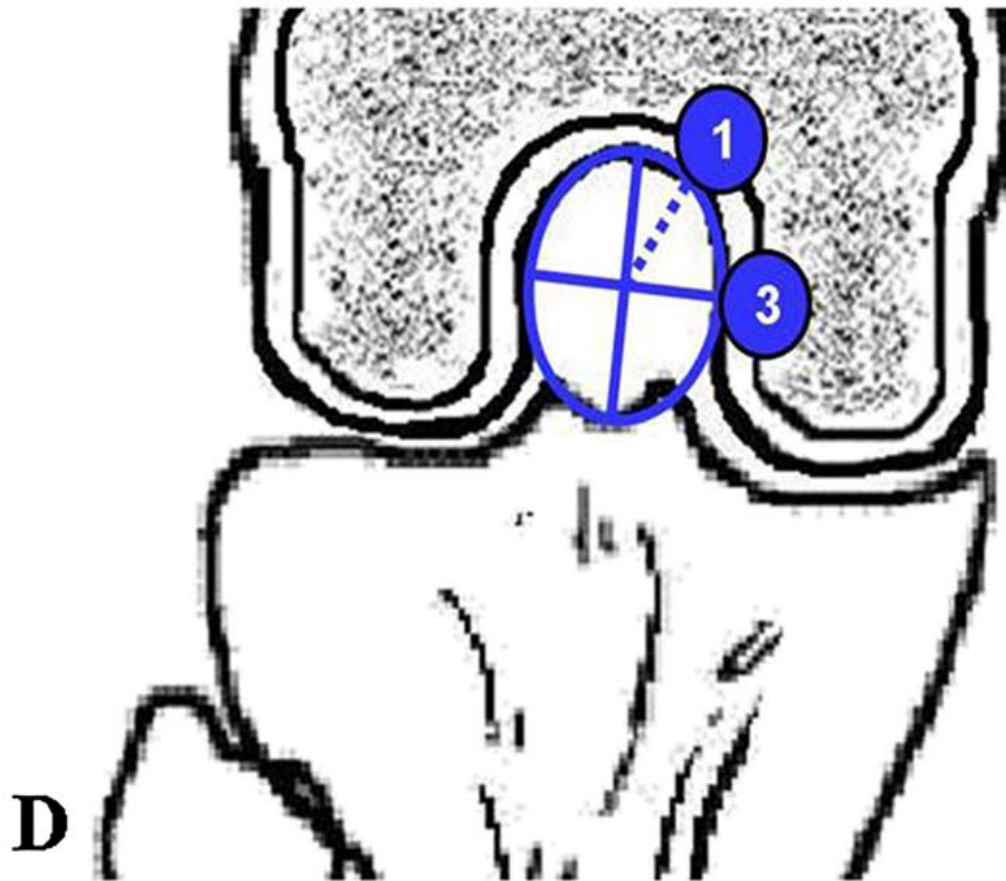
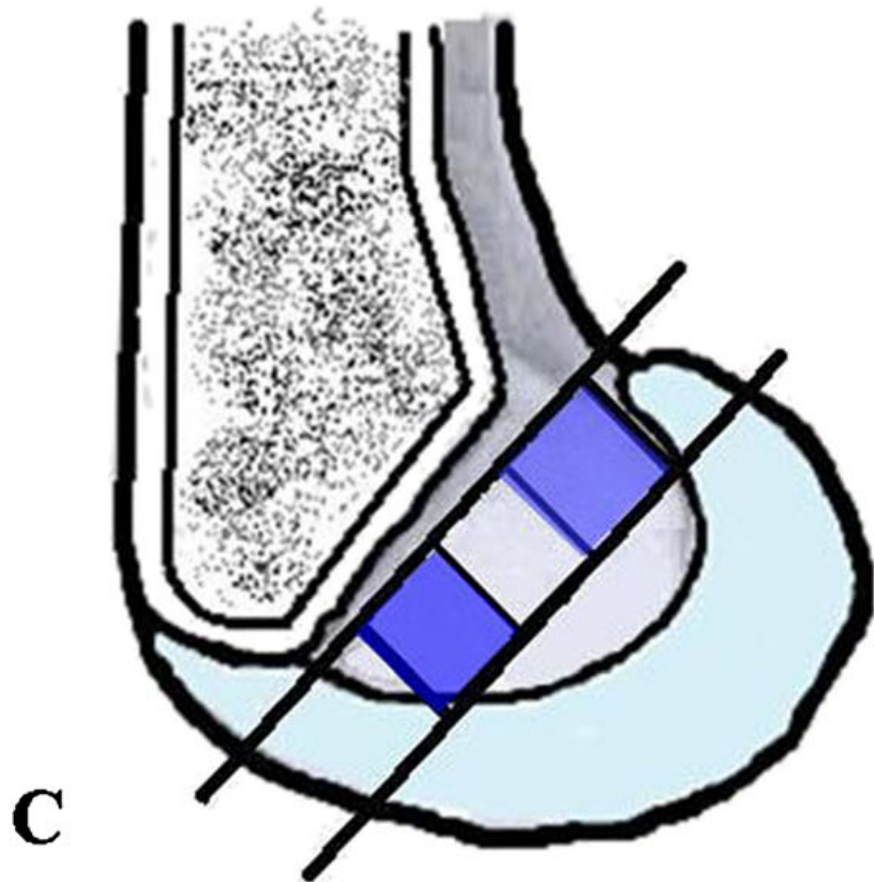
FEMUR

T

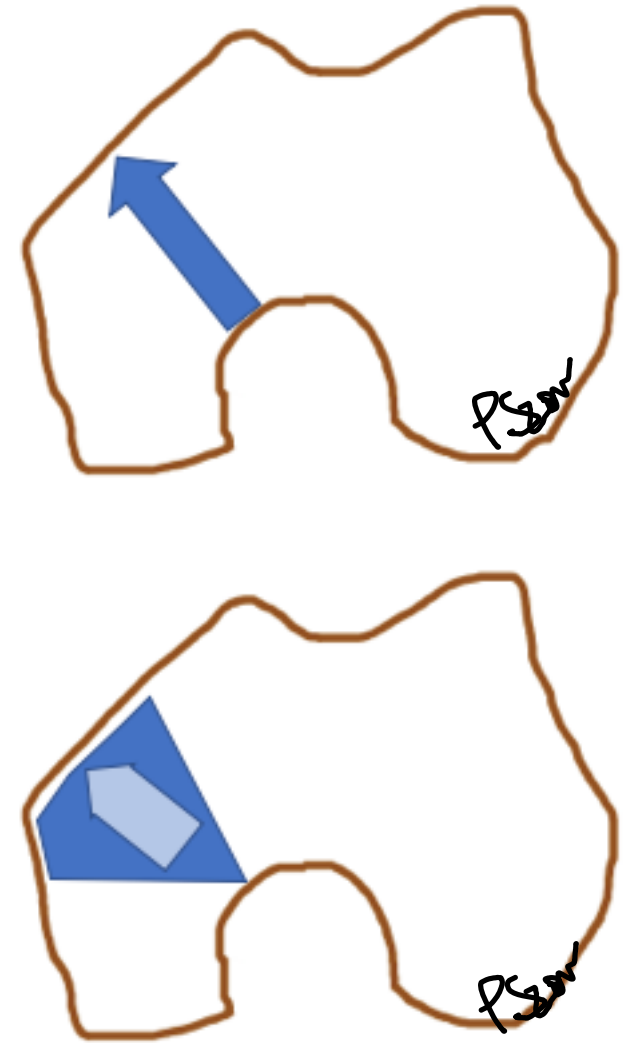
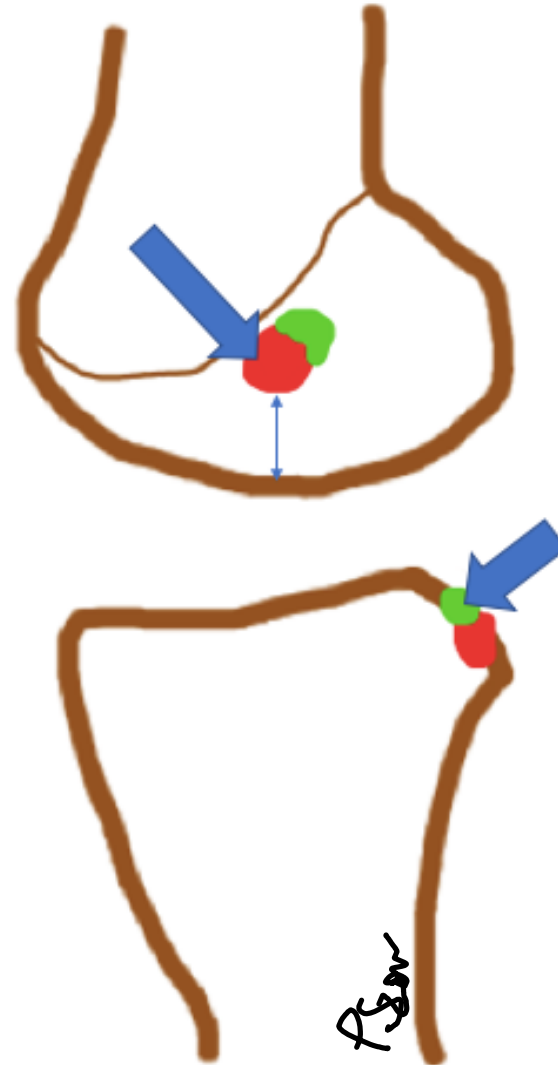
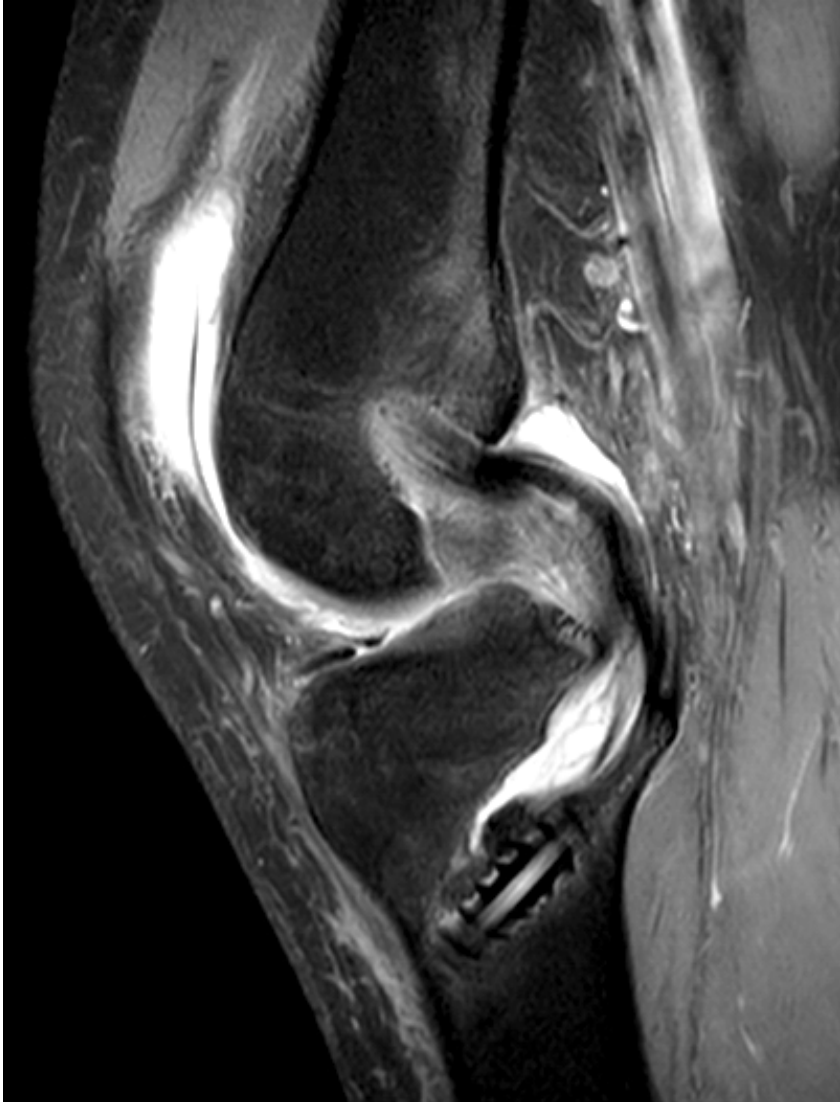

FEMUR *PCL*

T



FEMUR PCL



T

TIBIA PCL

