

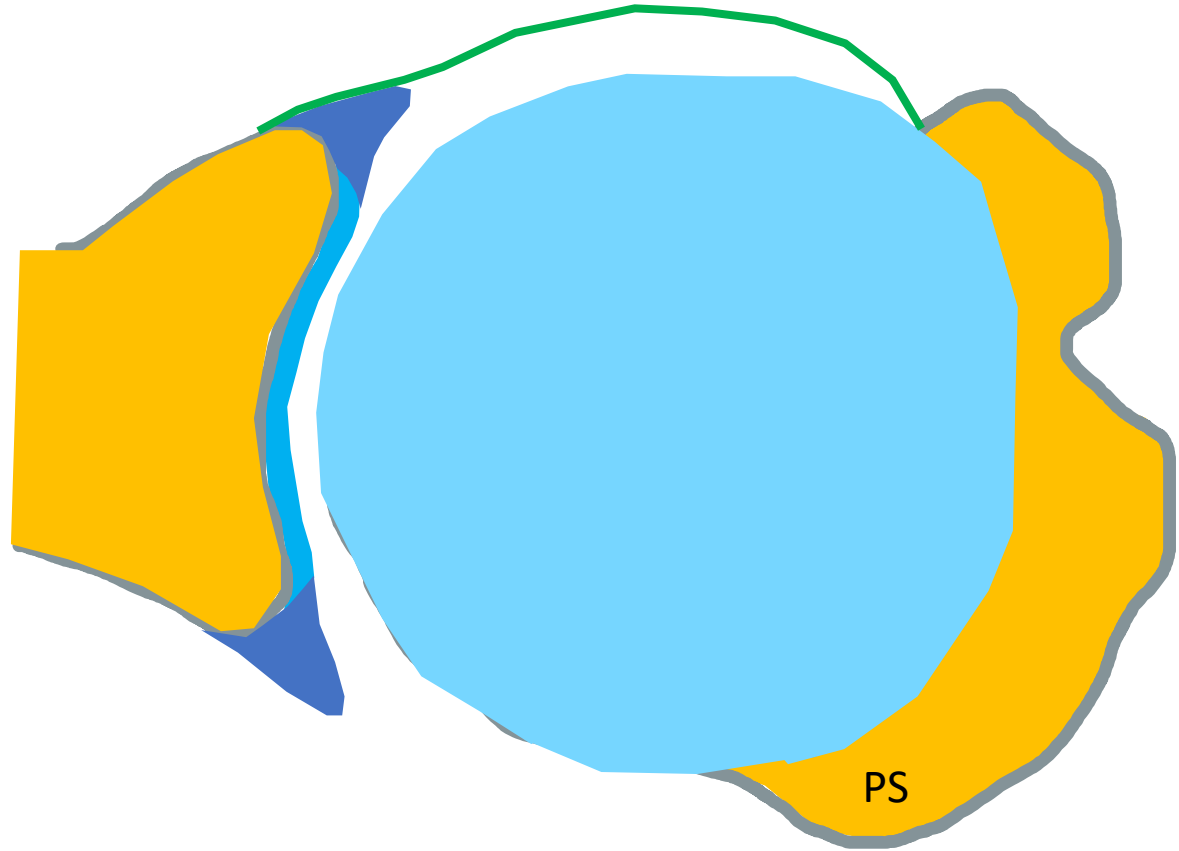


Anterior shoulder instability

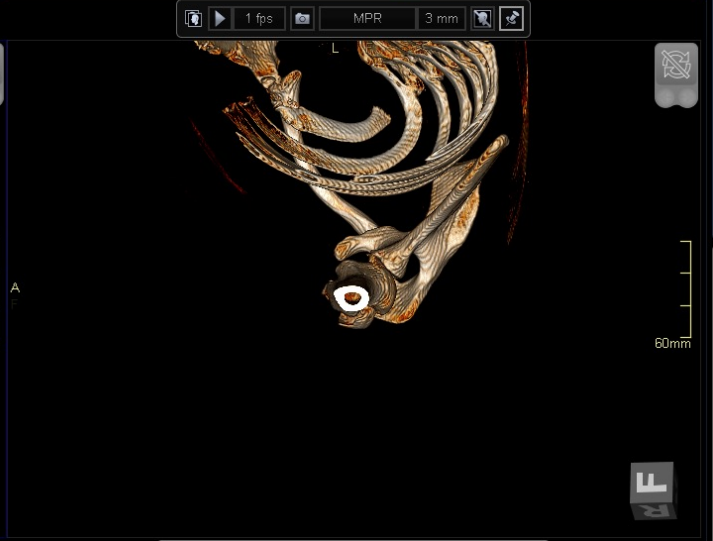
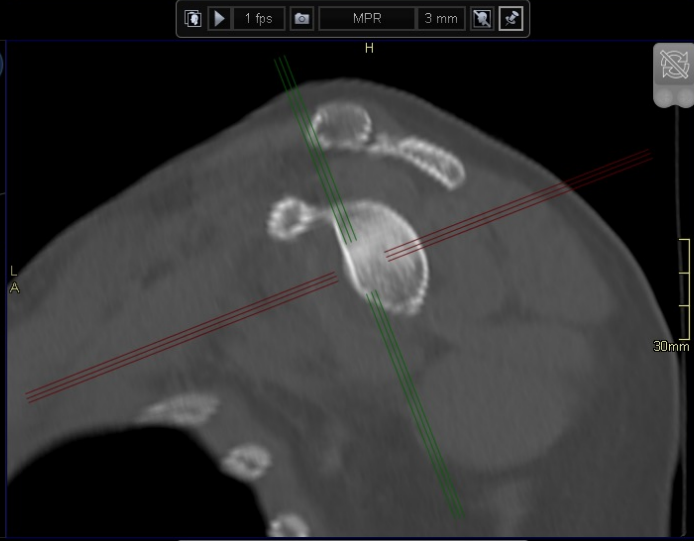
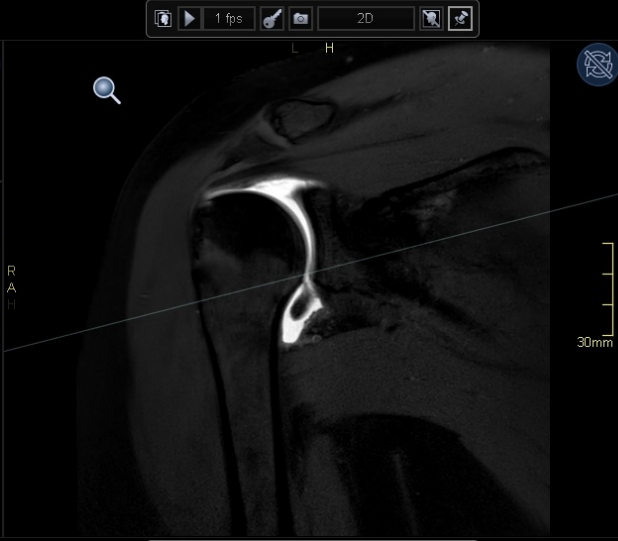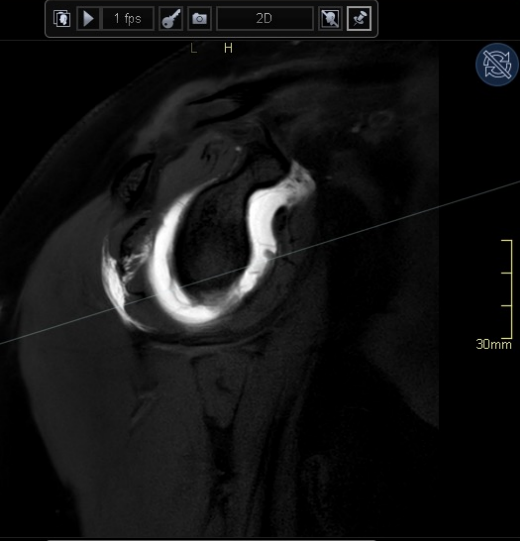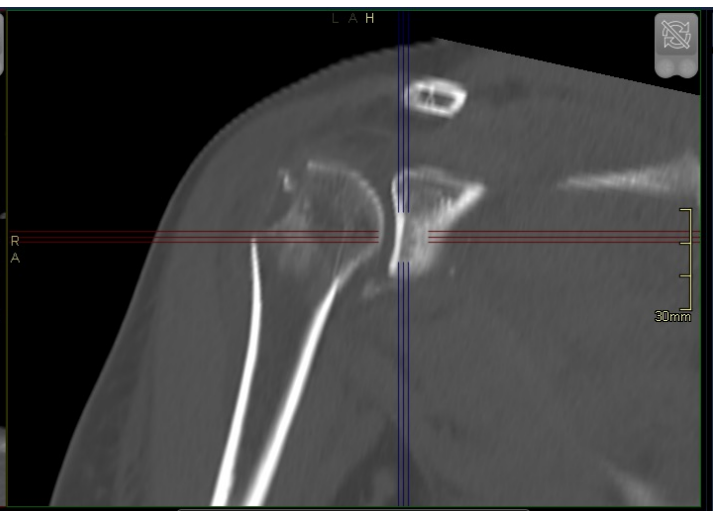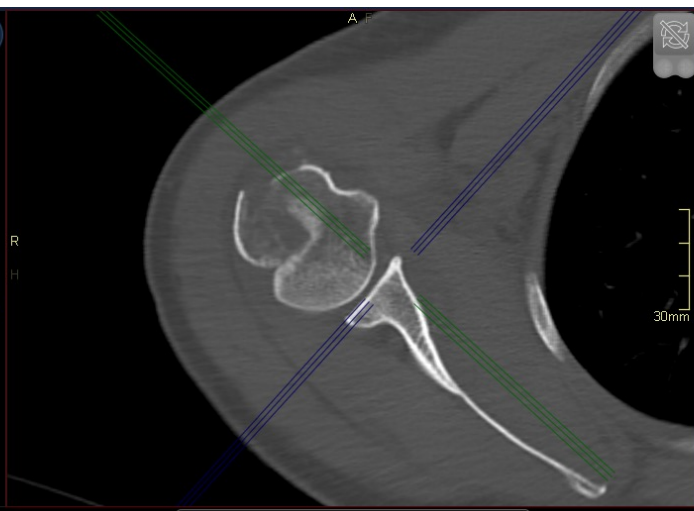
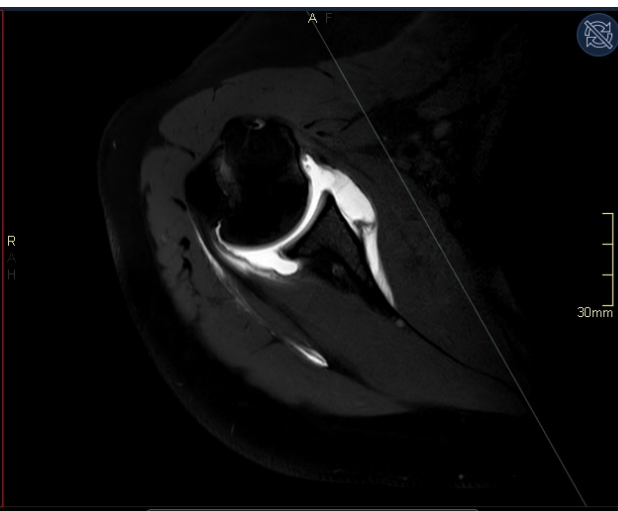
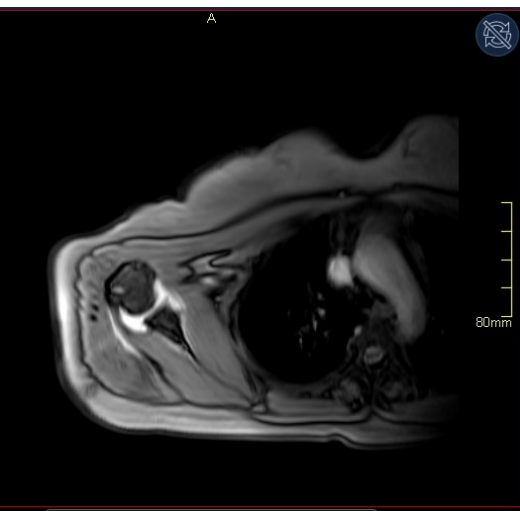
Pawel Szaro

Anterior instability

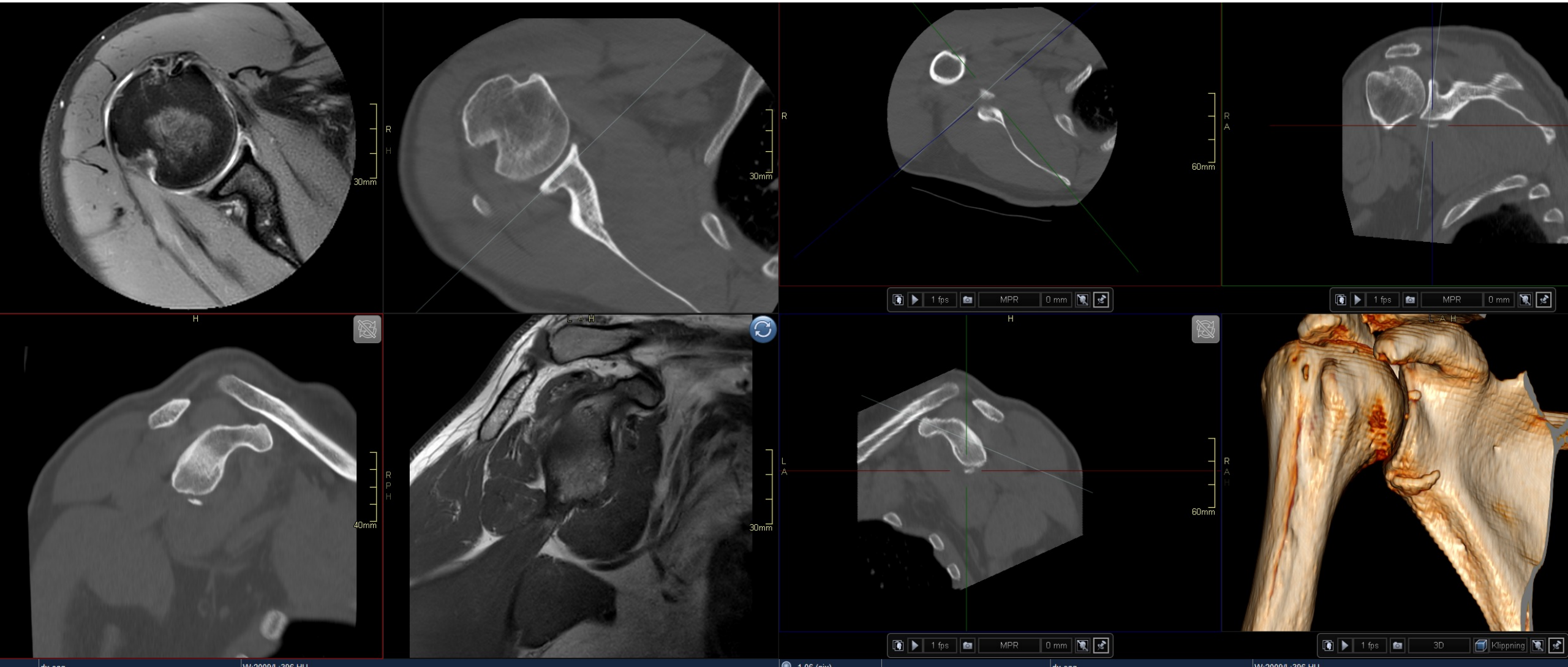
Acute?



Chronic?



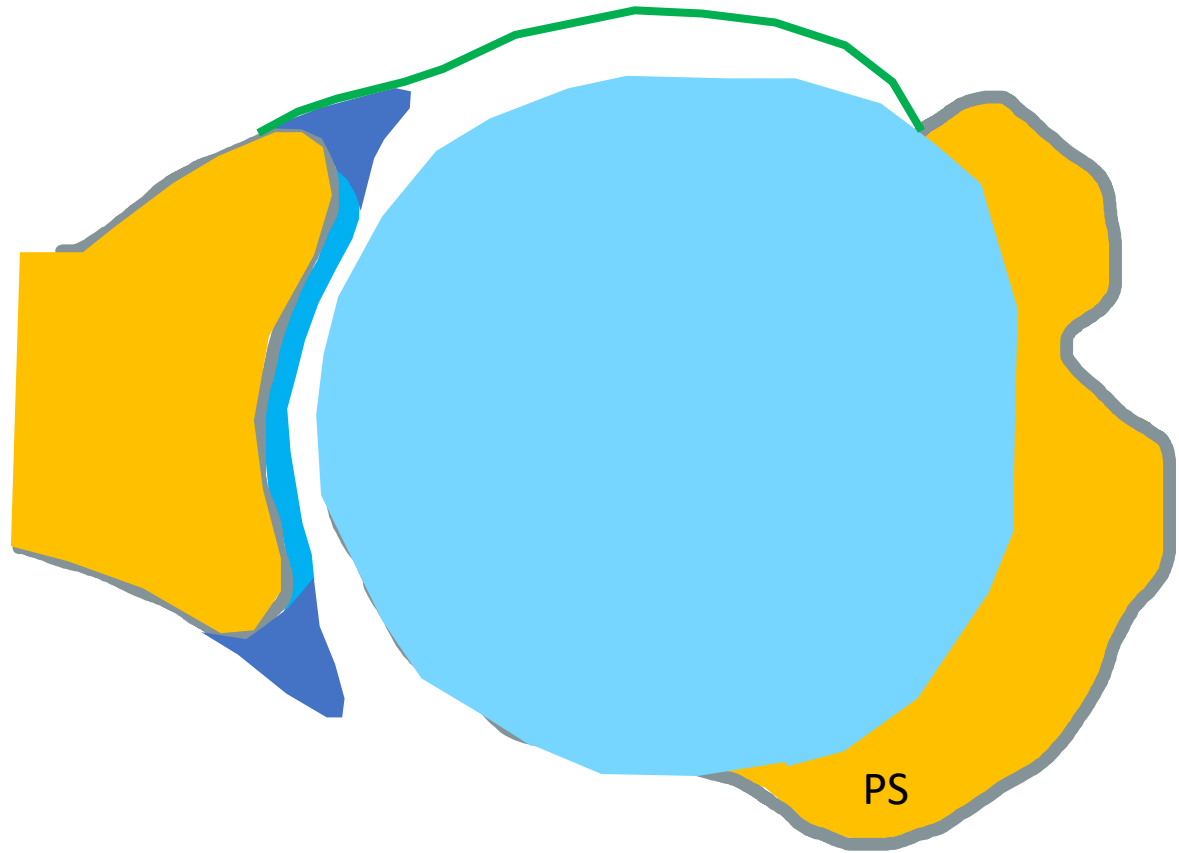
Anterior instability

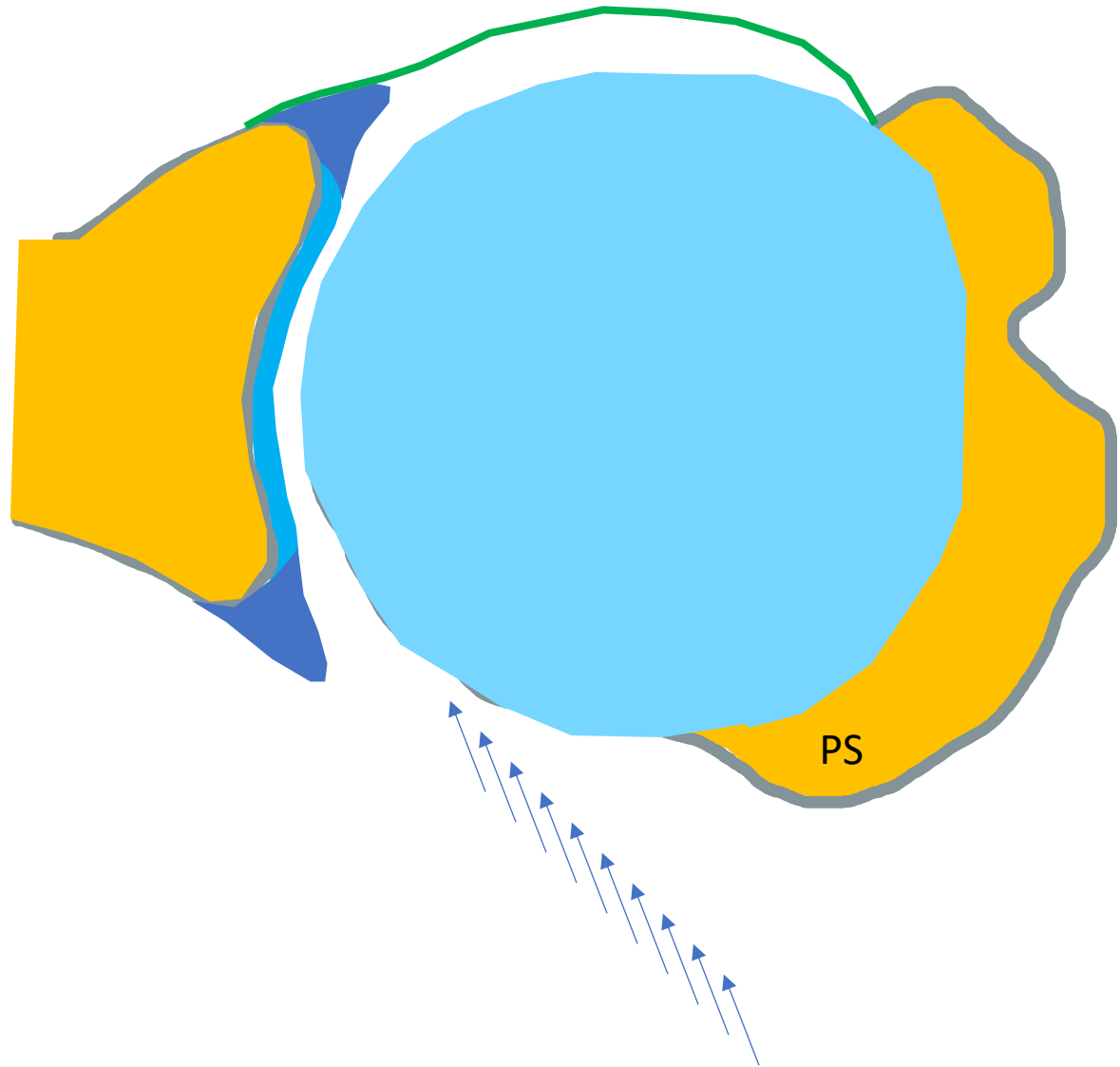


Labral lesions

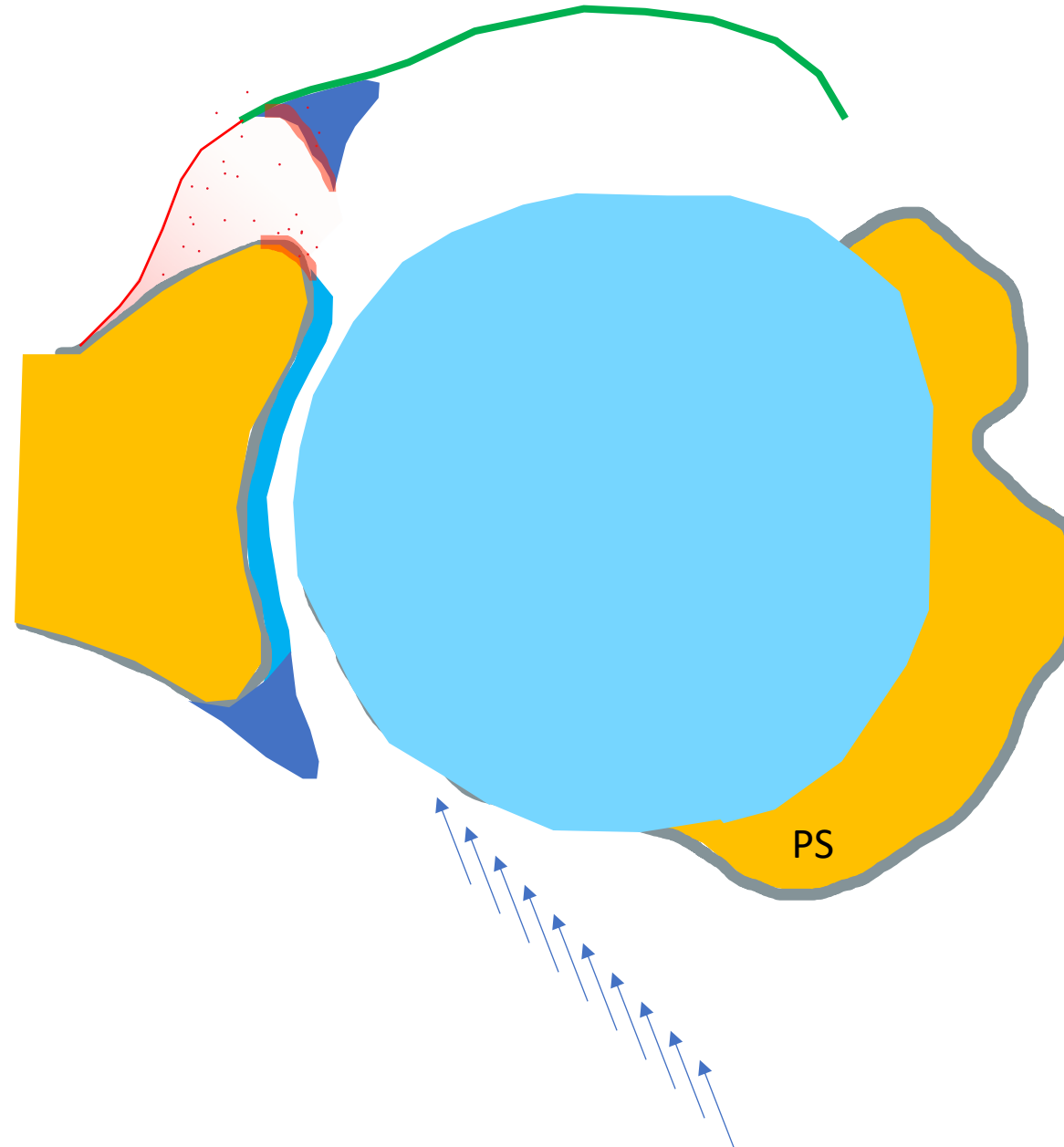
- Bankart lesion
- bony Bankart lesion

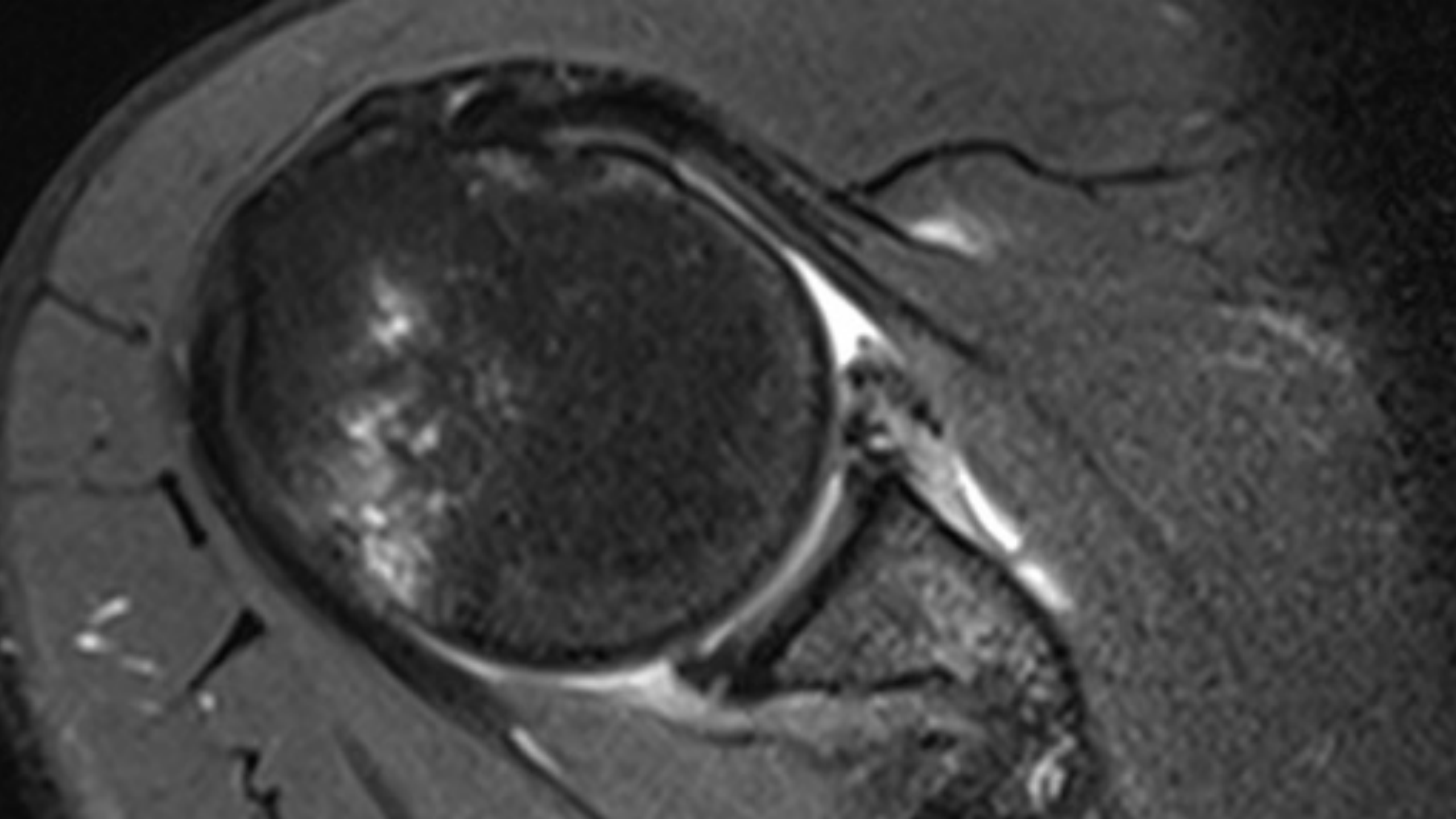
- anterior labroligamentous periosteal sleeve avulsion (ALPSA)
- Perthes lesion
- glenolabral articular disruption (GLAD)
- humeral avulsion of the glenohumeral ligament (HAGL)
- bony humeral avulsion of the glenohumeral ligament (BHAGL)

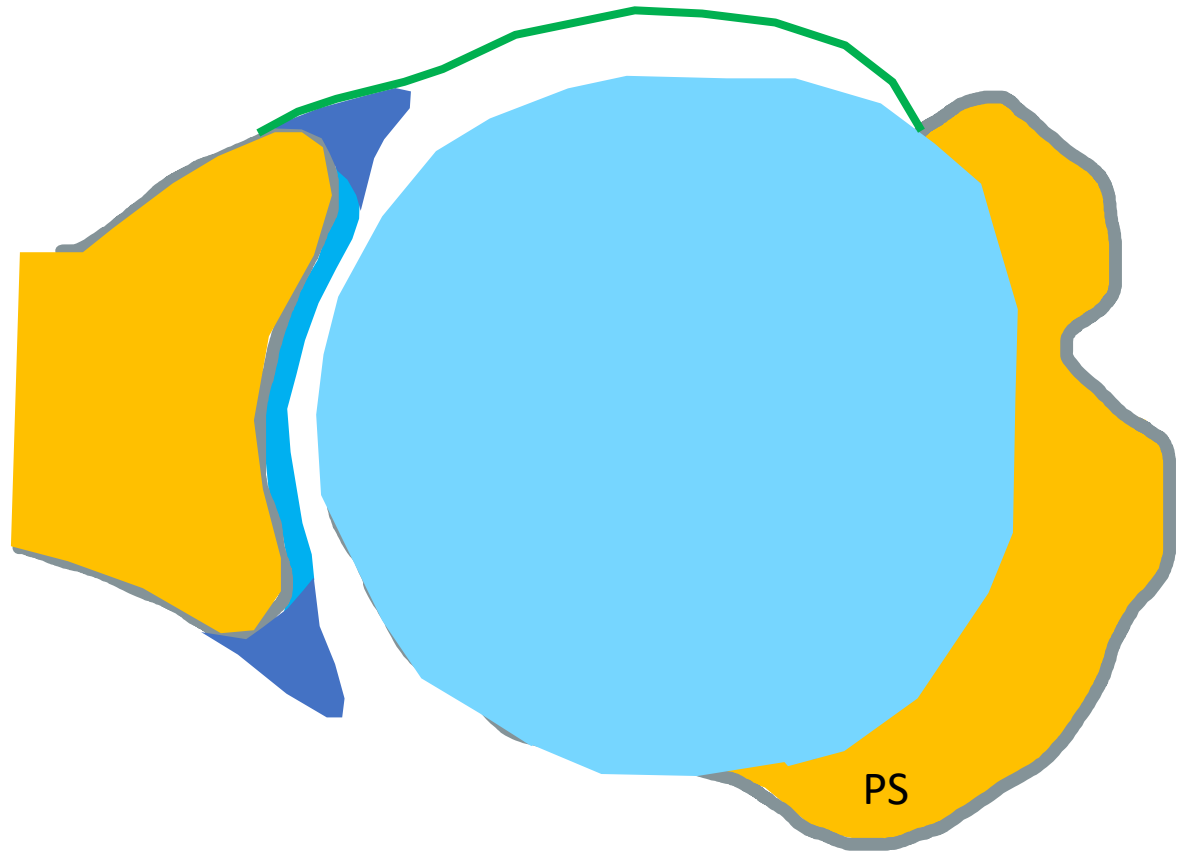


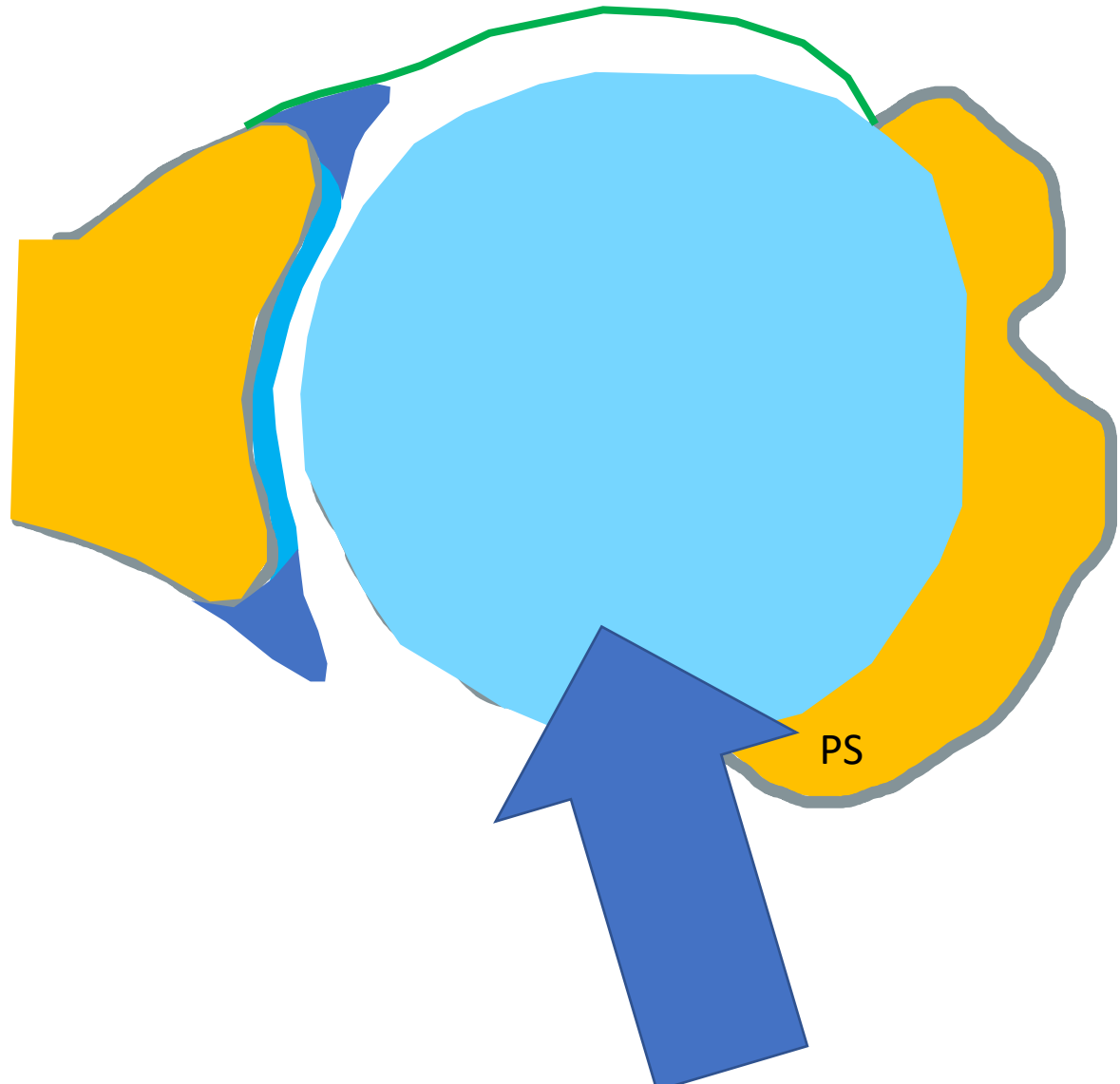


Anterior labroligamentous periosteal sleeve avulsion lesion

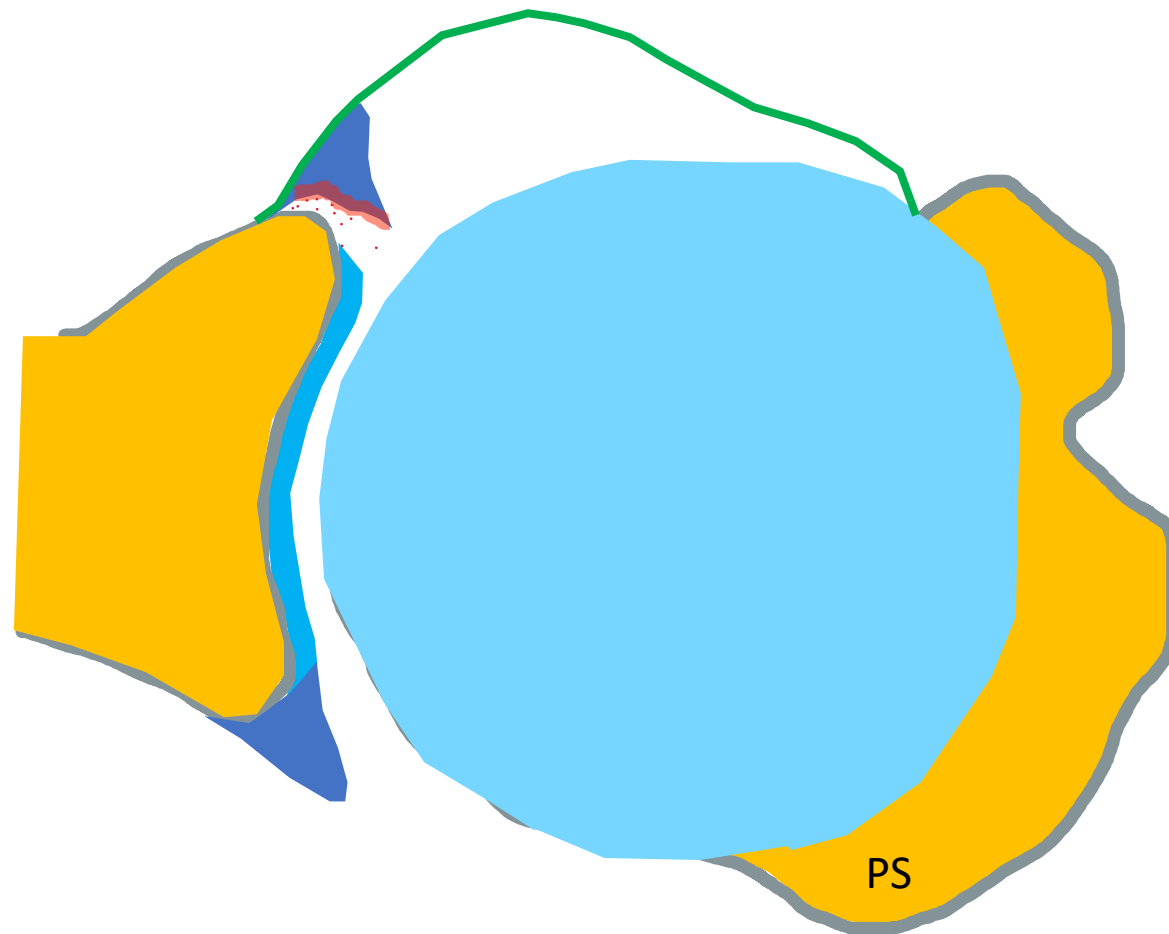


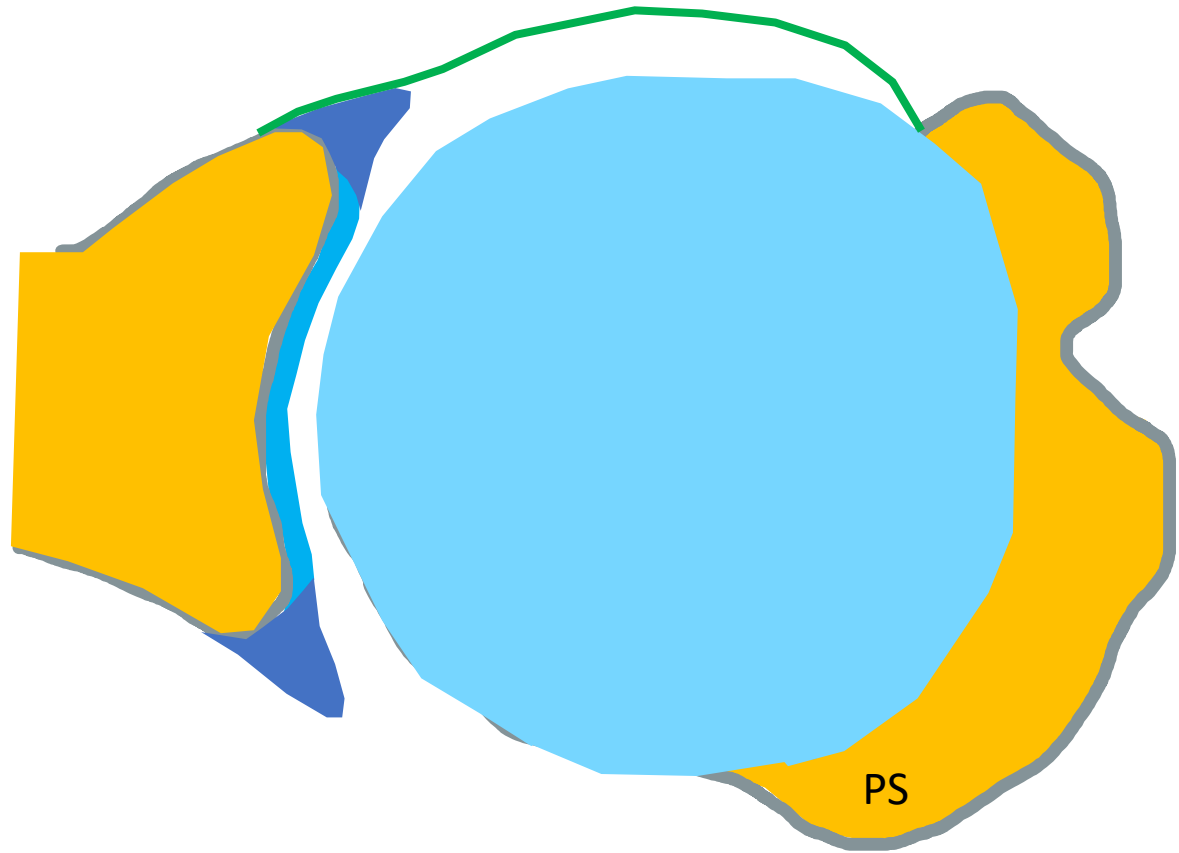


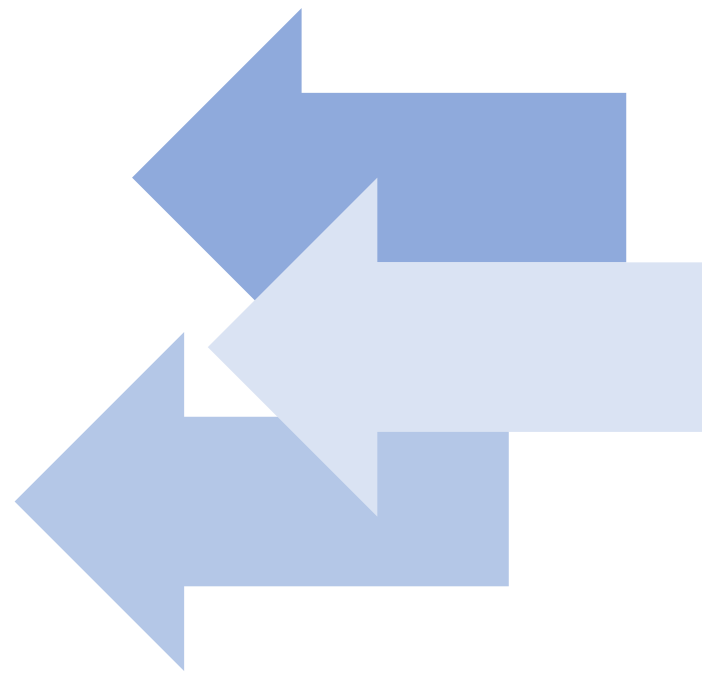
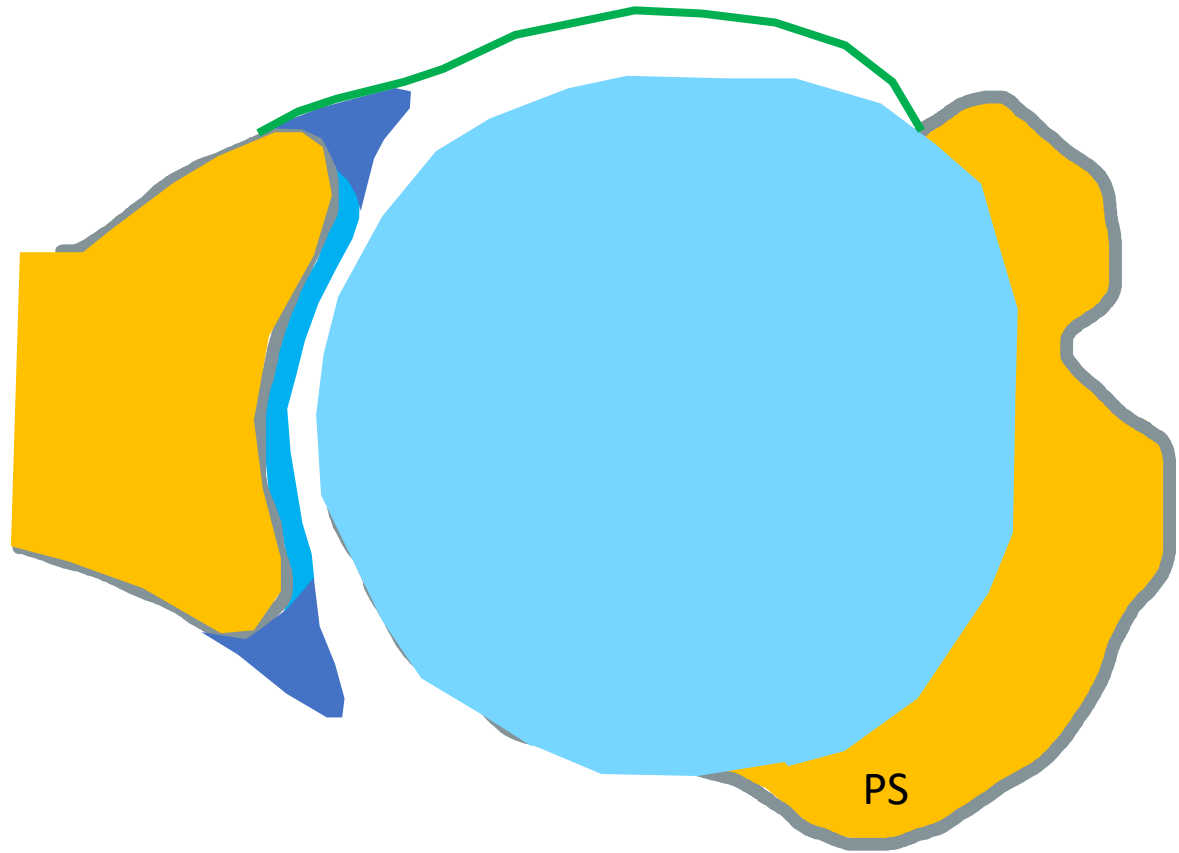




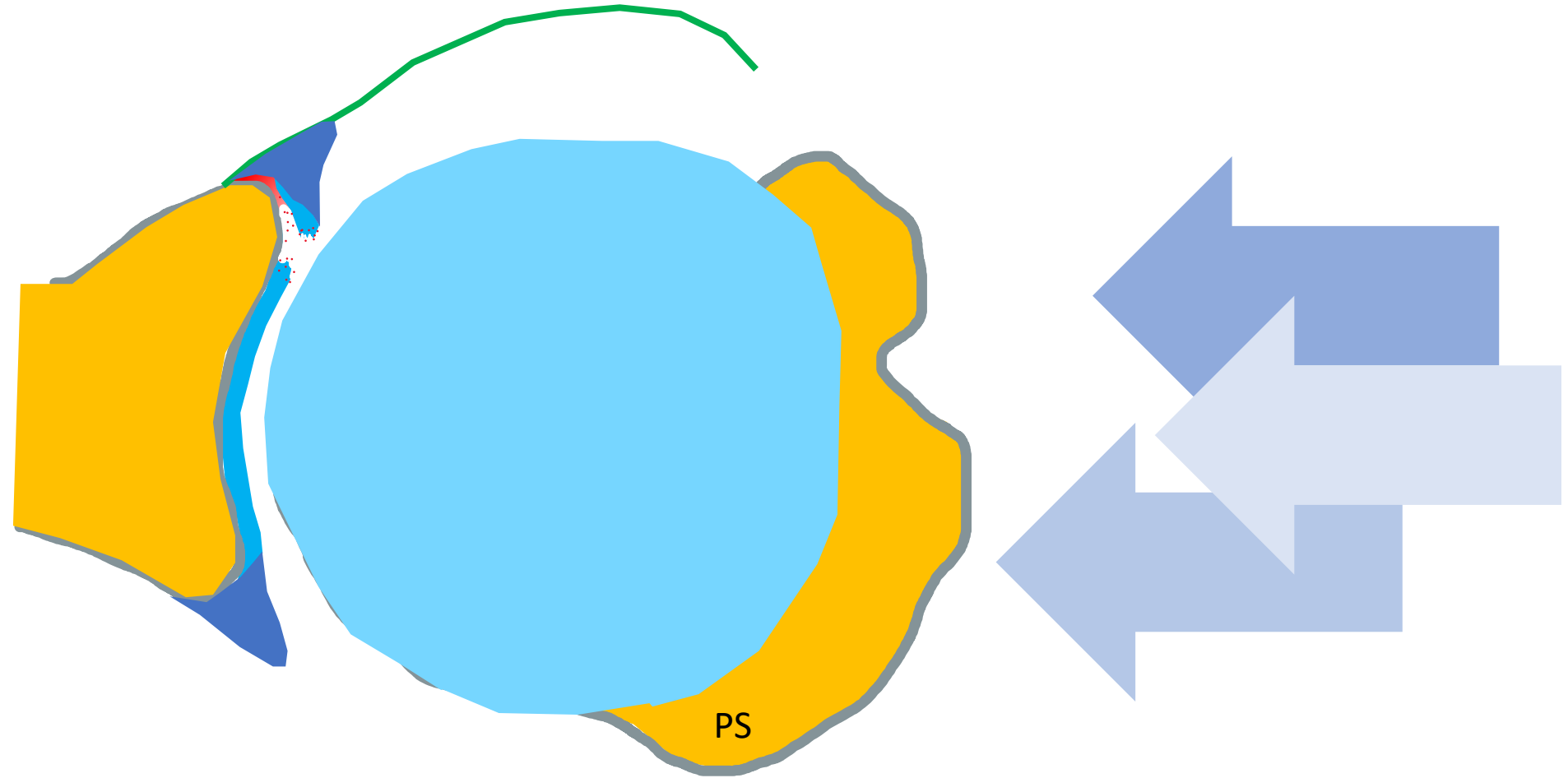
Perthes lesion

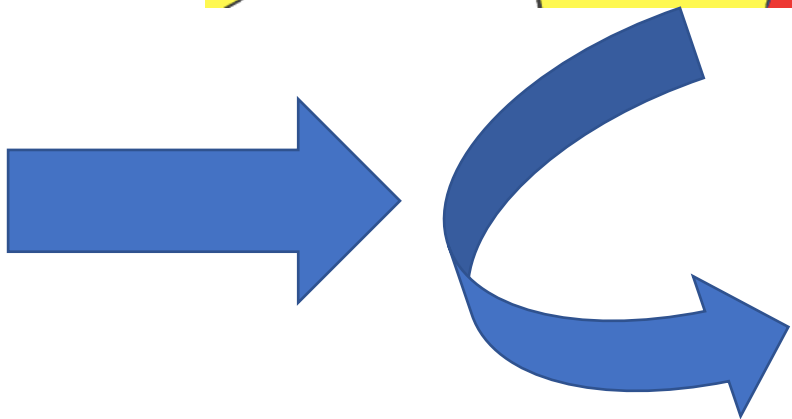
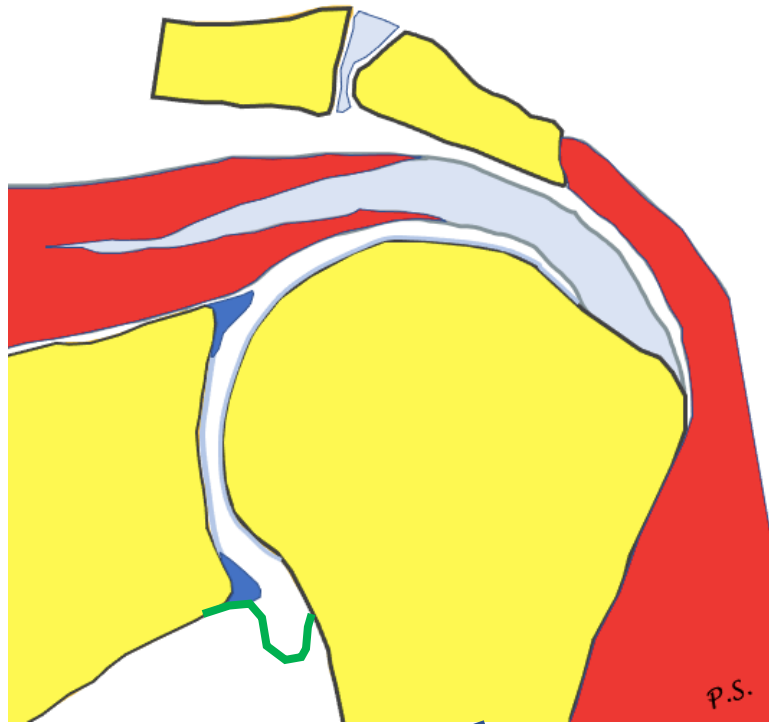




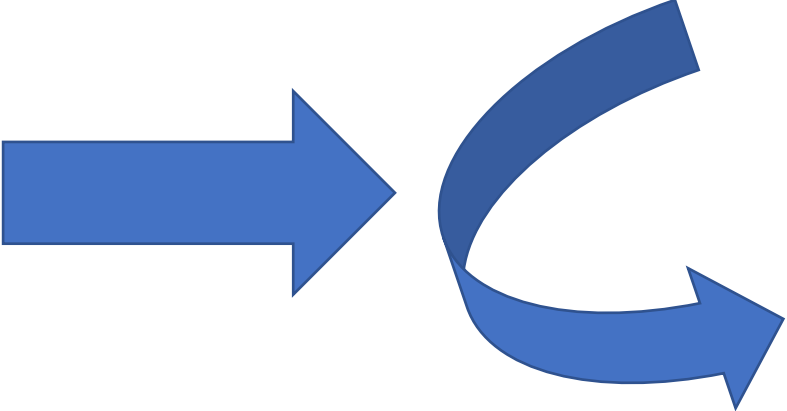
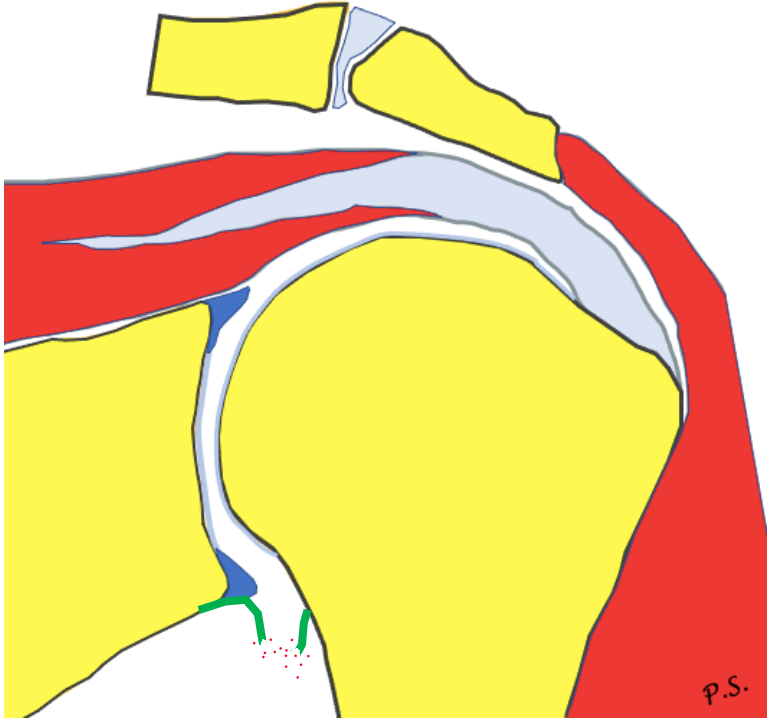
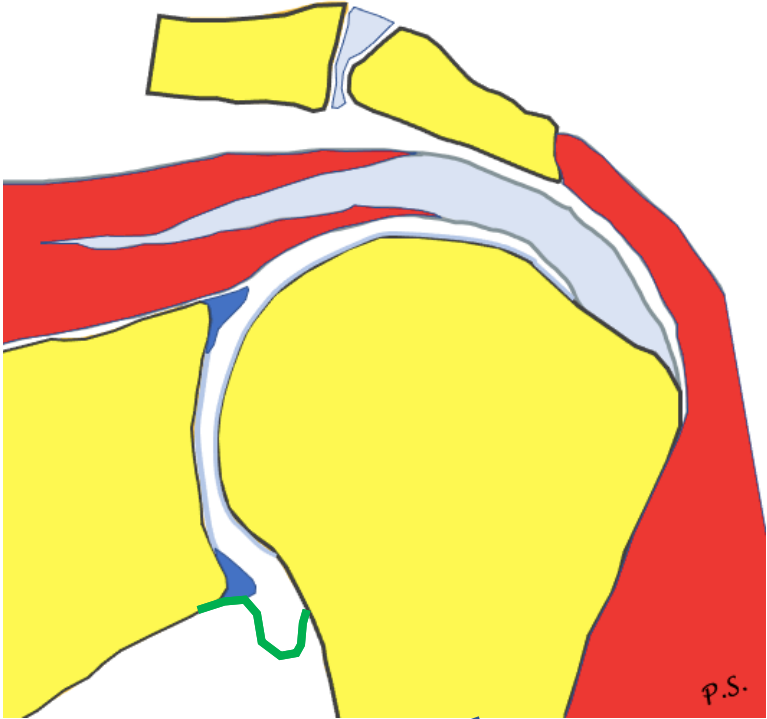


Glenolabral articular disruption lesion





Humeral avulsion of the glenohumeral ligament



Periosteal involvement

Bony Bankart

Anterior labroligamentous
periosteal sleeve avulsion
lesion ALPSA

No periosteal involvement

Glenolabral articular
disruption lesion GLAD

Soft tissue Bankart
Perthes lesion

Chondral or osteochondral
involvement

No chondral or osteochondral
involvement

Periosteal involvement

No periosteal involvement

Bony Bankart ^{AC}

Glenolabral articular
disruption lesion GLAD ^A

Anterior labroligamentous
periosteal sleeve avulsion
lesion ALPSA ^C

Soft tissue Bankart ^{AC}
Perthes lesion ^A

Chondral or osteochondral
involvement

No chondral or osteochondral
involvement

A- acute, C- chronic