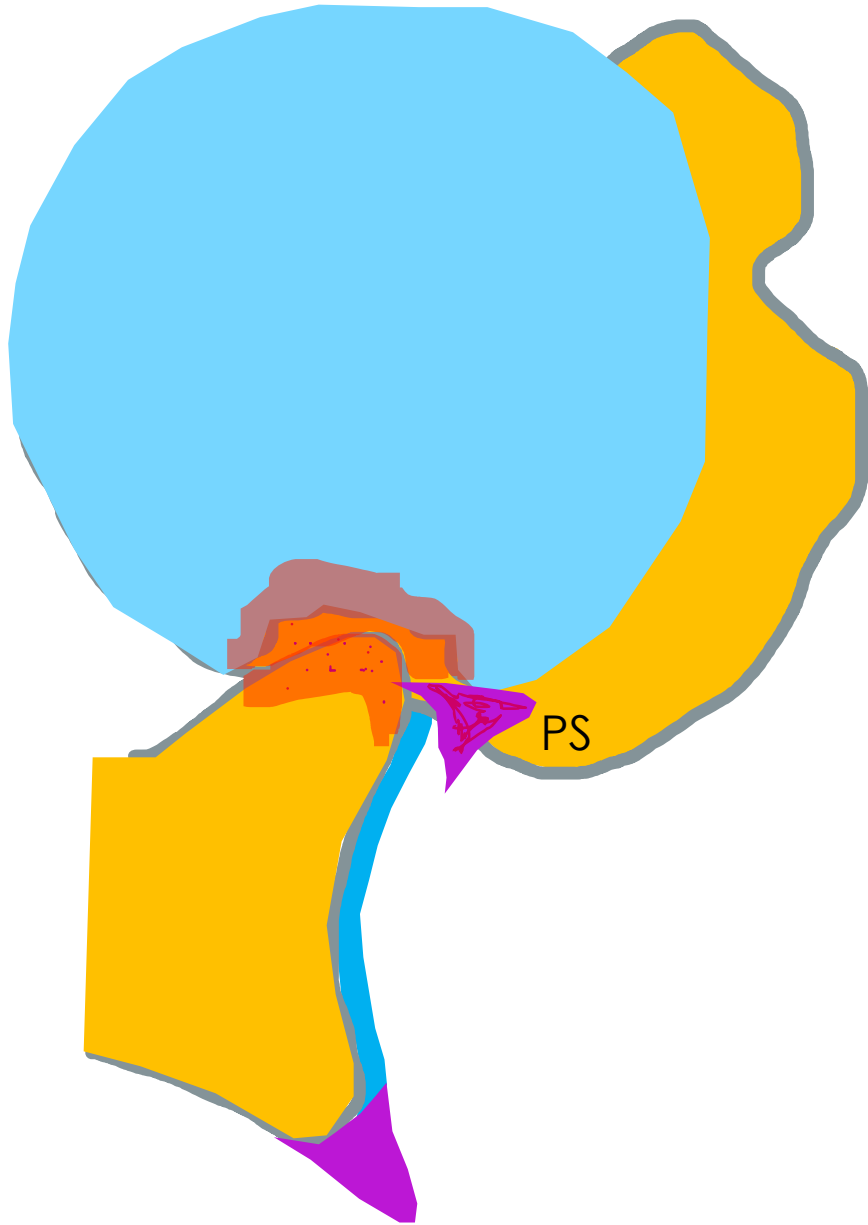

Bankart lesion

Pawel Szaro

Dislocation of the shoulder joint occurs in 1 to 2% of the population

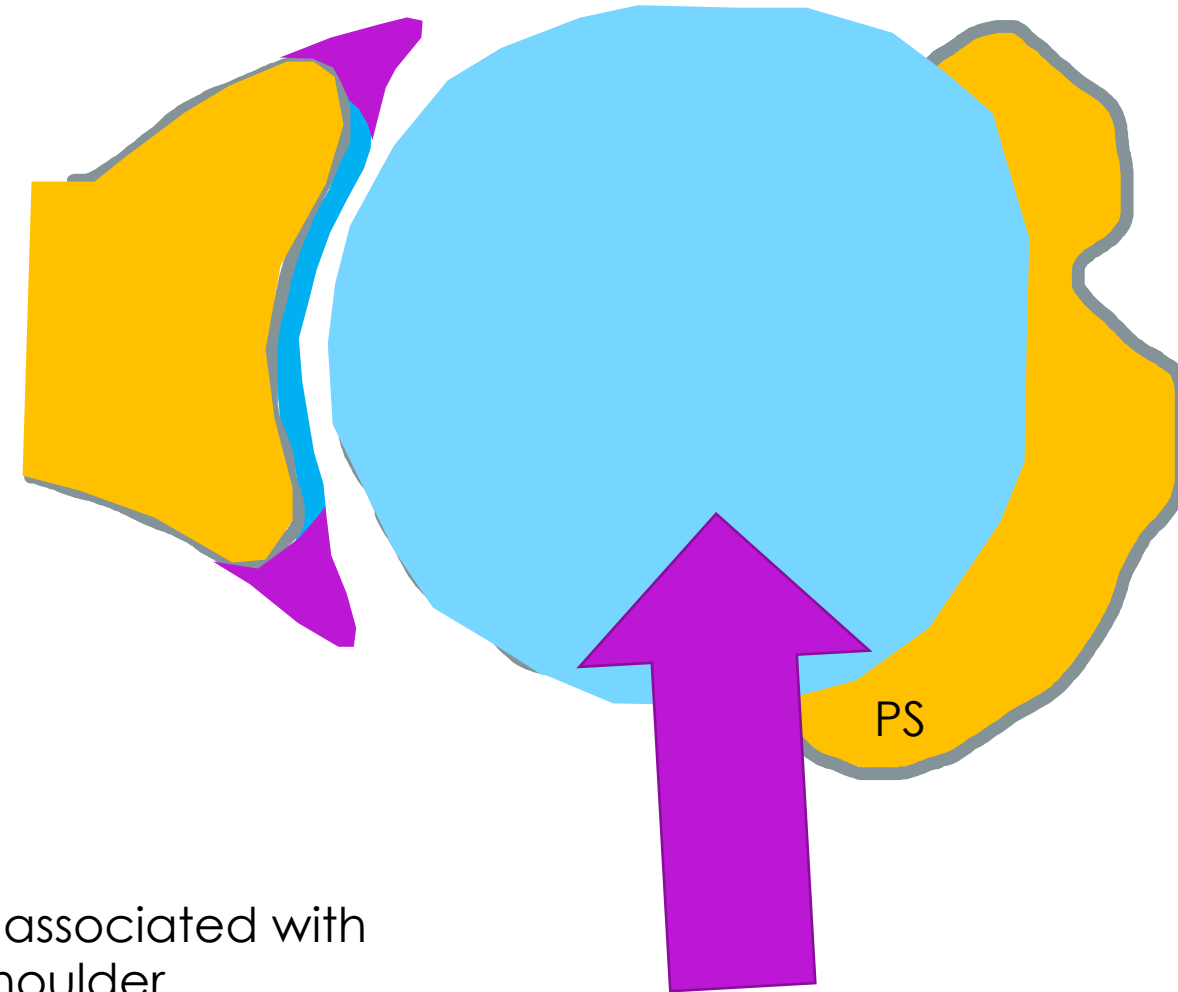
90% of shoulder dislocations are anterior dislocations, most of them are traumatic dislocations

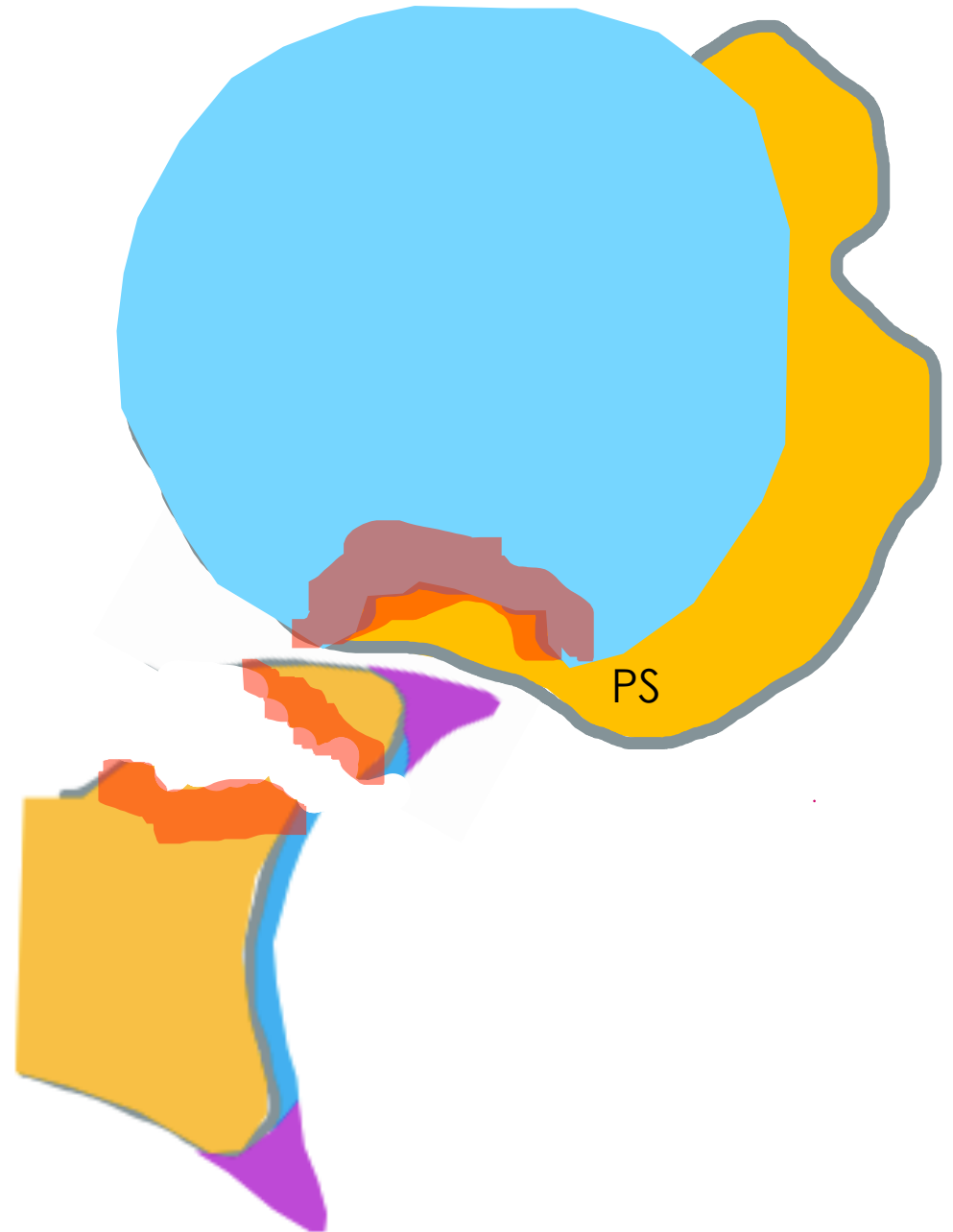
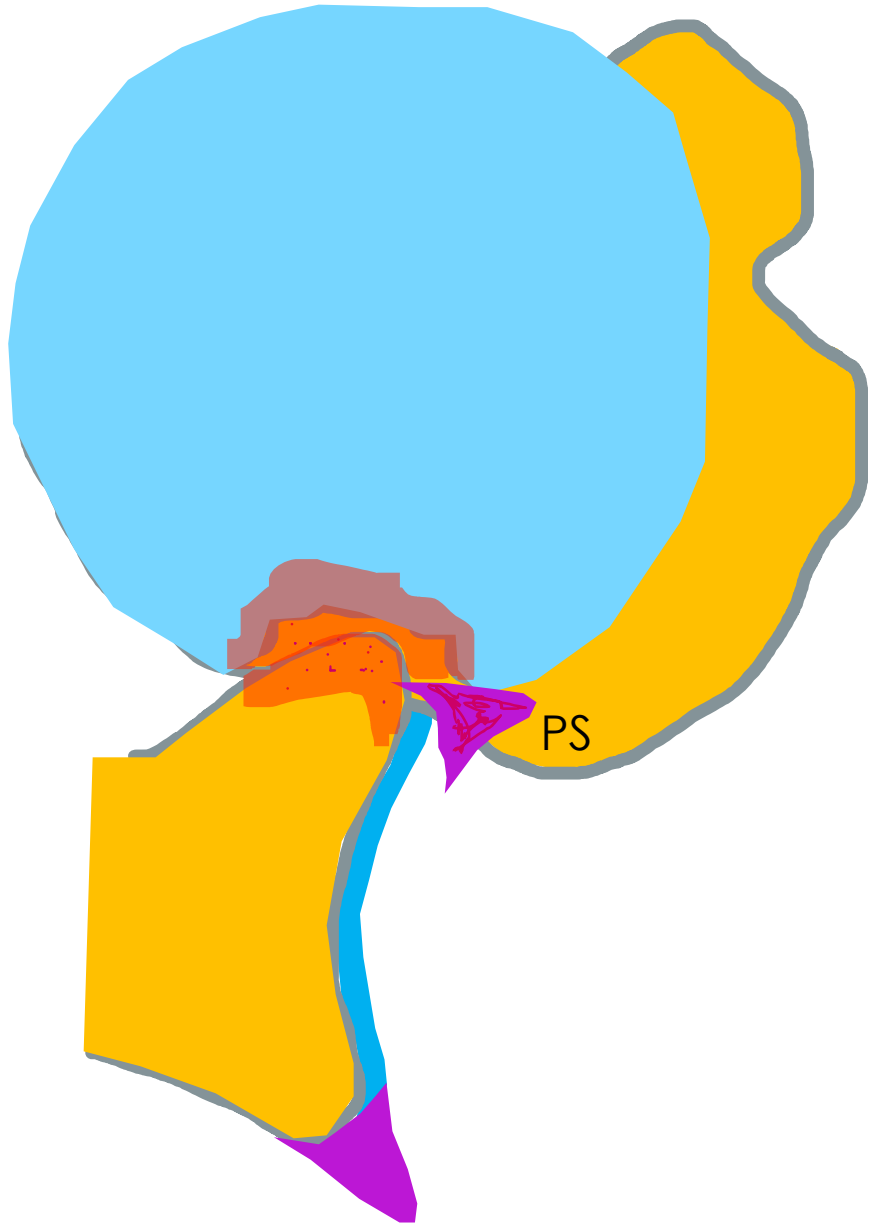
In athletic patients under the age of 20 years, the recurrence rates are greater than 90%

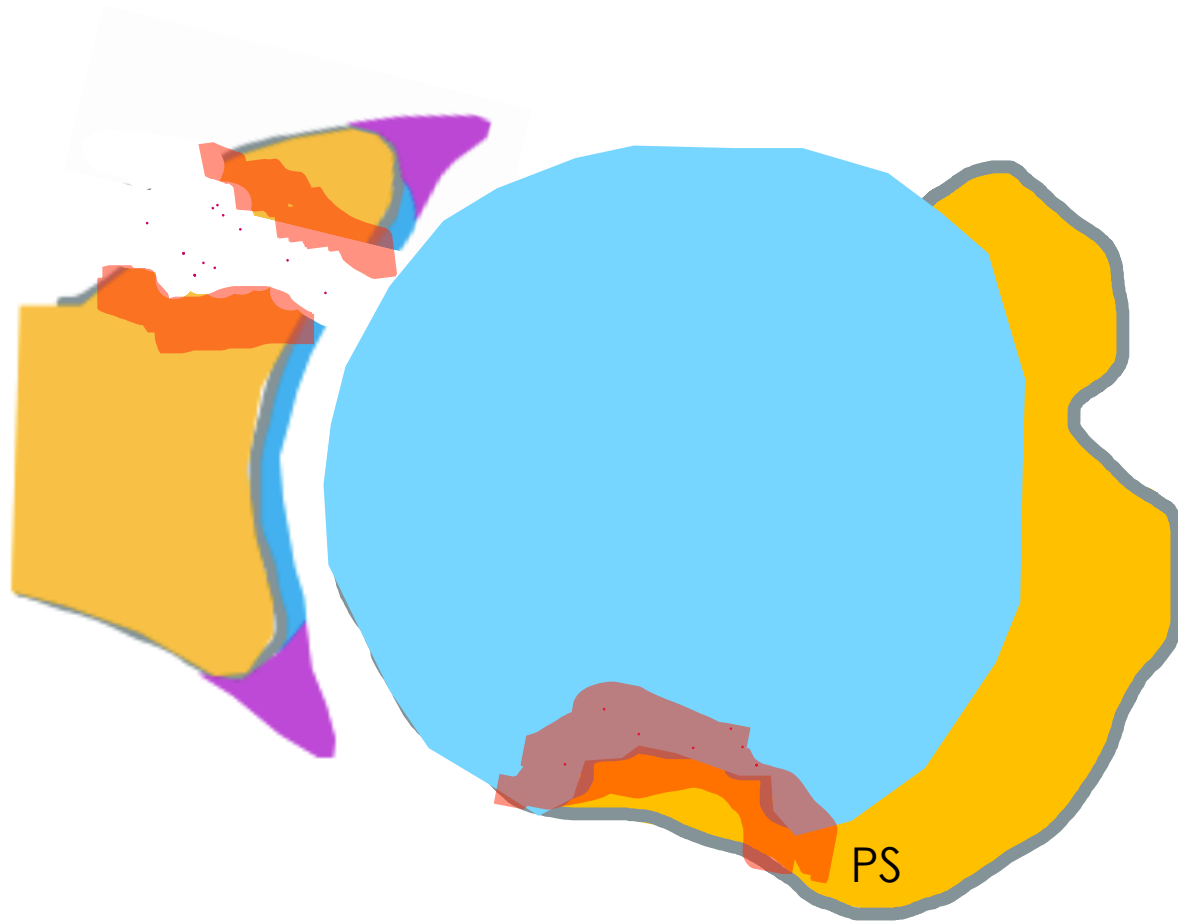
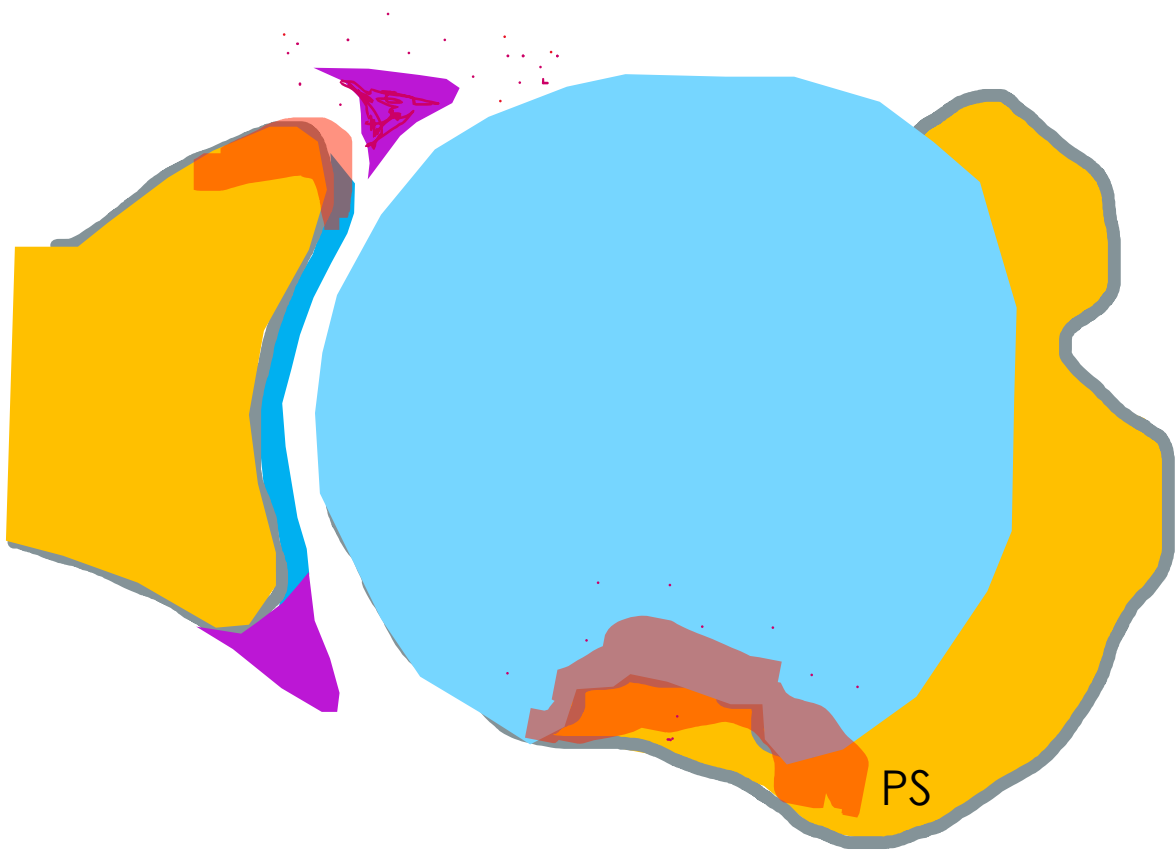
Lesion	n	%
Bankart lesion	57	100
Hill-Sachs lesion	41	71.9
SLAP lesion	22	38.6
Bone lesion of the glenoid	18	31.6
Chondral lesion	16	28
Lesion of the long head of the biceps	8	14
Rotator cuff lesion	1	1.8

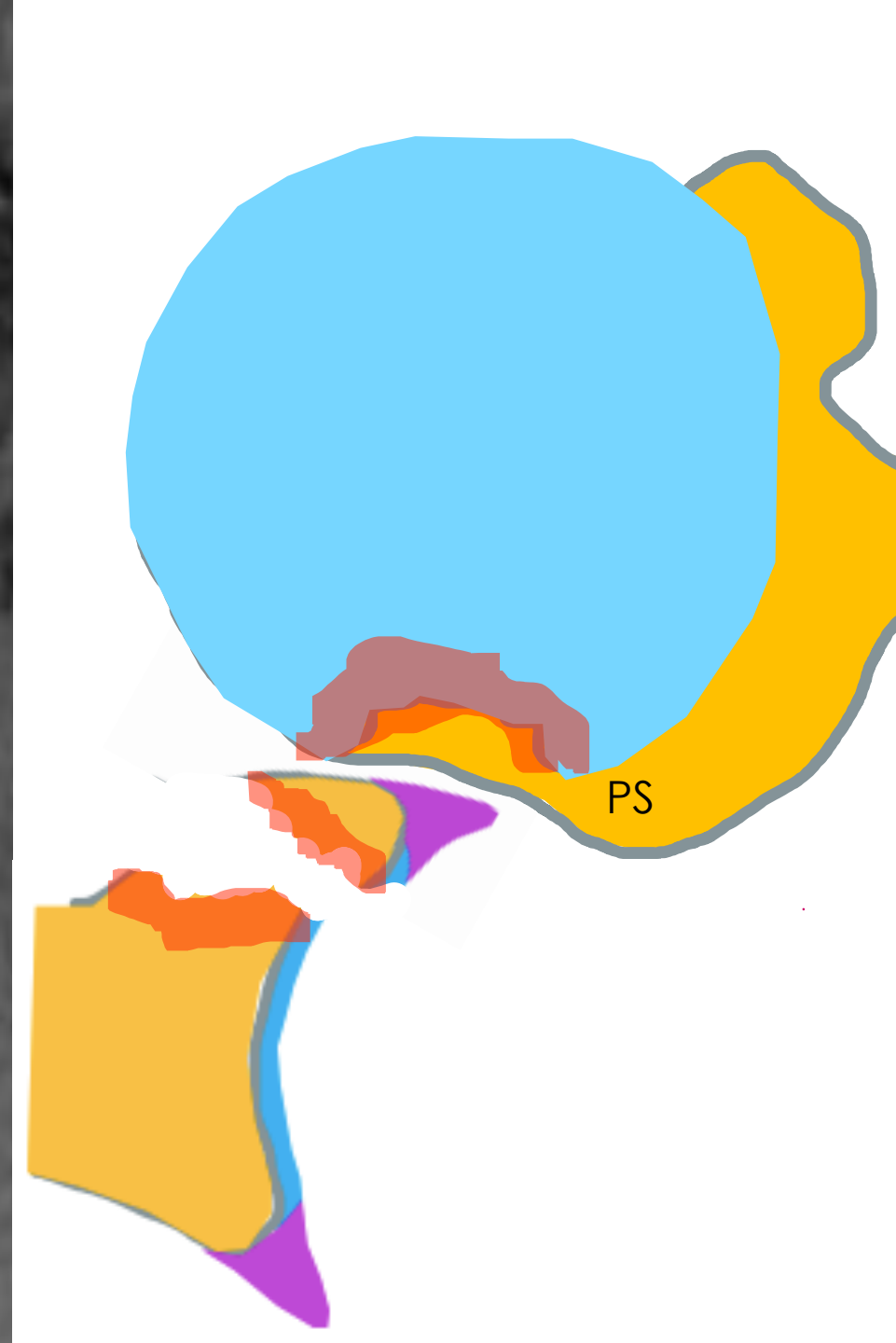
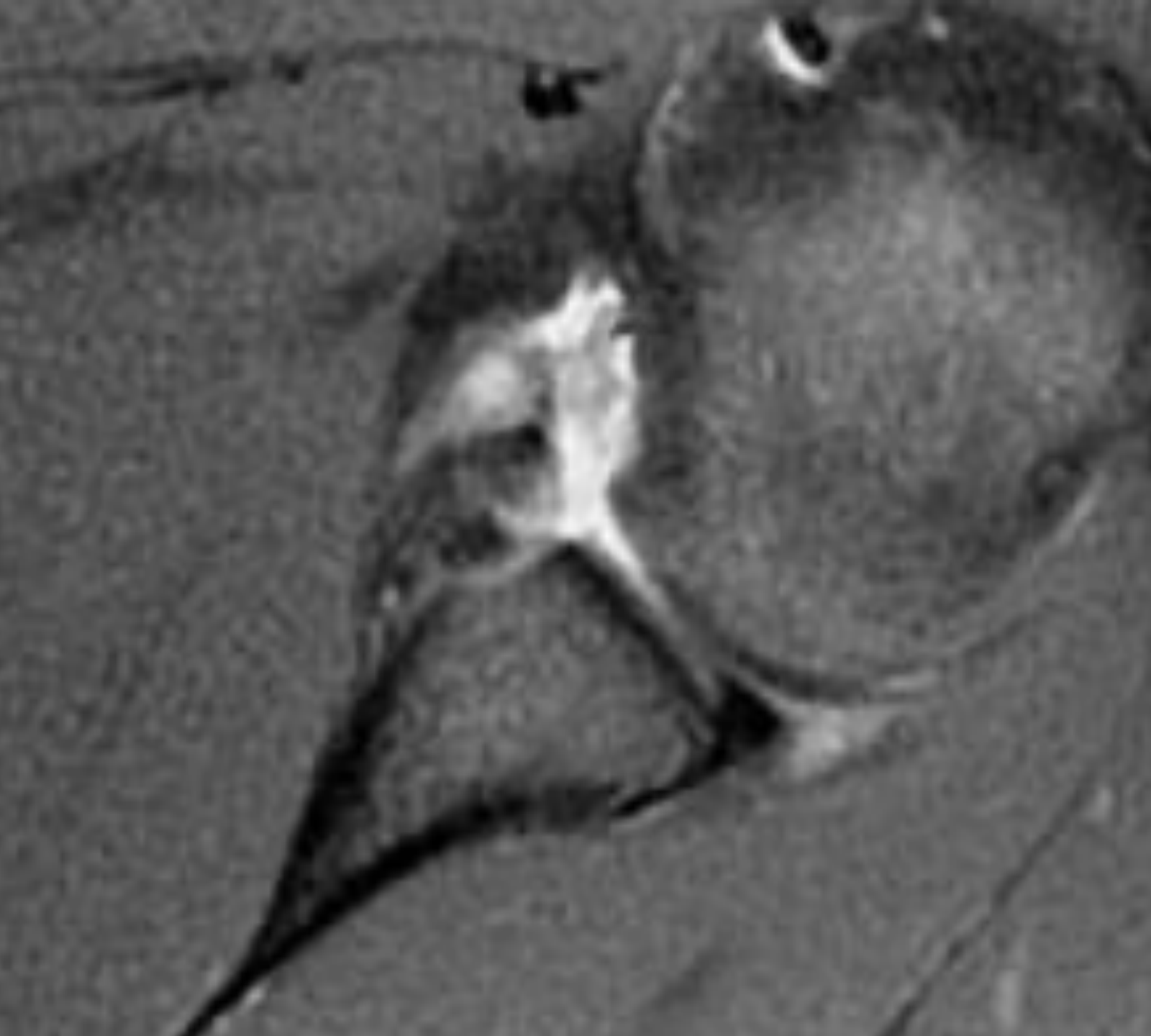
Prevalence of lesions associated with traumatic recurrent shoulder dislocation.

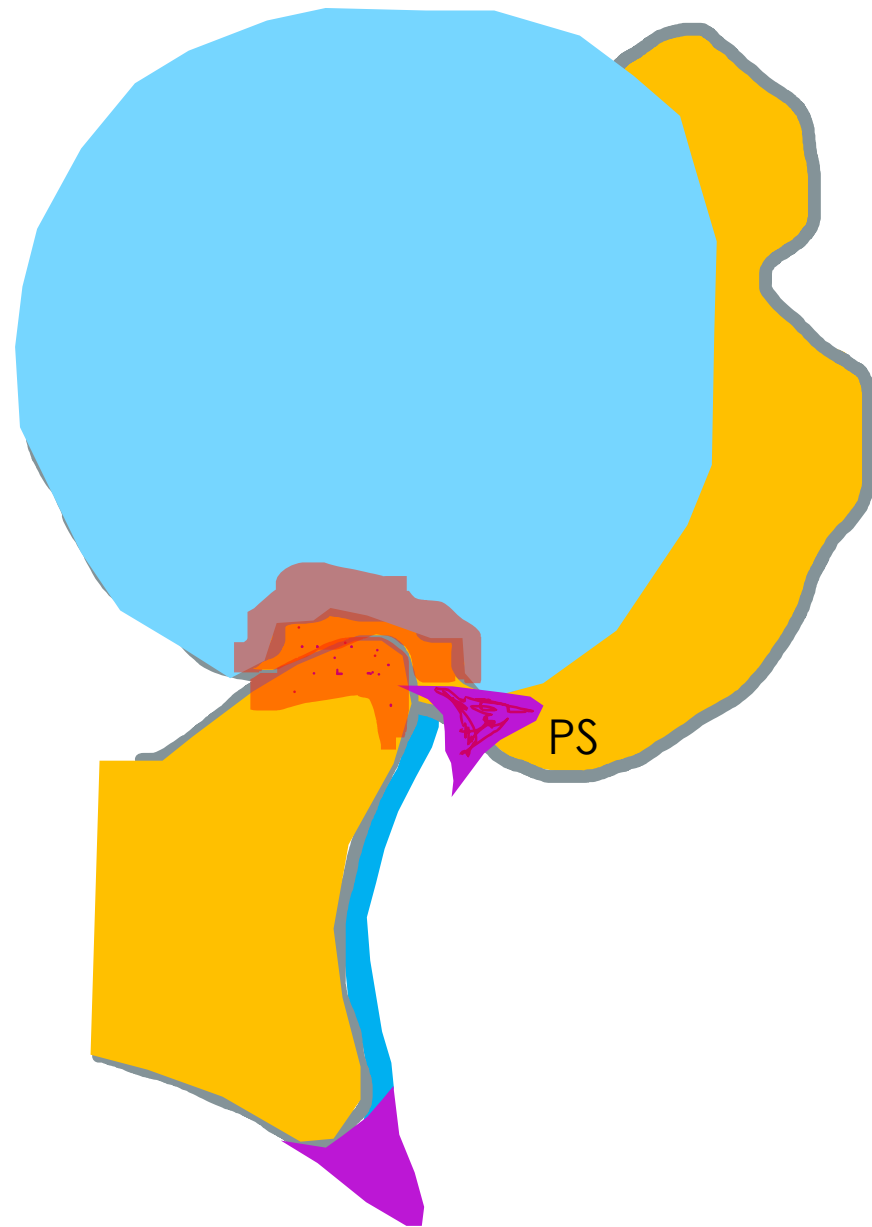
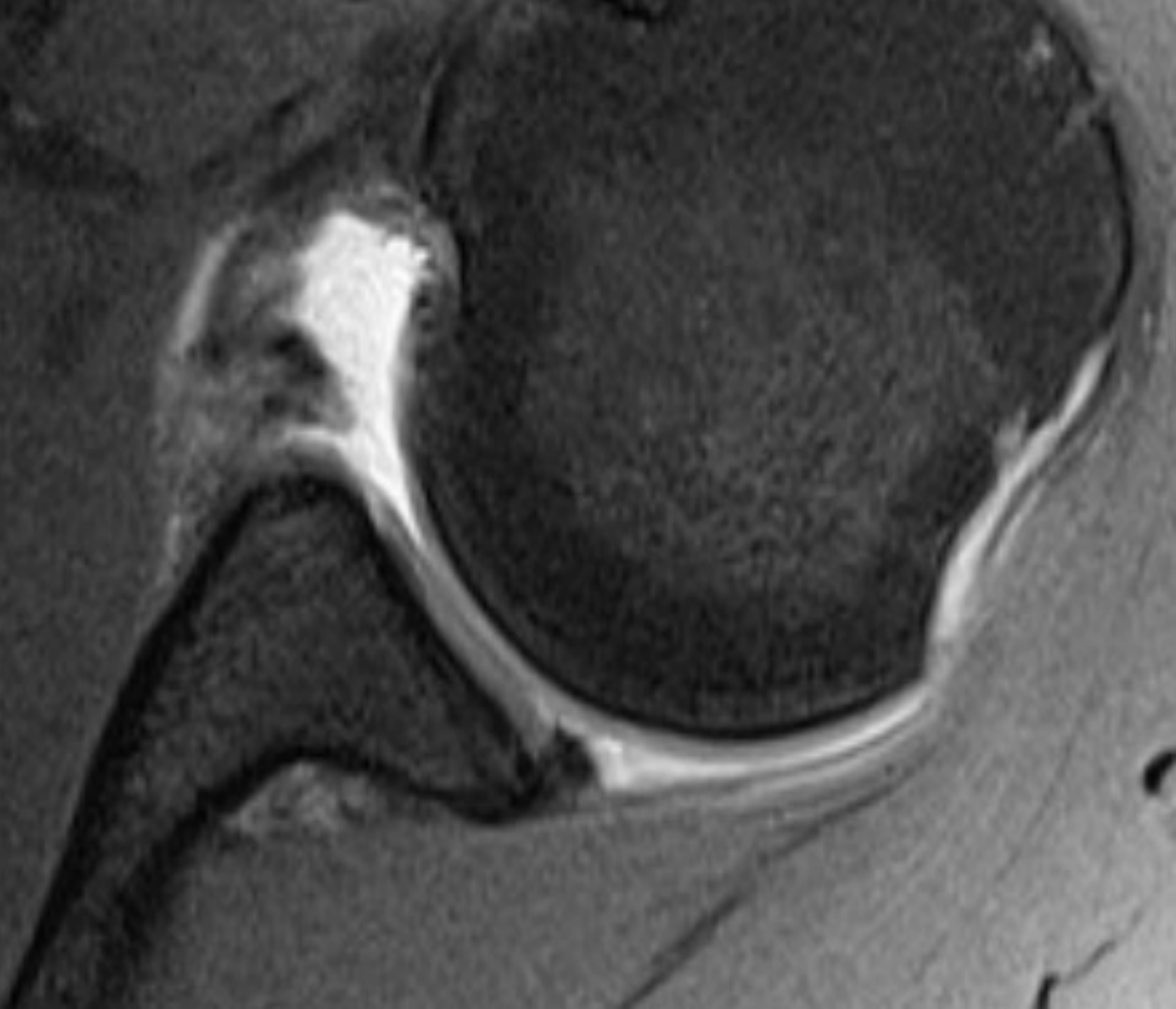
10.1016/S2255-4971(15)30196-8

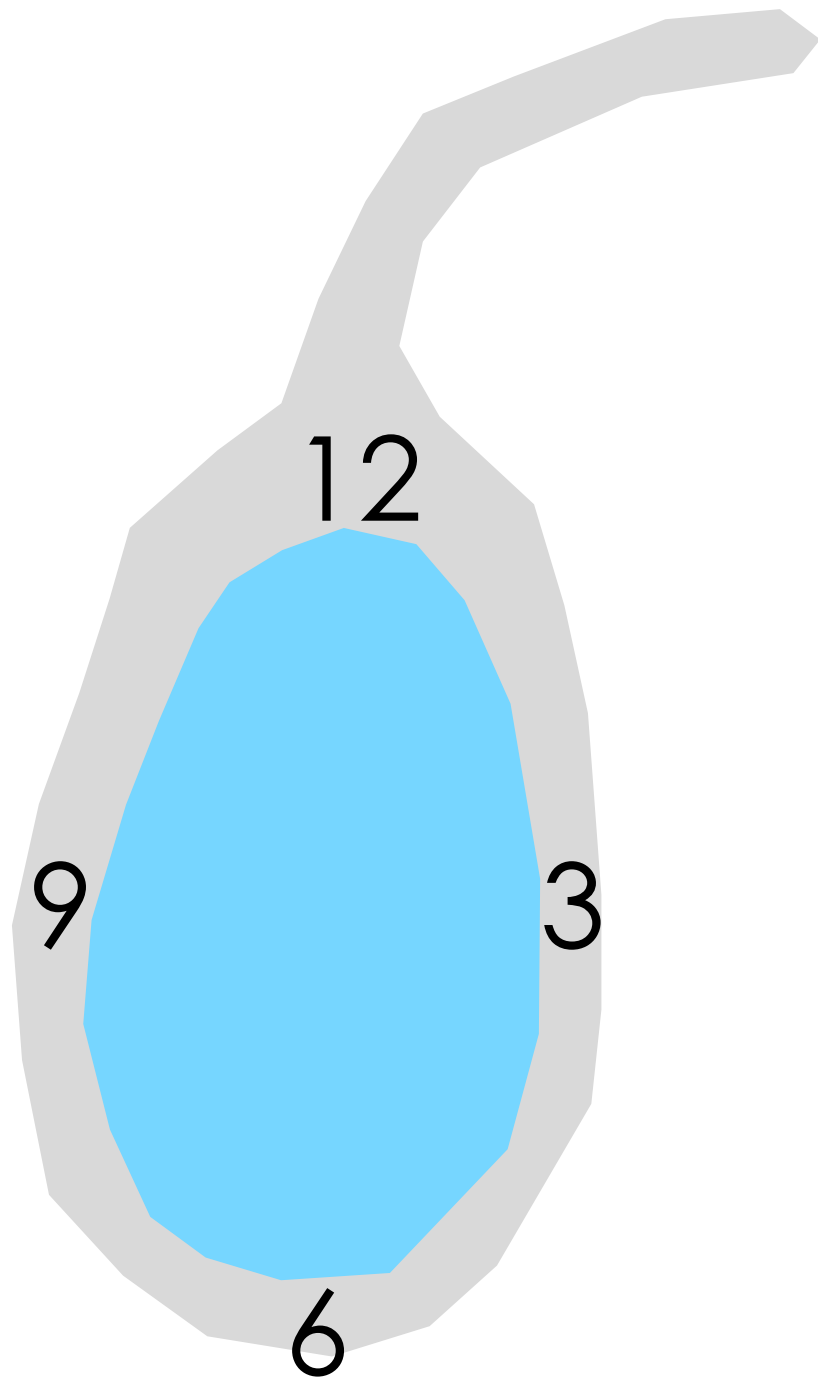




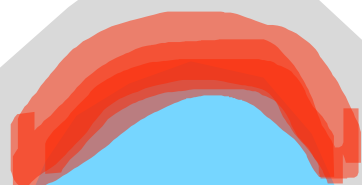








SLAP



PS

sublabral foramen/recess



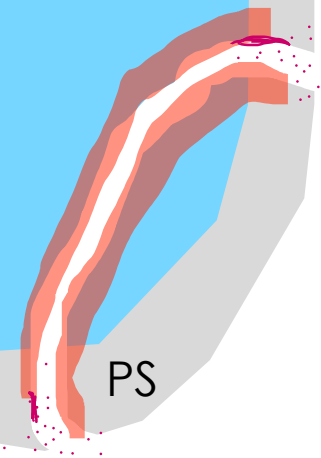
PS

Buford complex

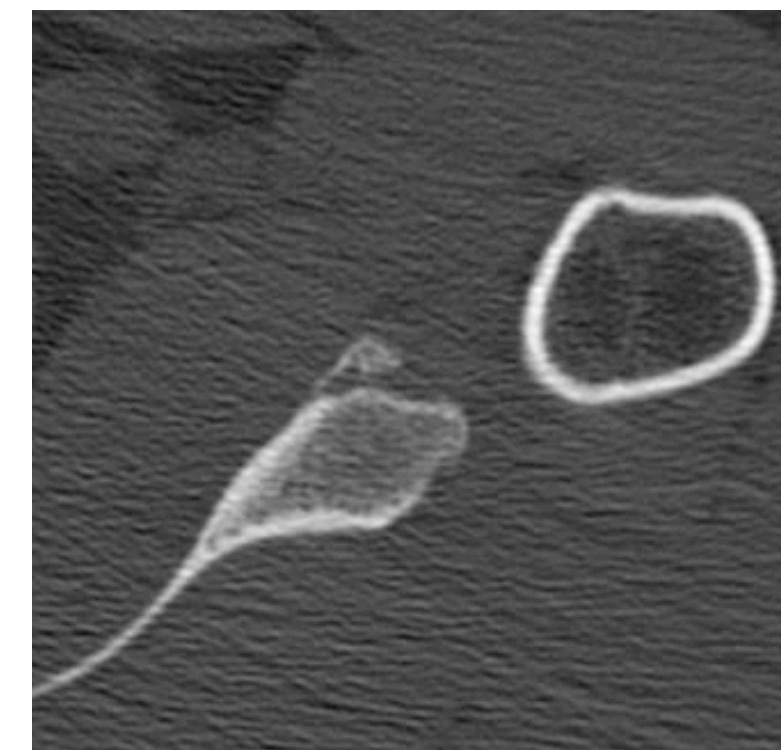
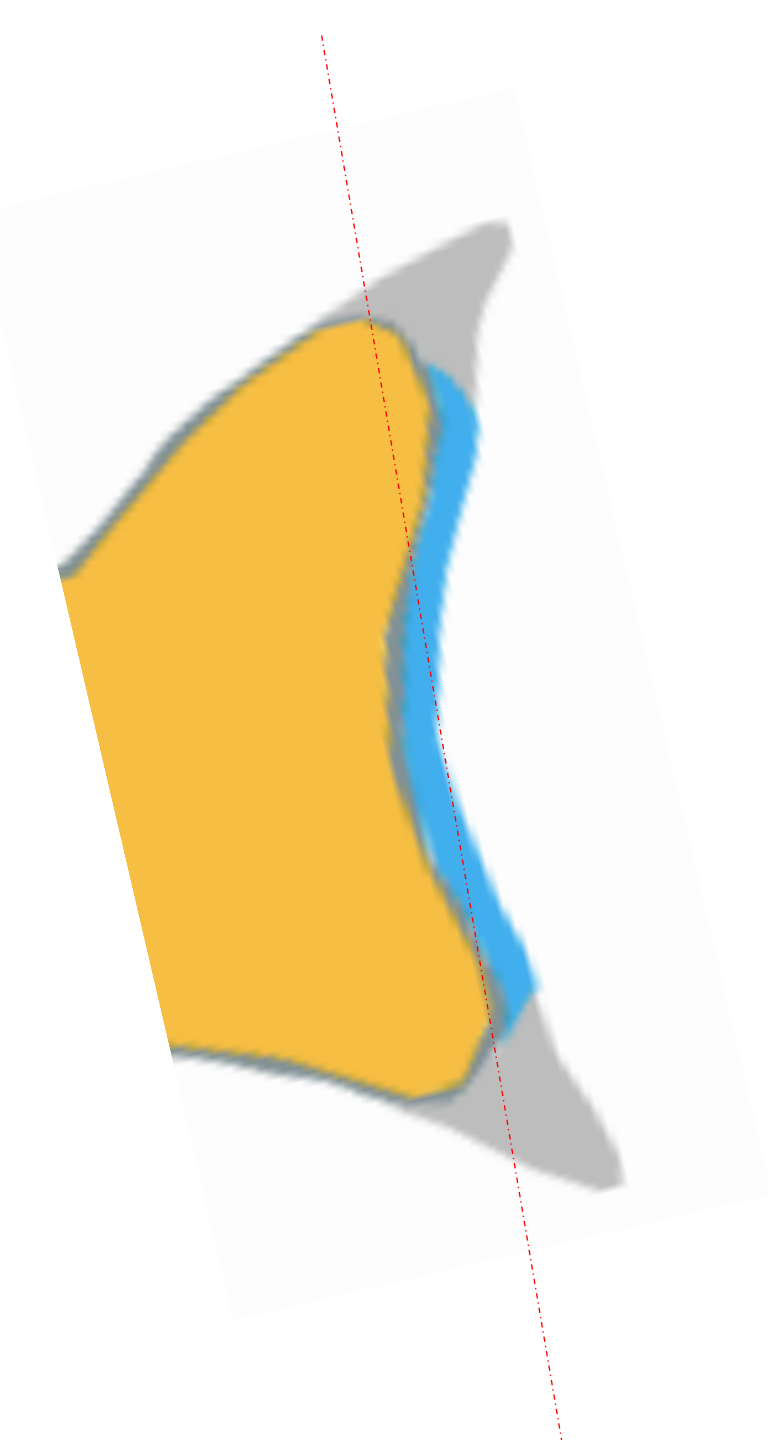


PS

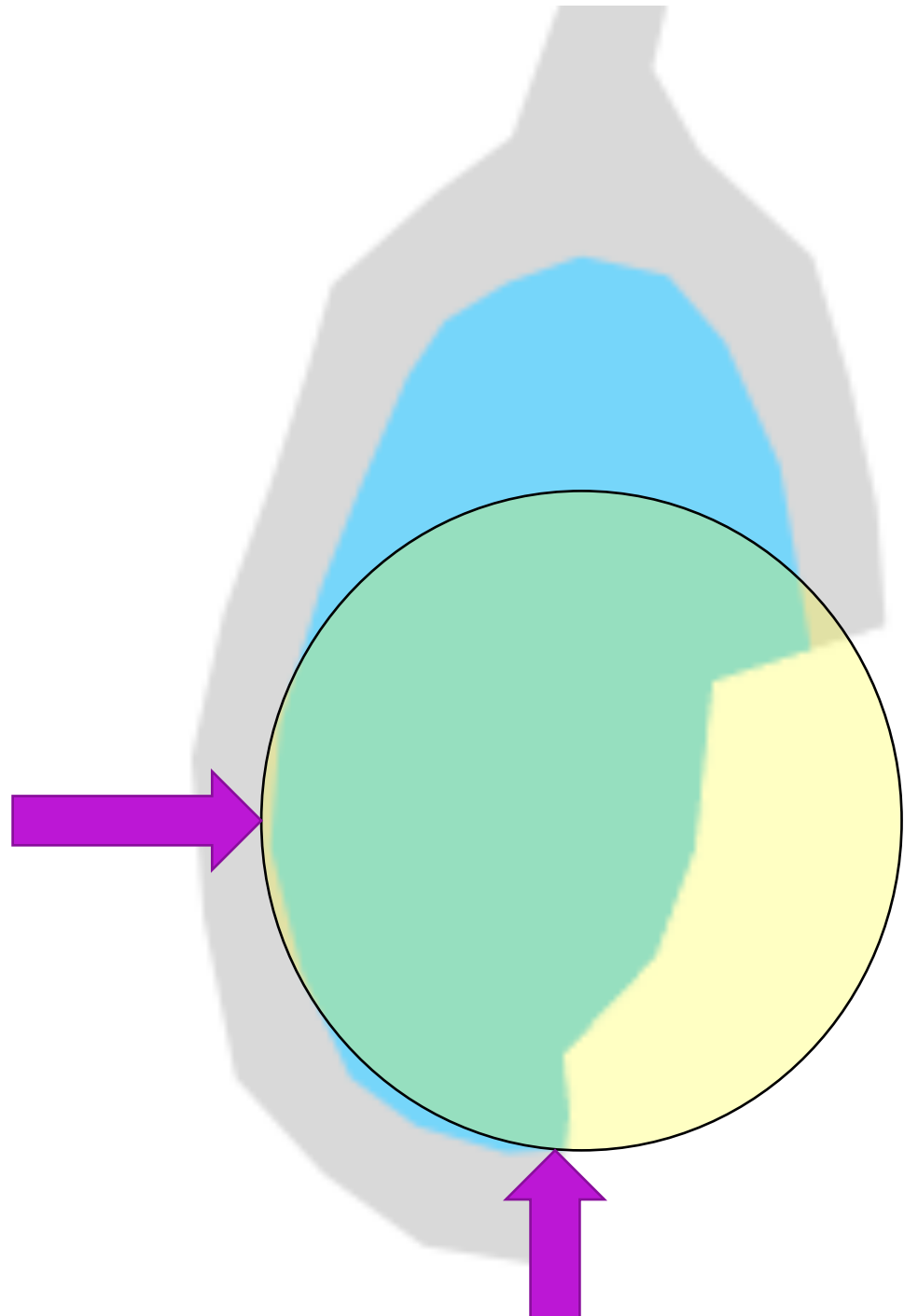
Bankart (bony)



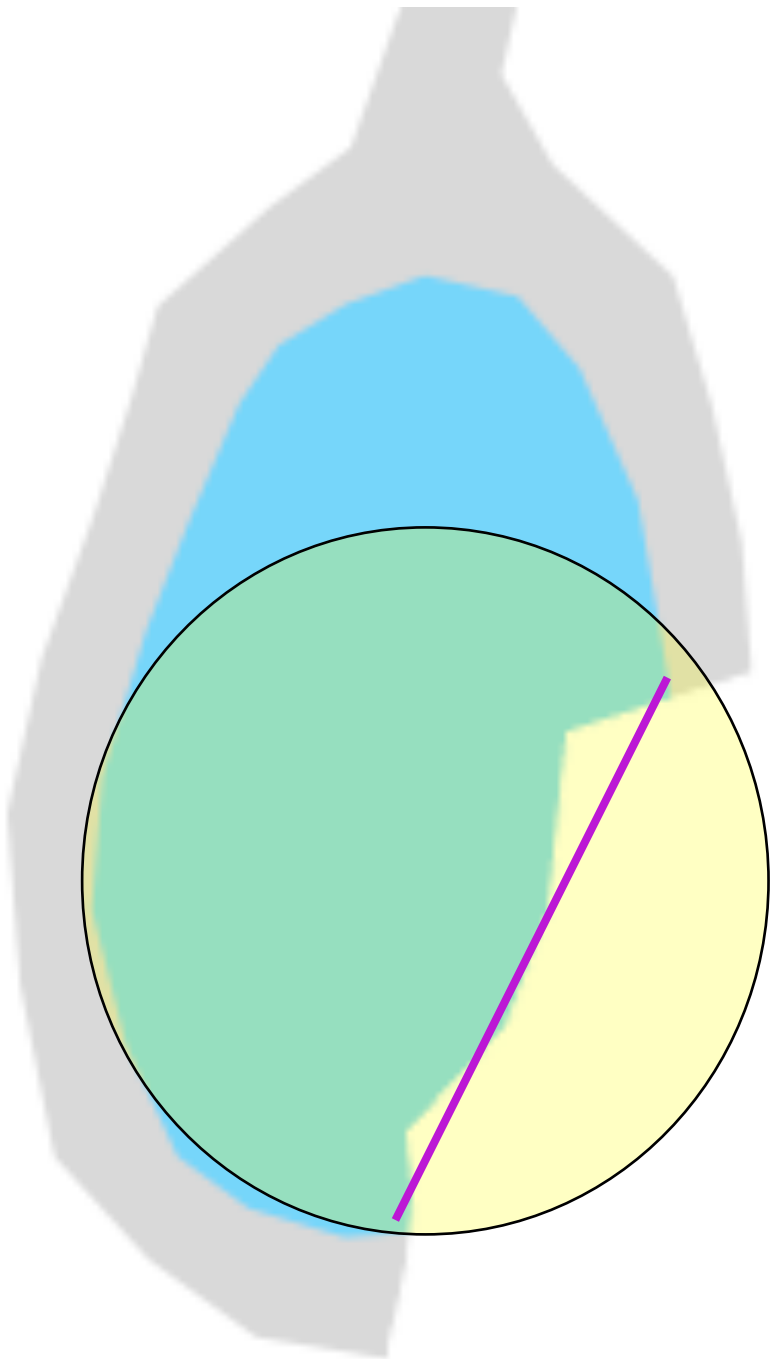
PS



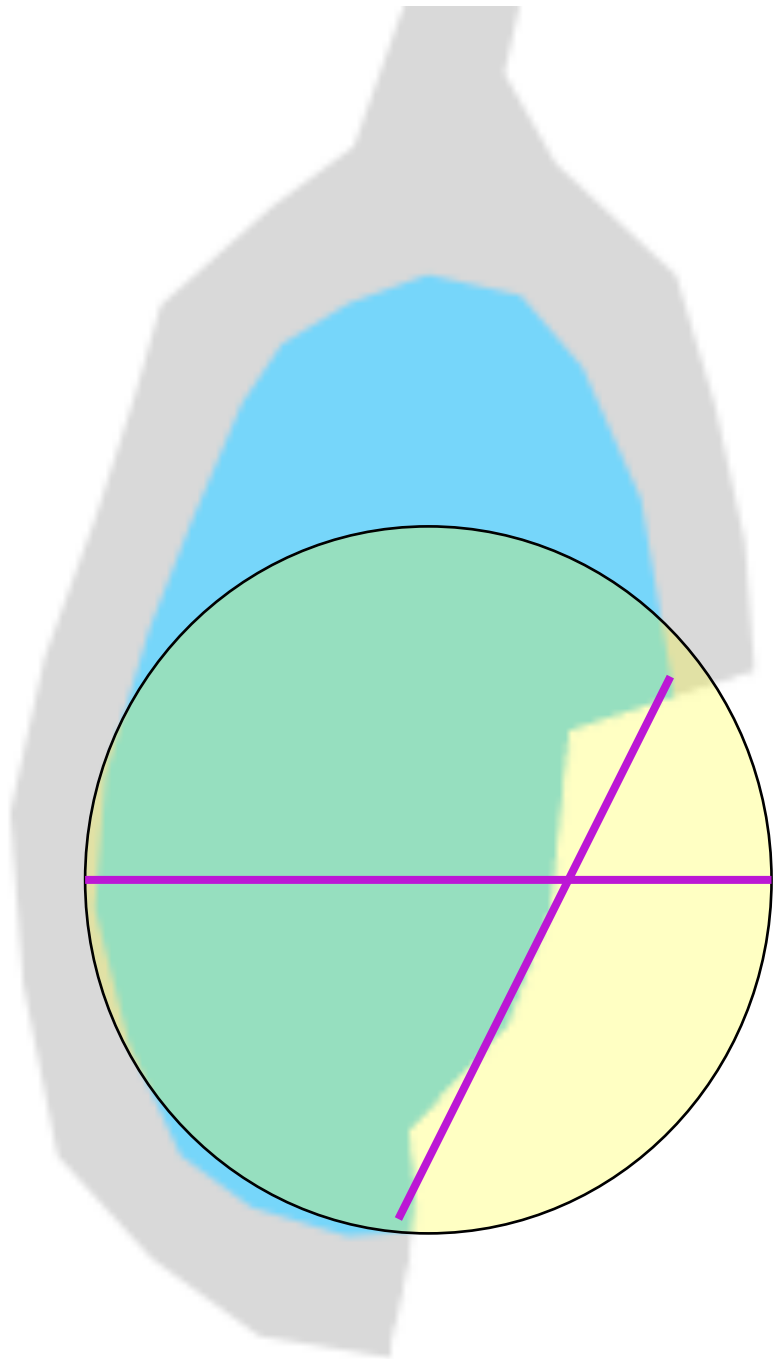
1



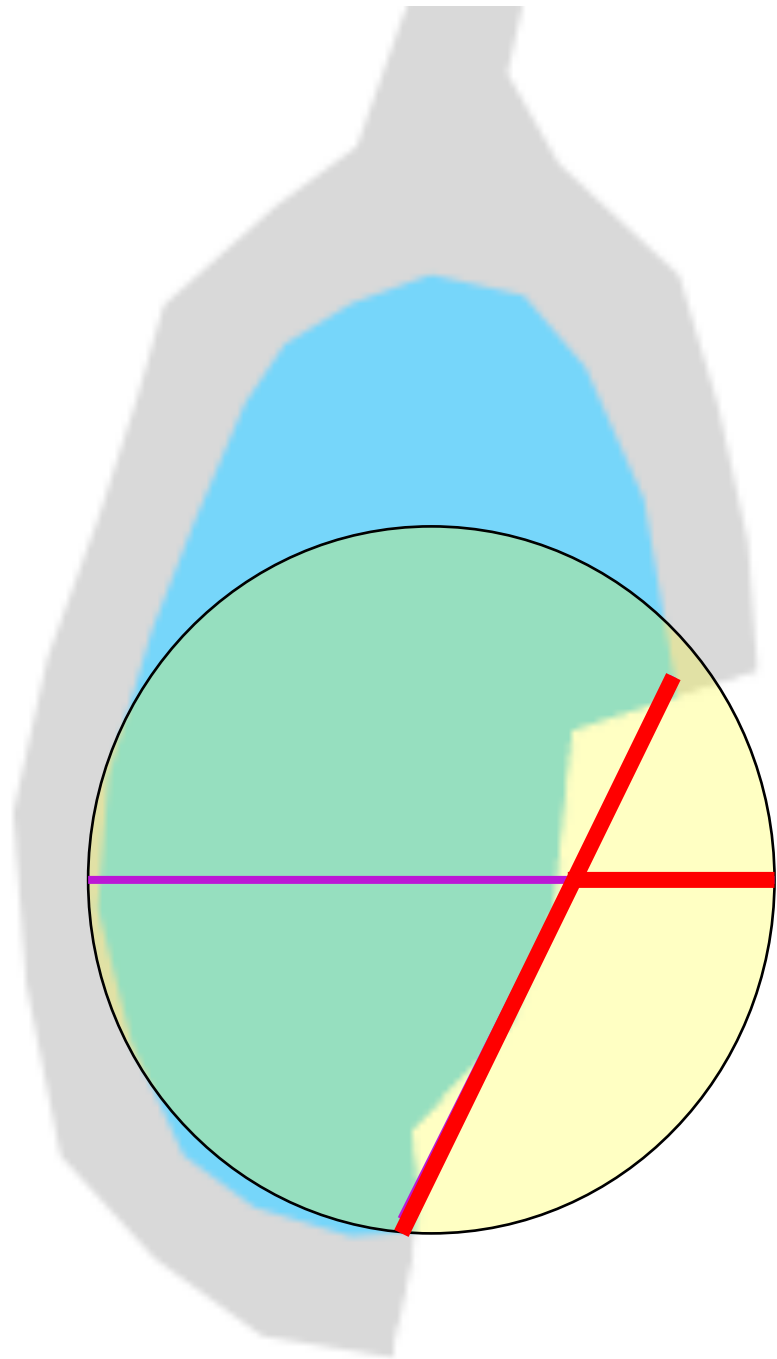
2



3



4



4