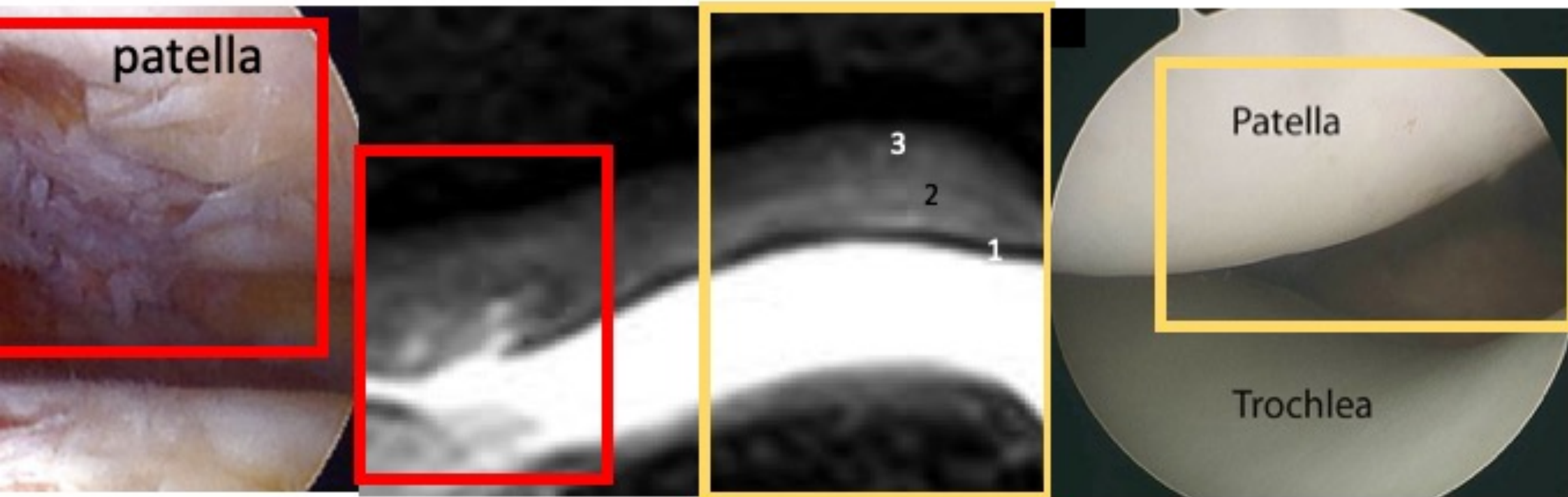


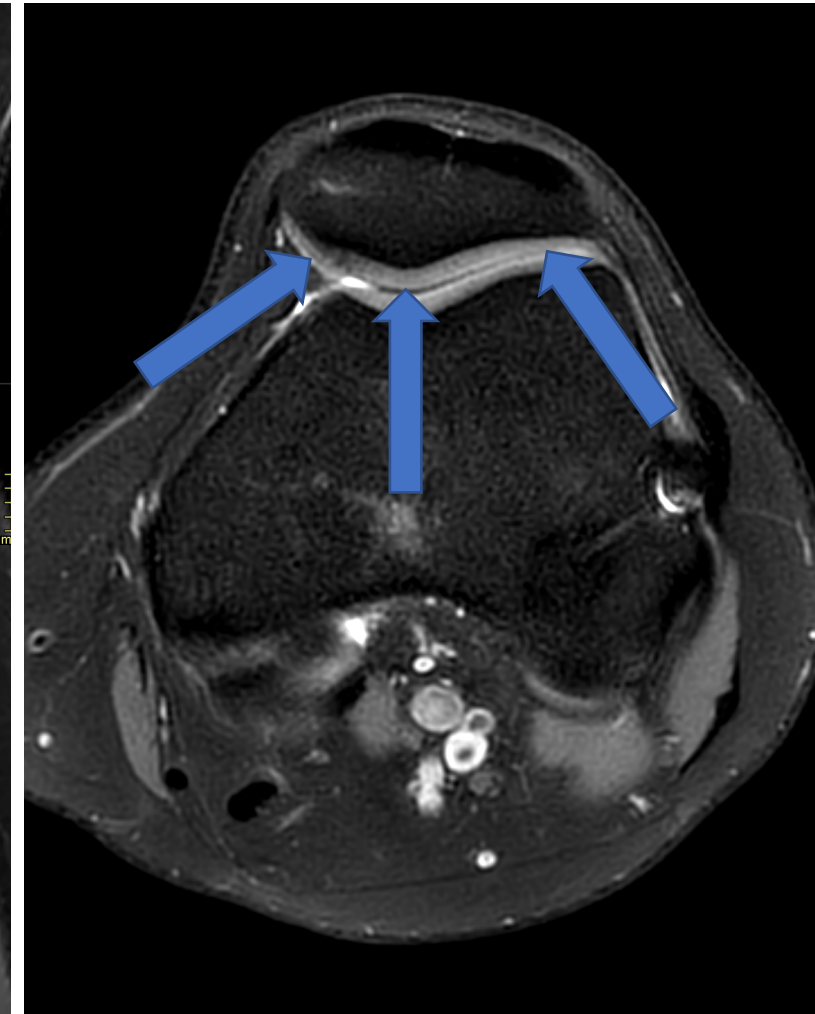
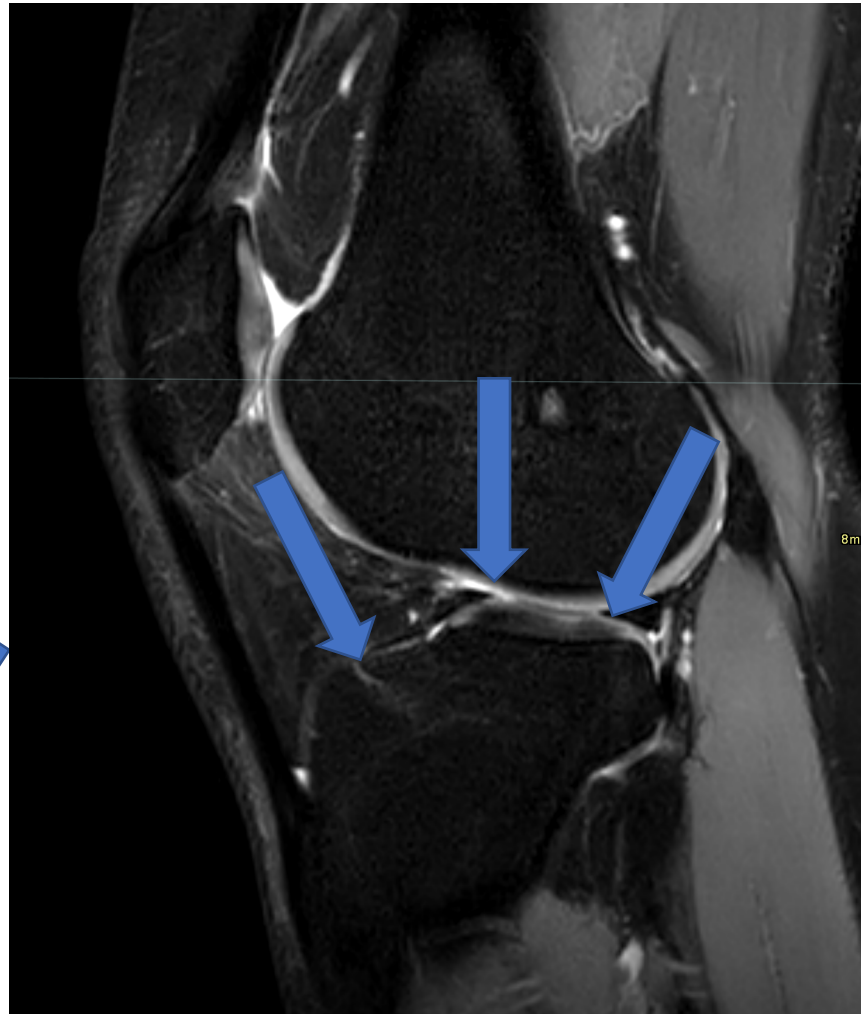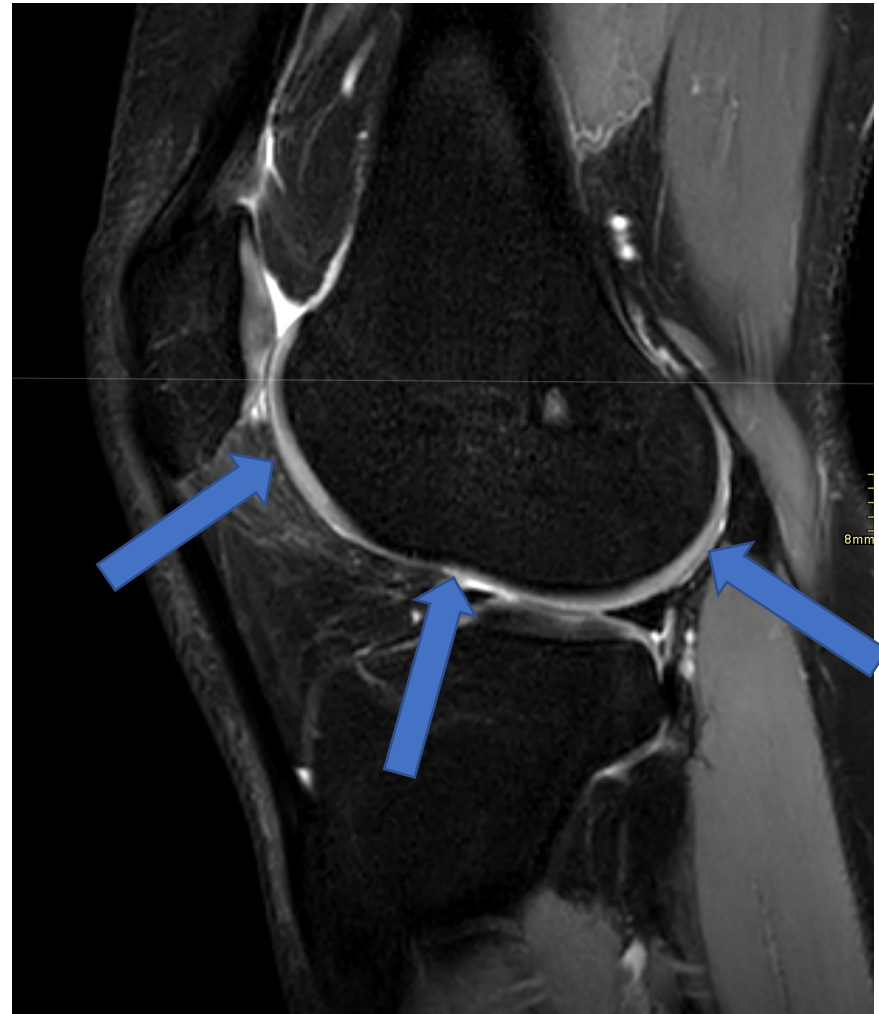


# Broskpatologi och rekonstruktion

Pawel Szaro



# Anatomi



Chrzastka

Osteoarthritis

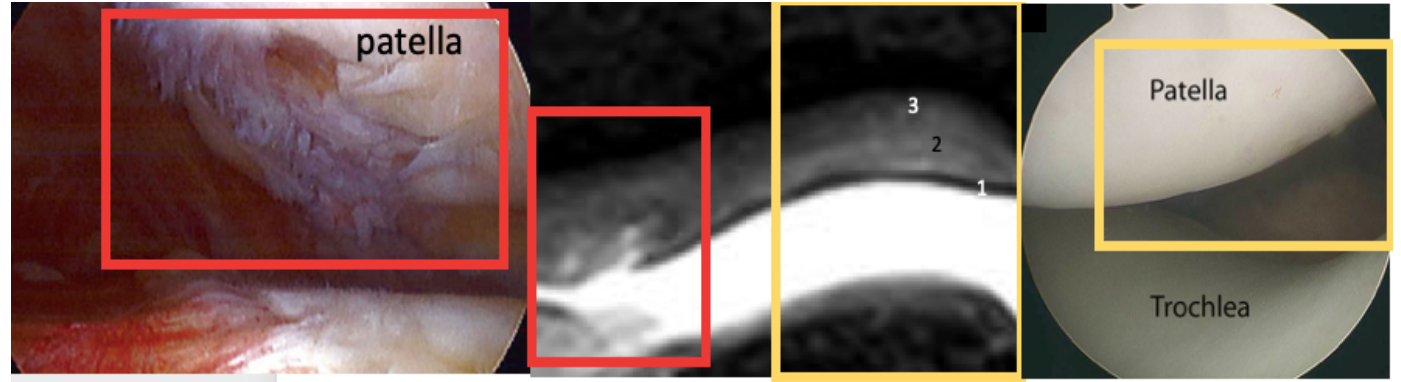
Focal chondral defect

Delamination, flap formation

Chondromalacia

Chondral fracture / injury/  
contusion

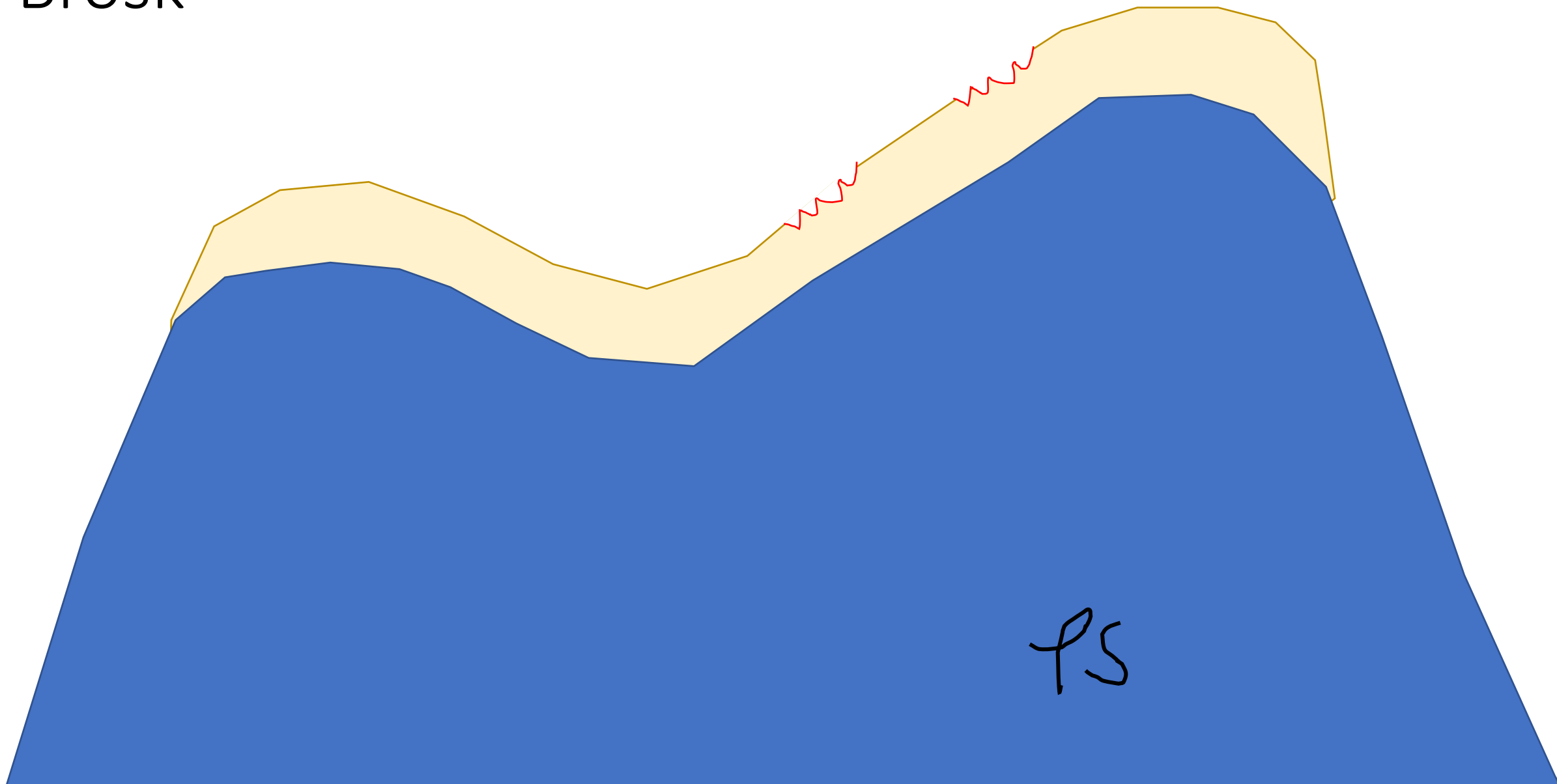
Osteochondral separation




# Nomenklatur - Broskskada

Pawel Szaro

Brosk




Brosk



PS

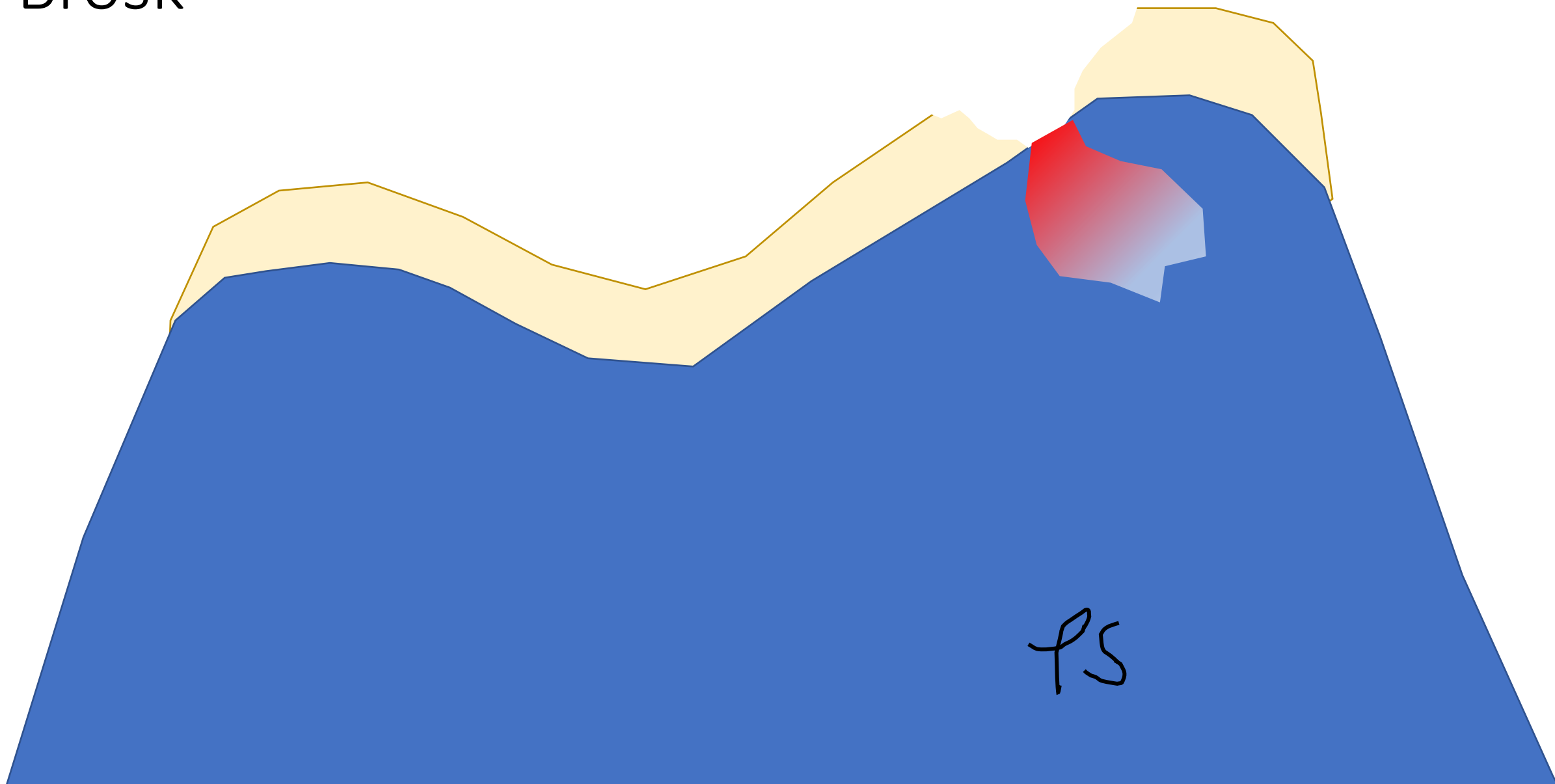
Brosk



PS

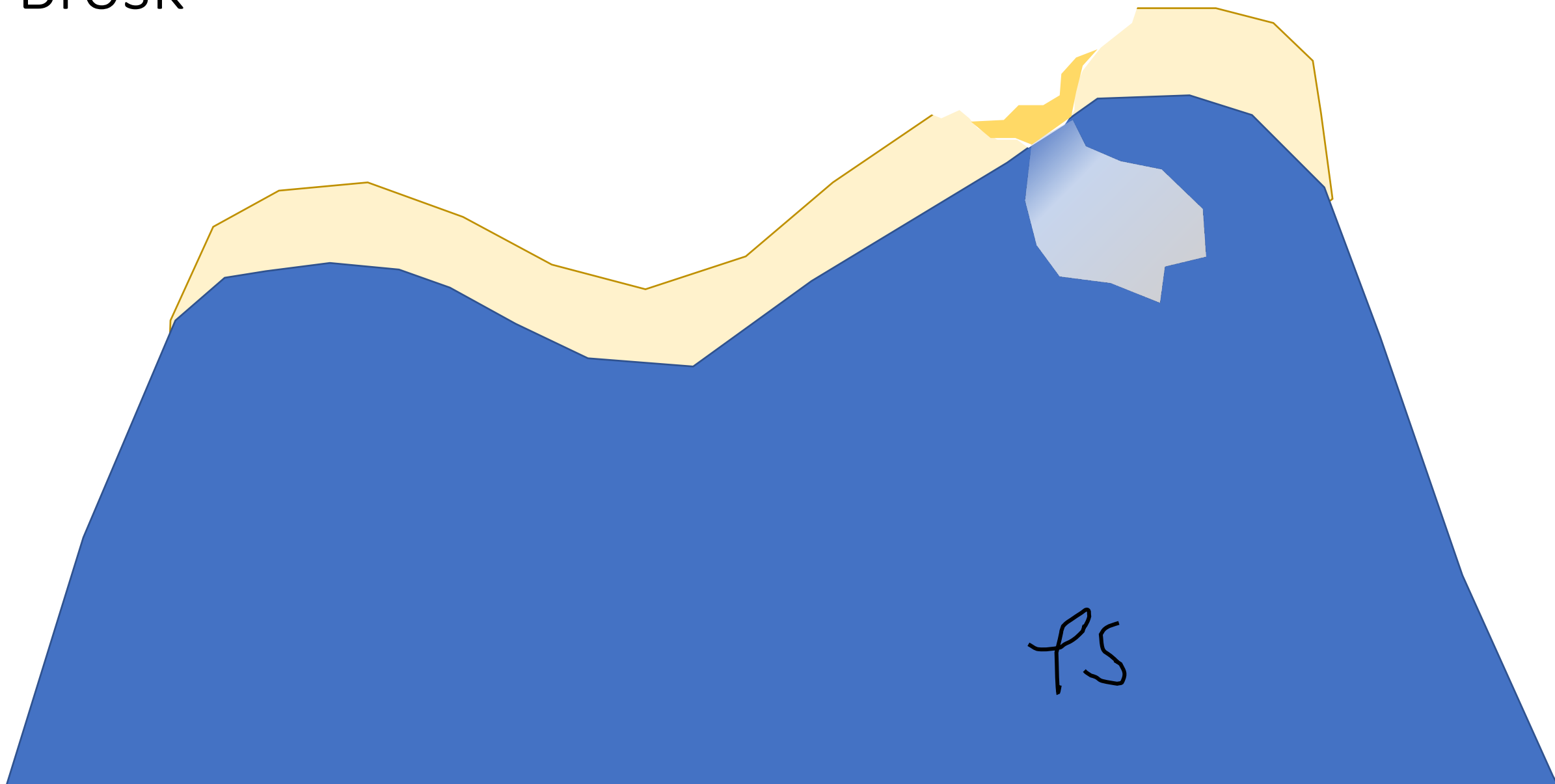


Brosk



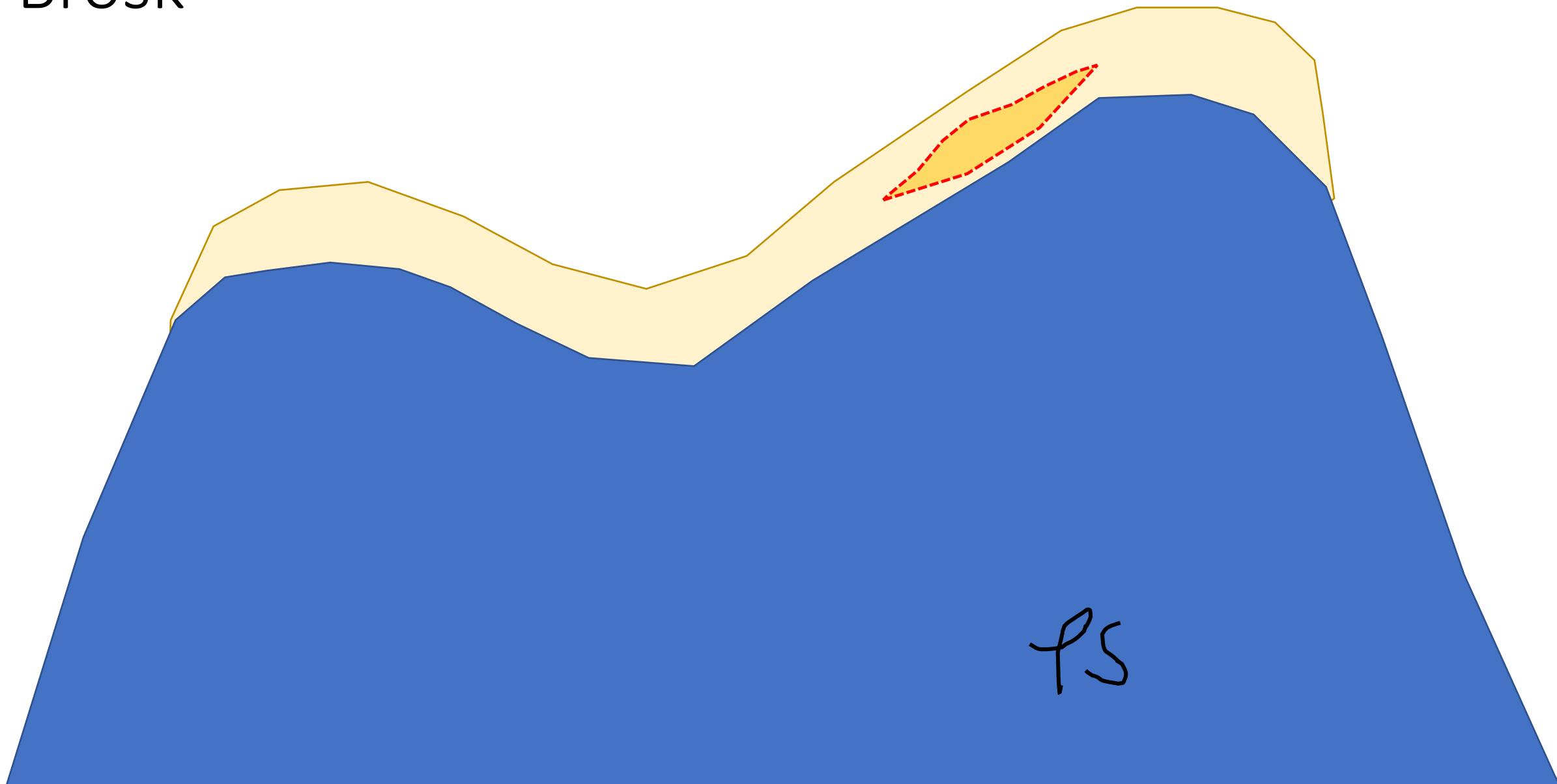
PS

Brosk



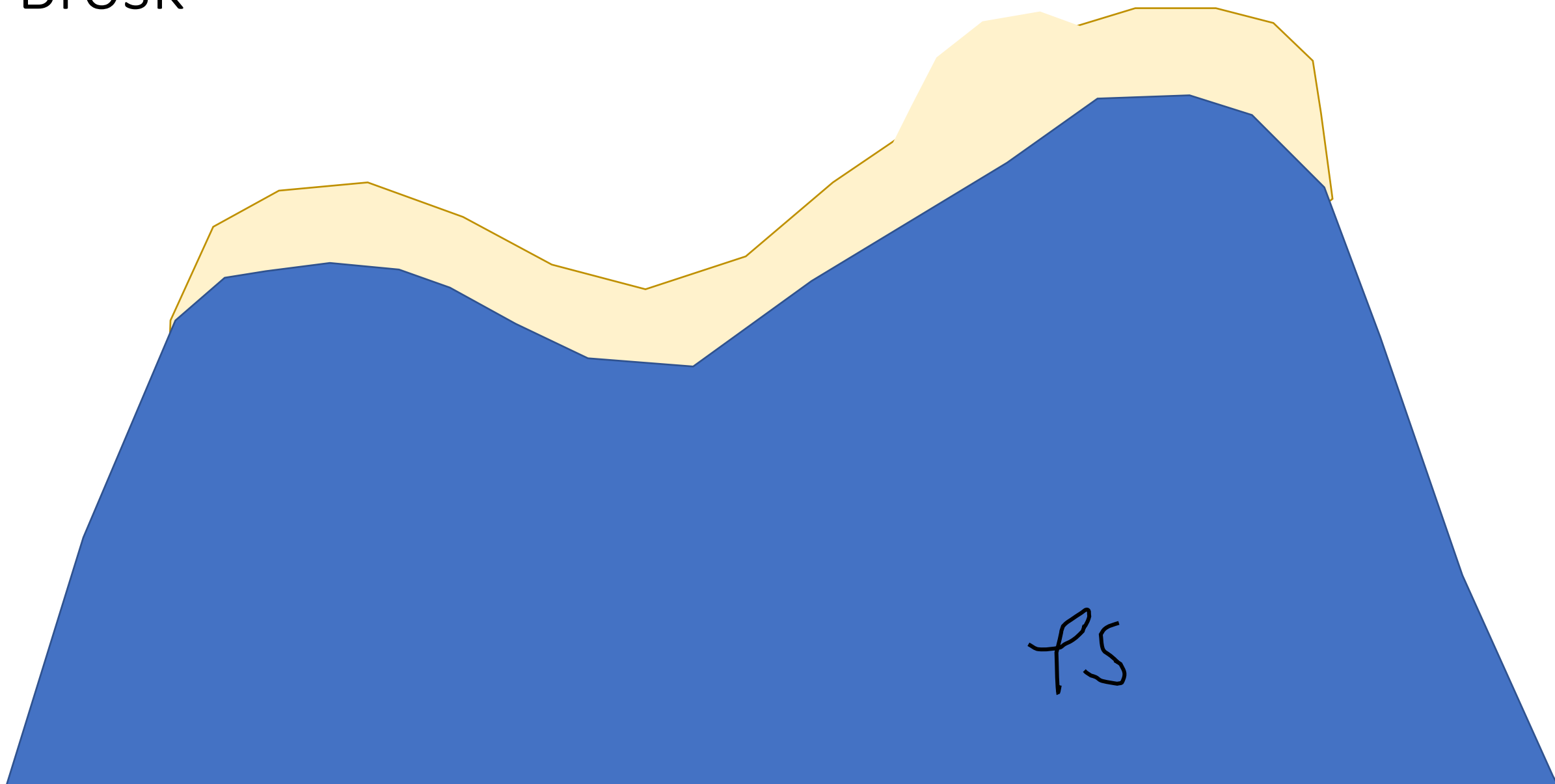
PS

Brosk



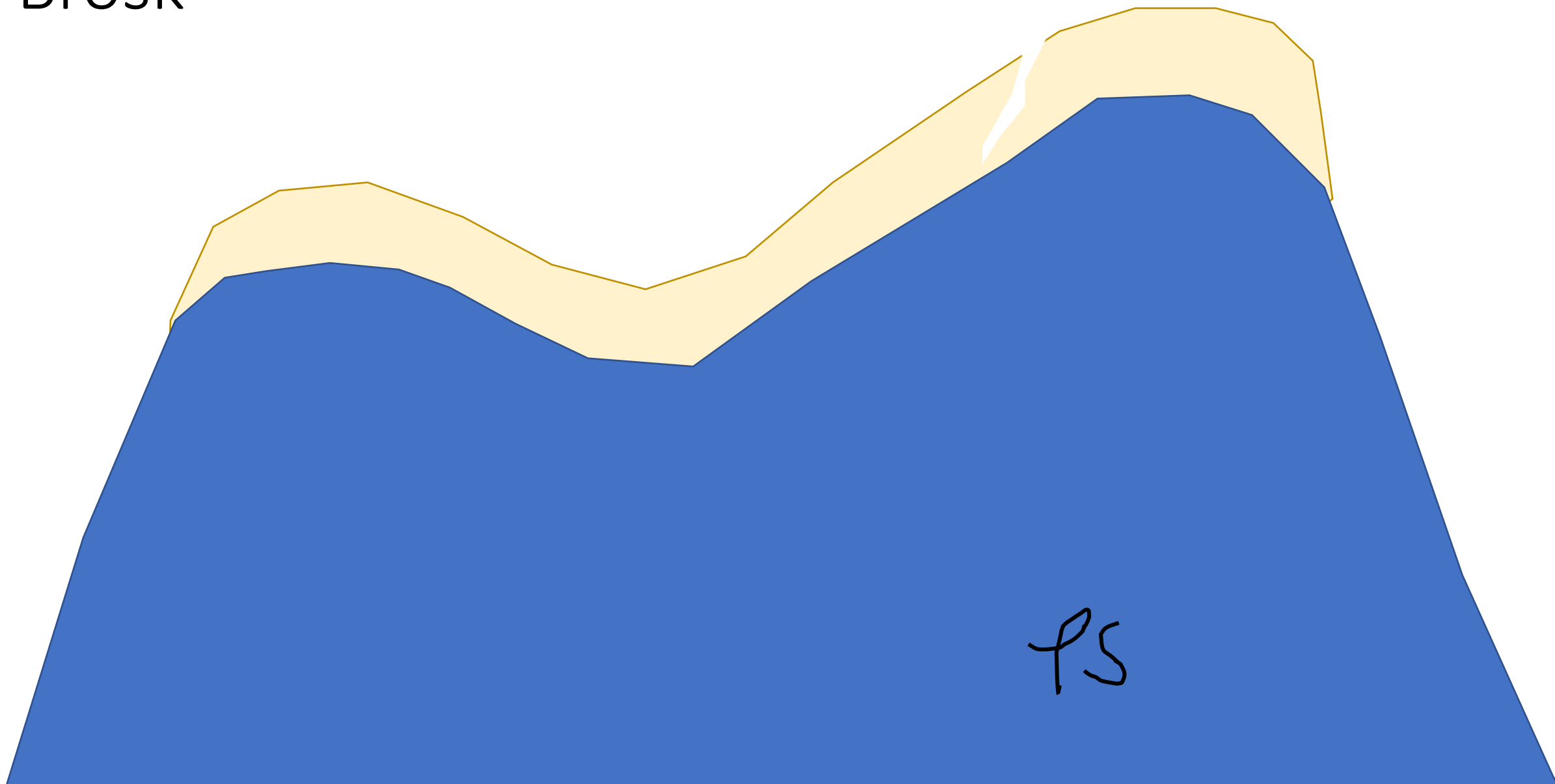
PS

Brosk



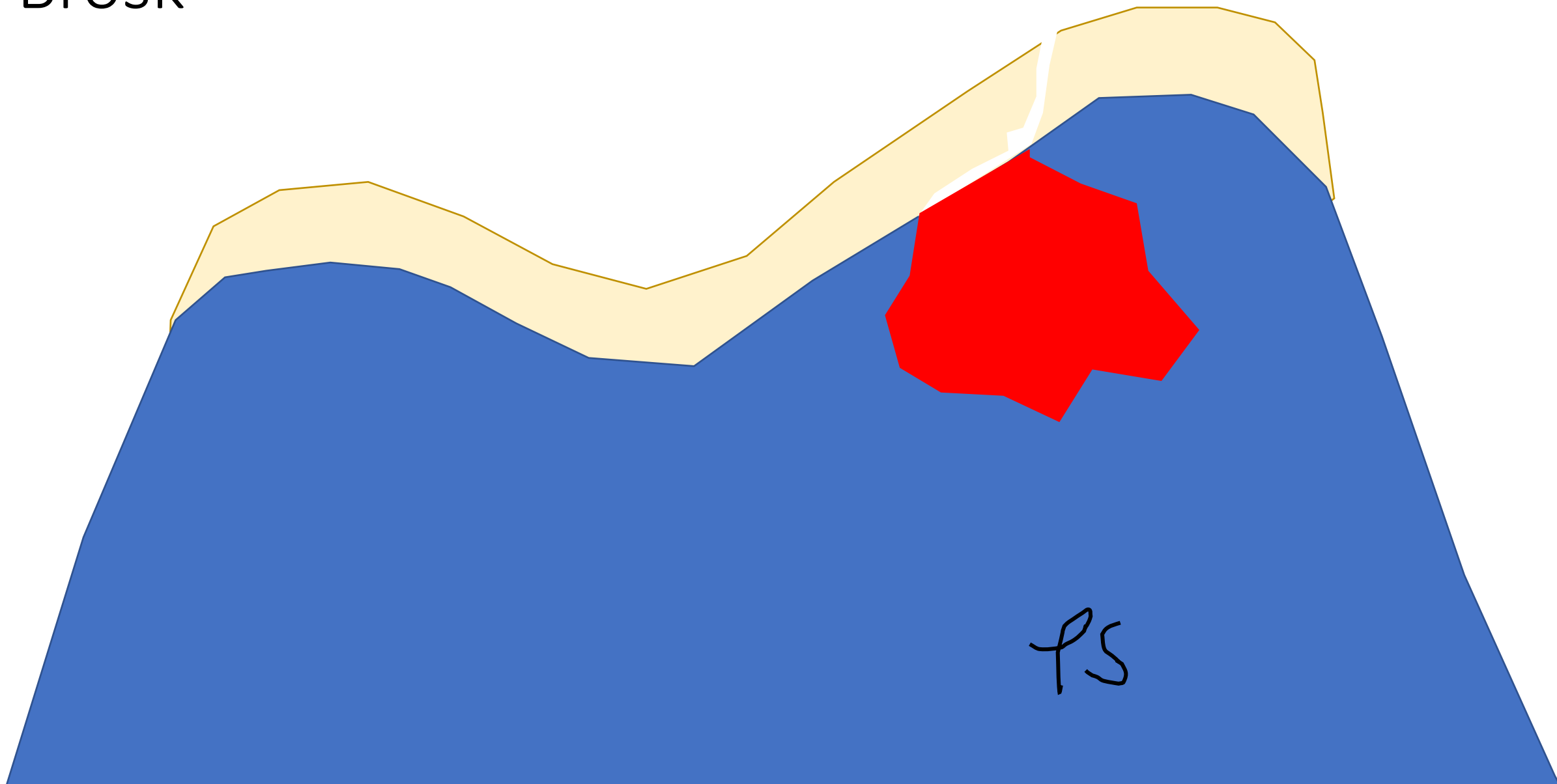
PS

Brosk




PS

Brosk



PS

Brosk



PS

Rekonstruktion



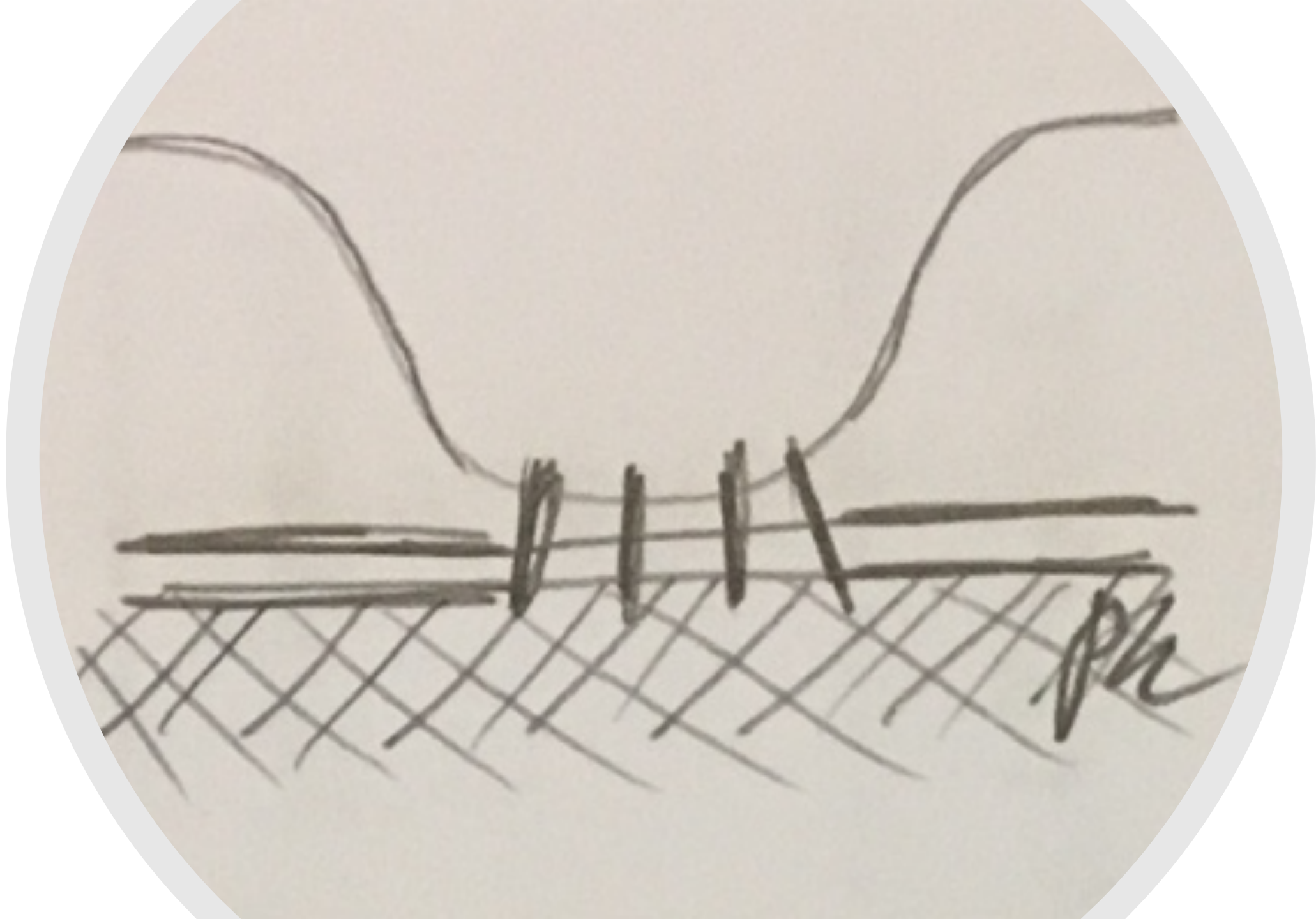
Handwritten horizontal line

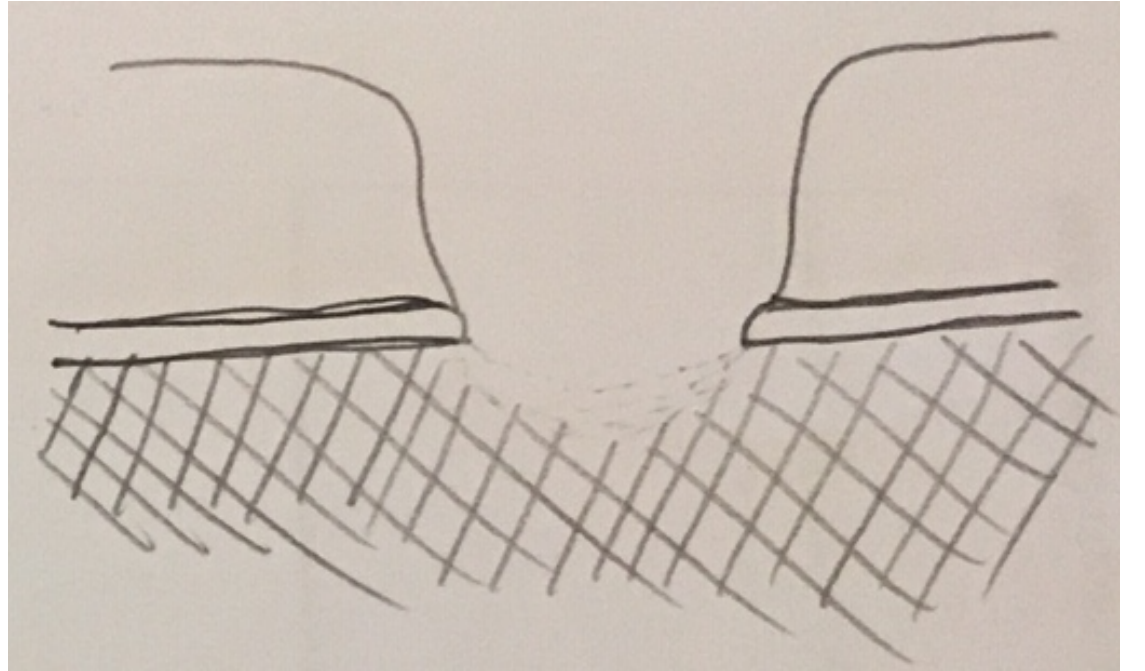
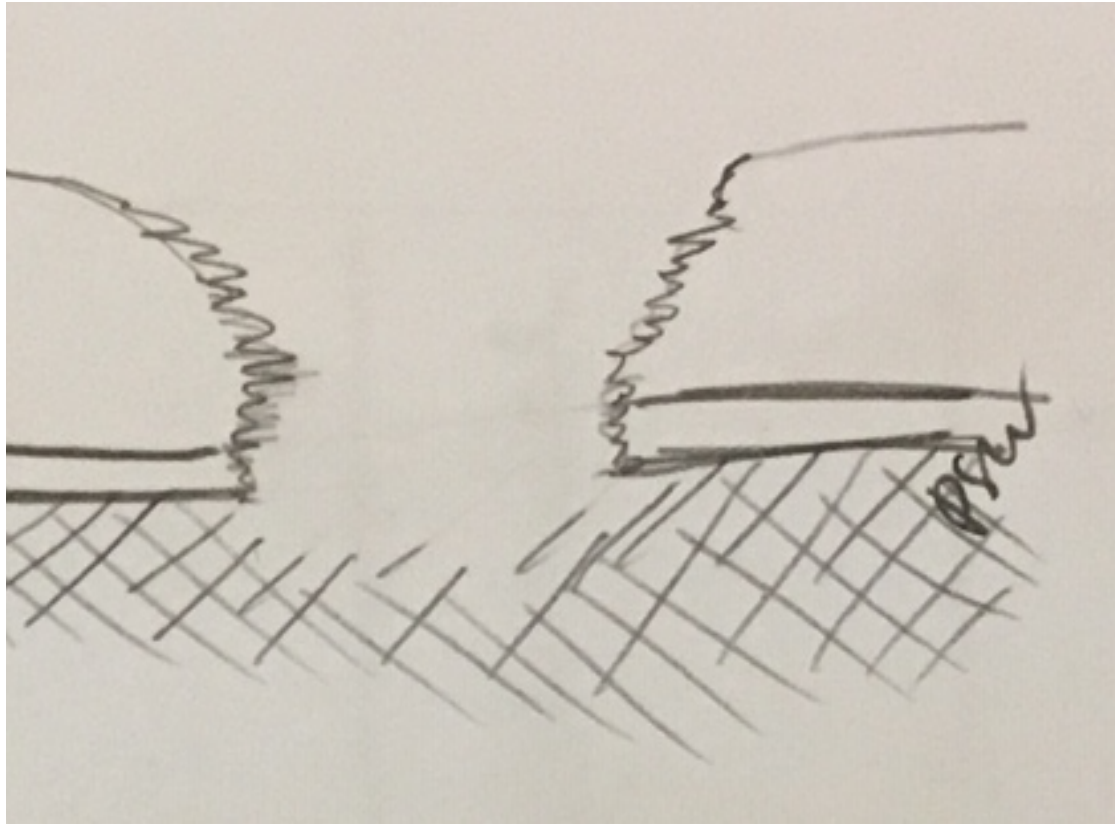
Handwritten horizontal line

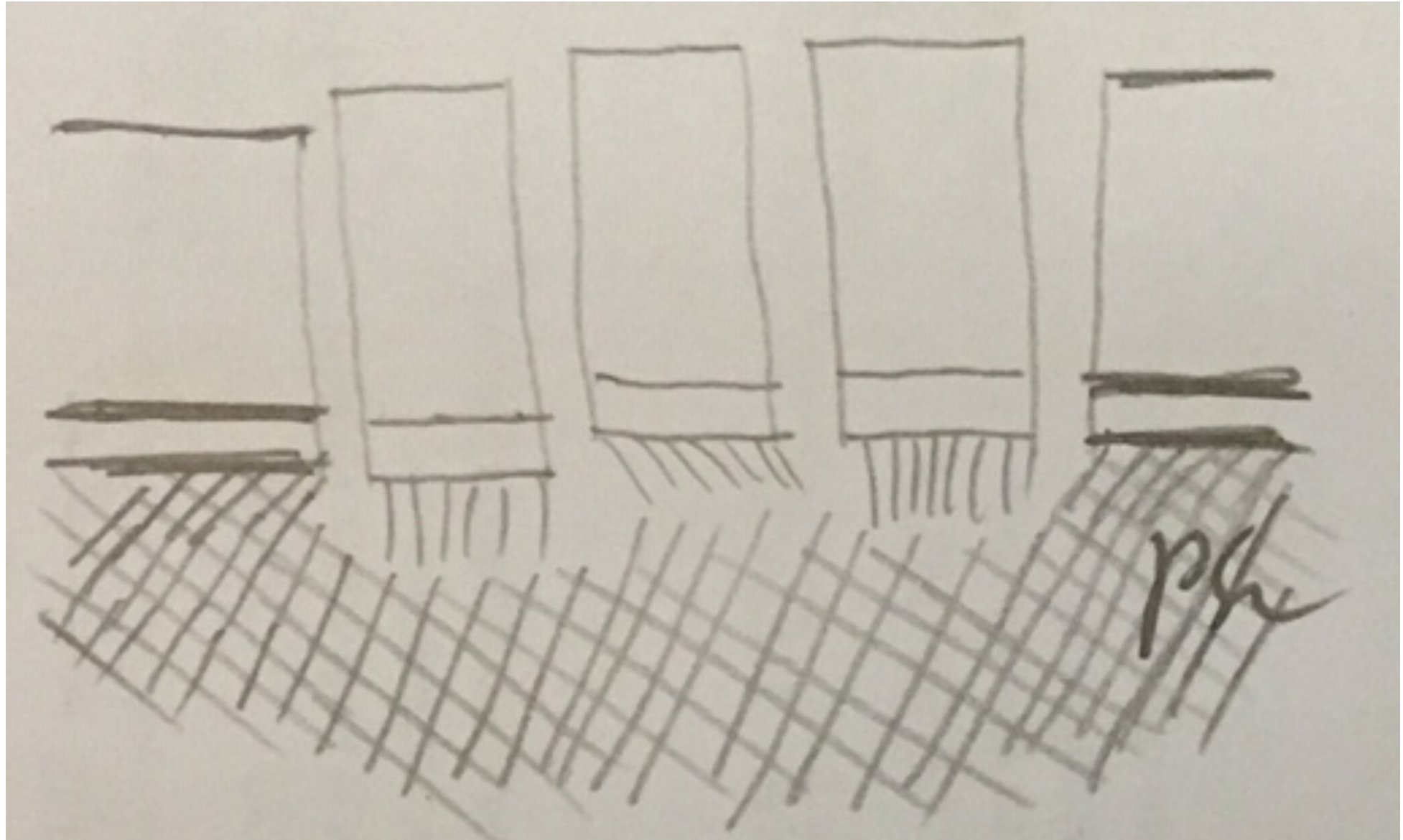
Handwritten horizontal line

Handwritten cross-hatched pattern

Handwritten initials "PSL"







psu



