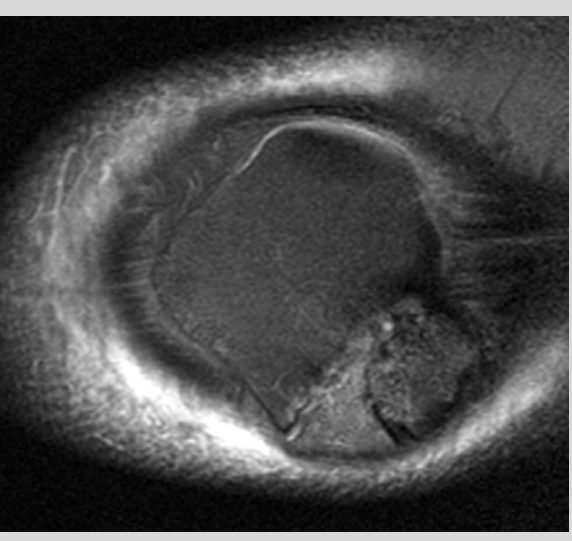
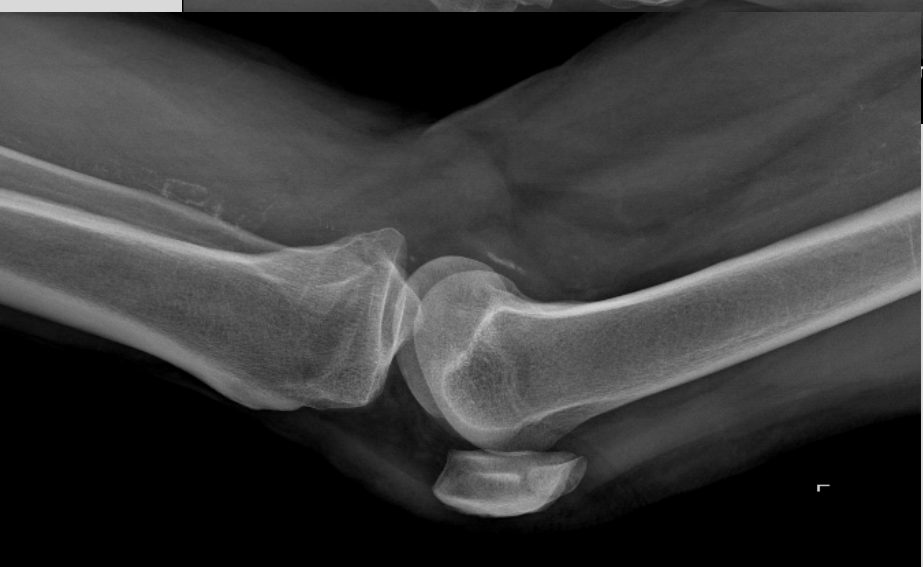
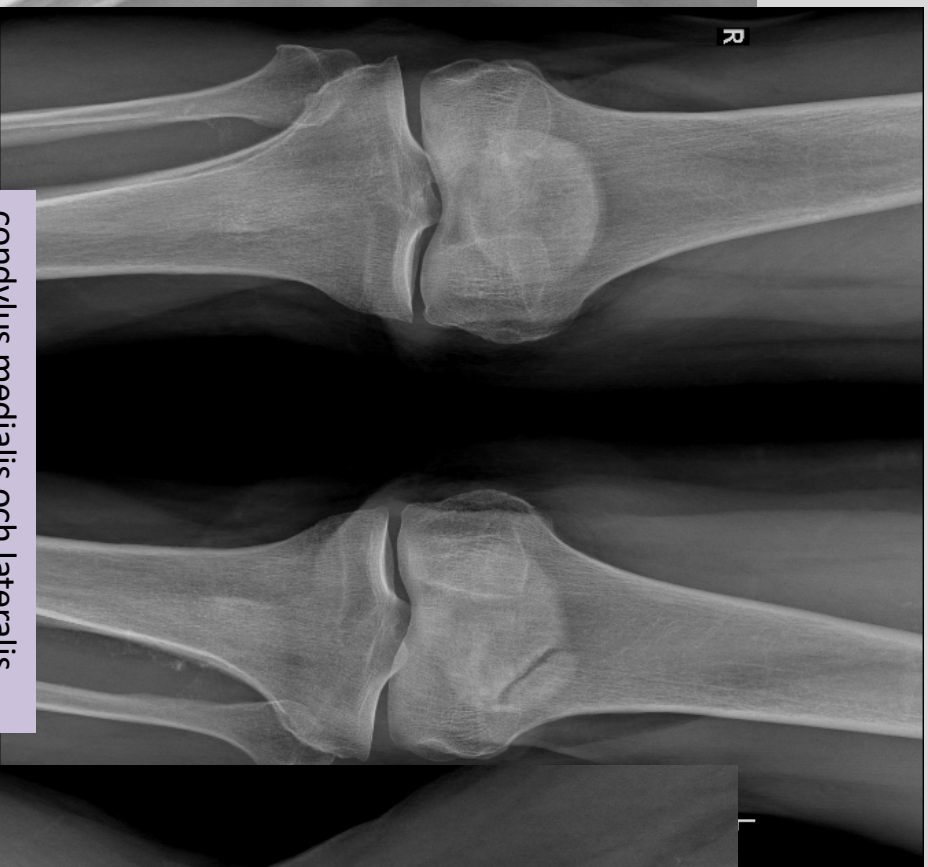
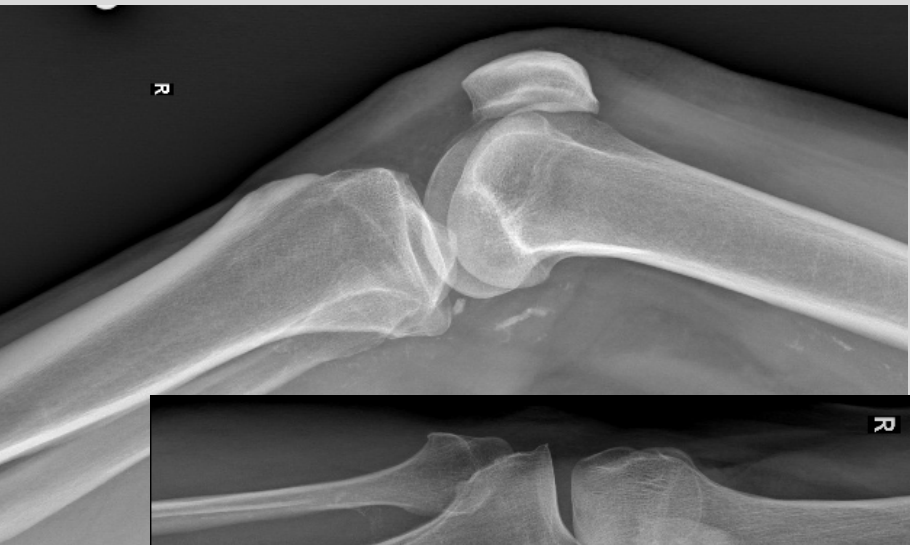Anatomi

Pawel Szaro, MD, PhD

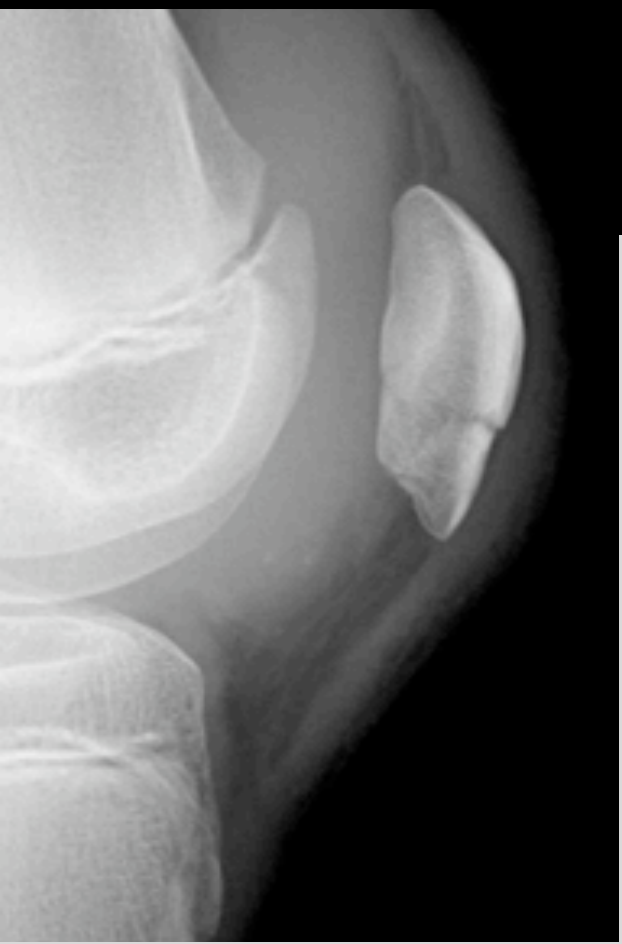
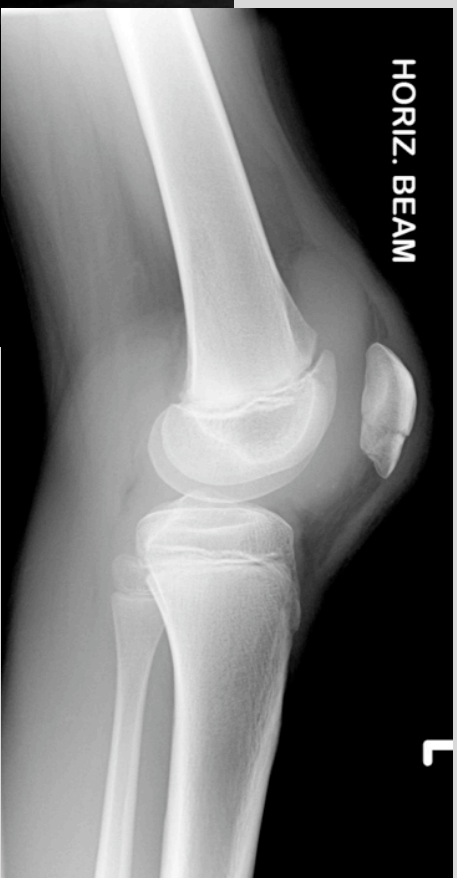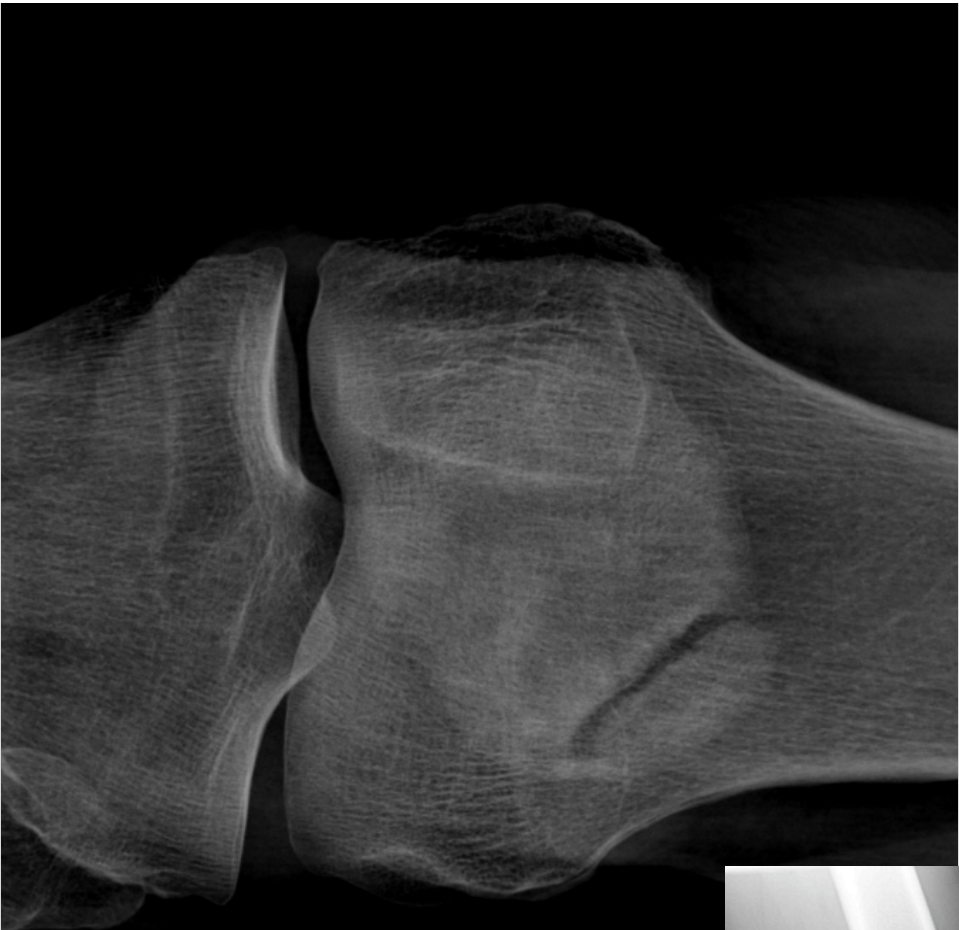Överläkare, MSK Sektion/Radiologi SU,
Göteborg



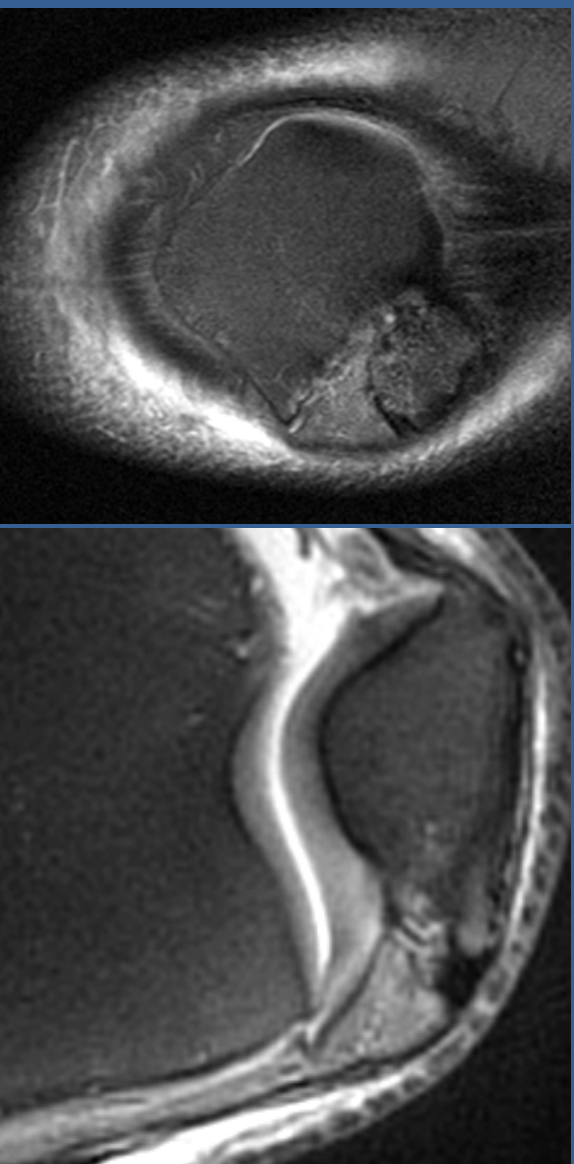


condylus medialis och lateralis
tuberositas tibiae
basis patellae
apex patellae

Patella bipartita vs. fraktur

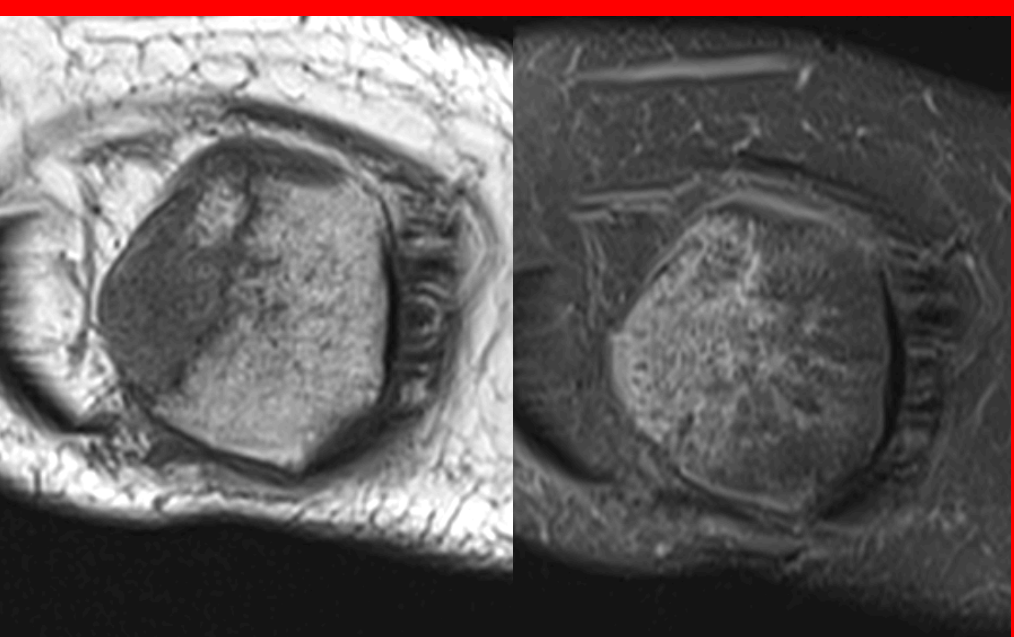


Pitfall

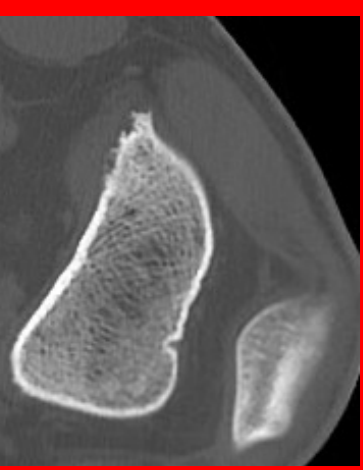
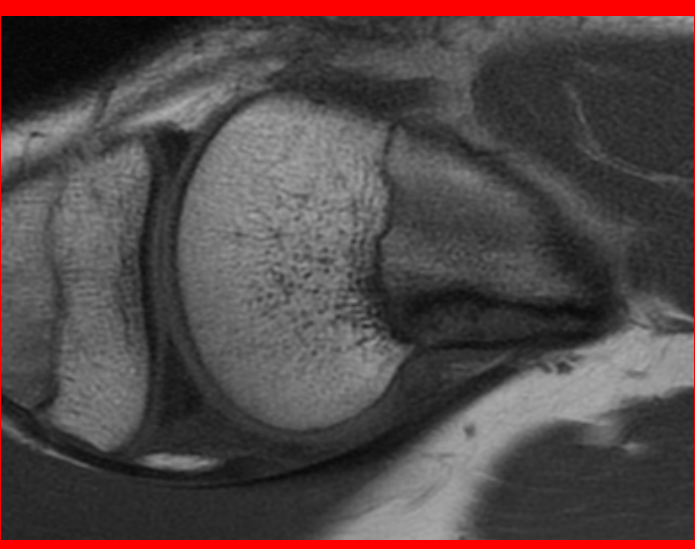
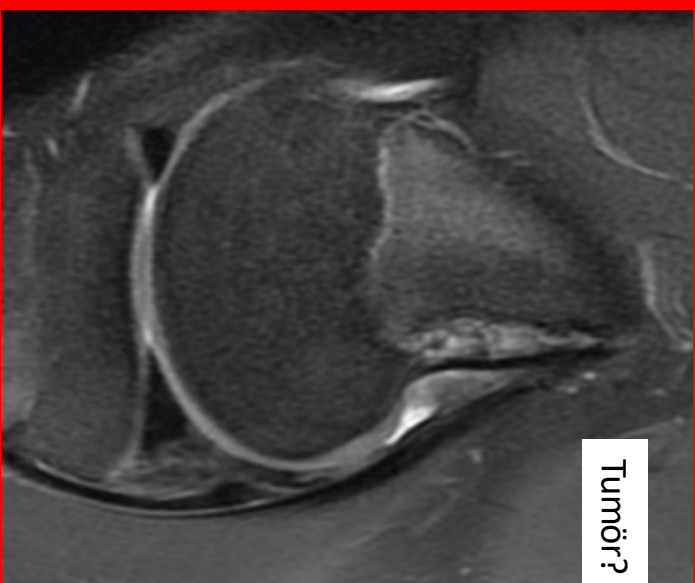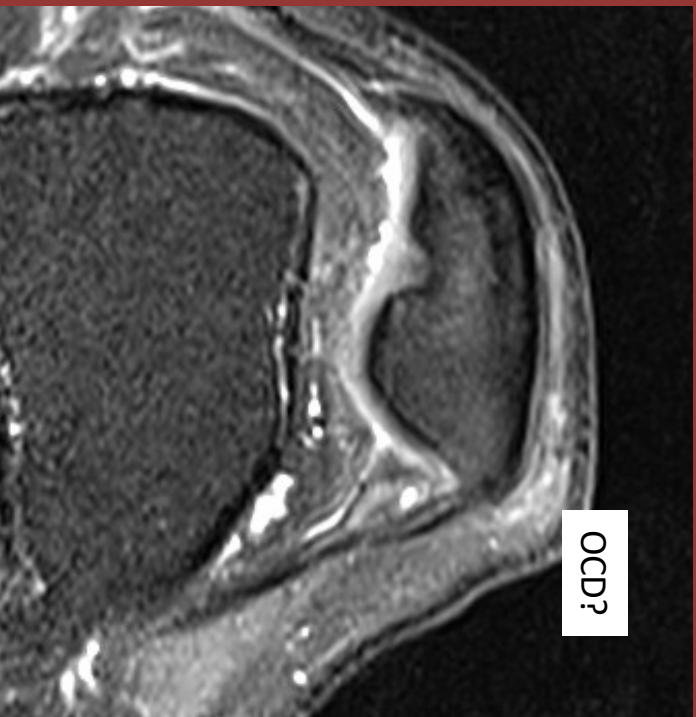


fraktur?

Patella bi/tripartite/multipartite



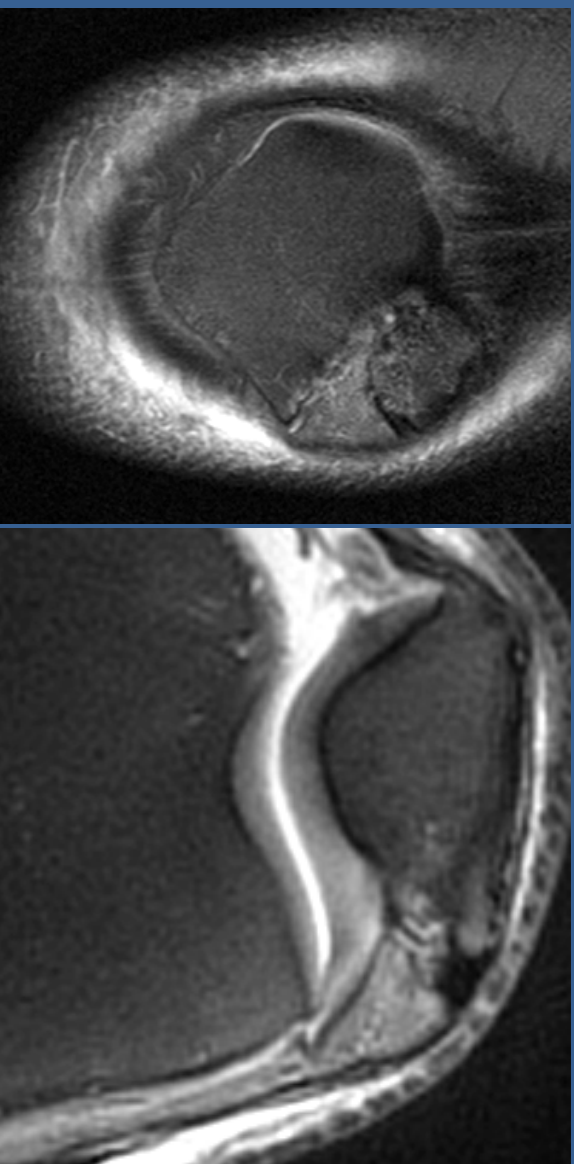
Pitfall



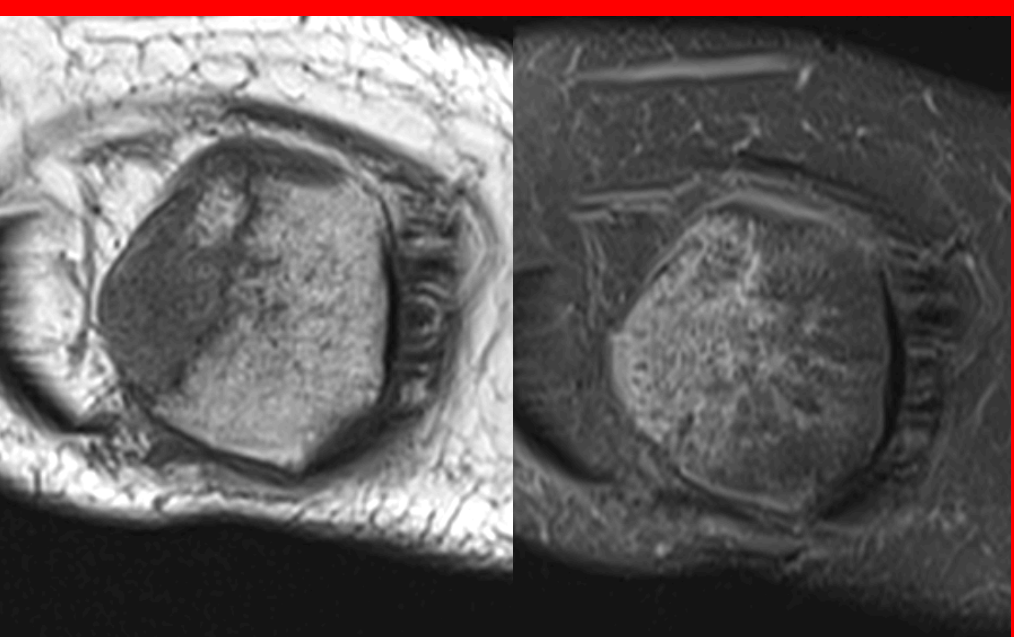
Cortical desmoid

Pitfall

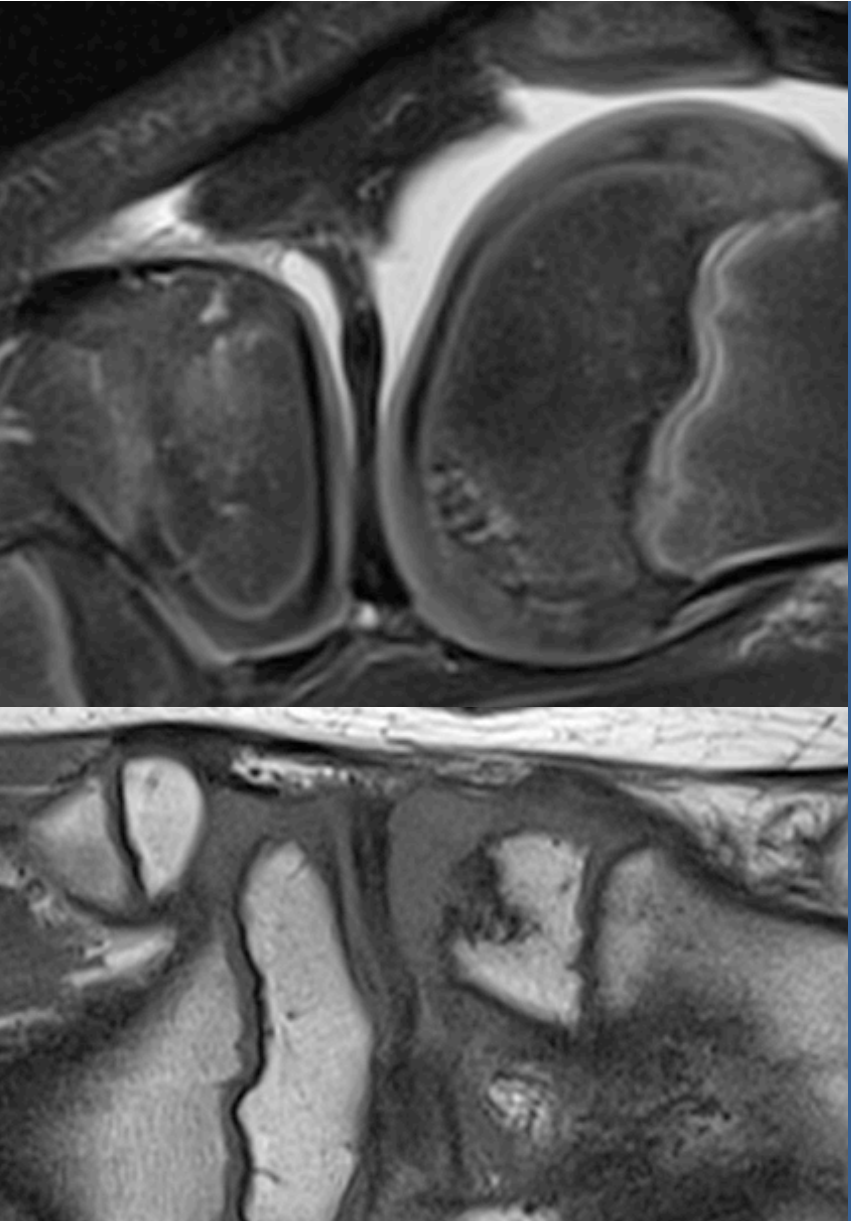
fraktur?



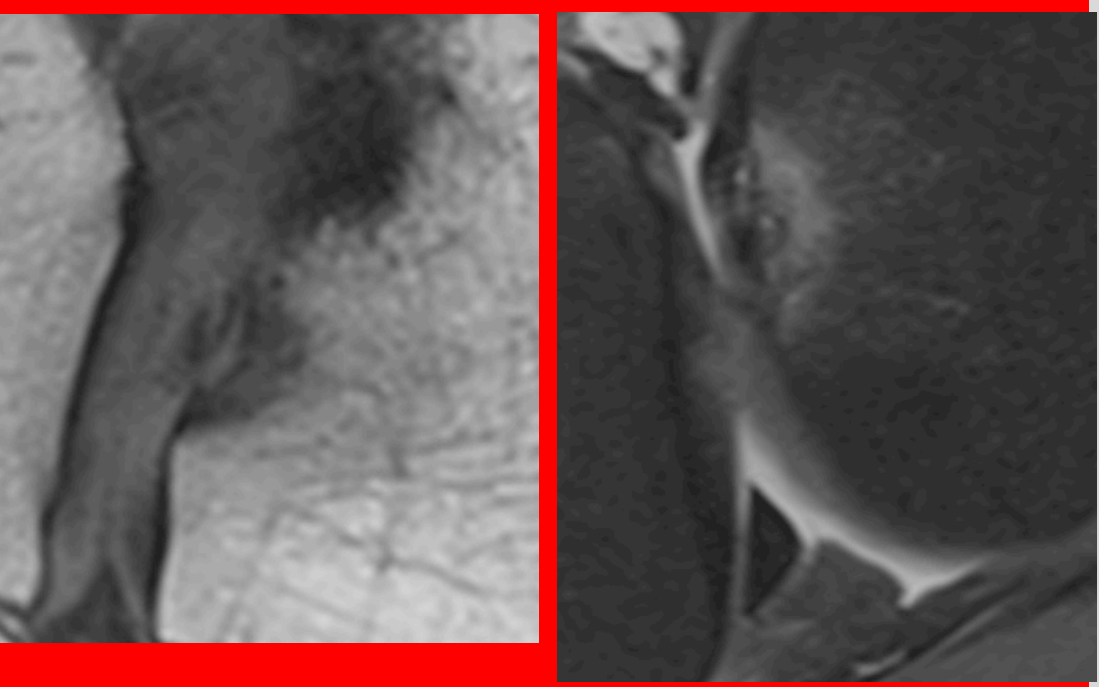
Patella bi/tripartite/multipartite



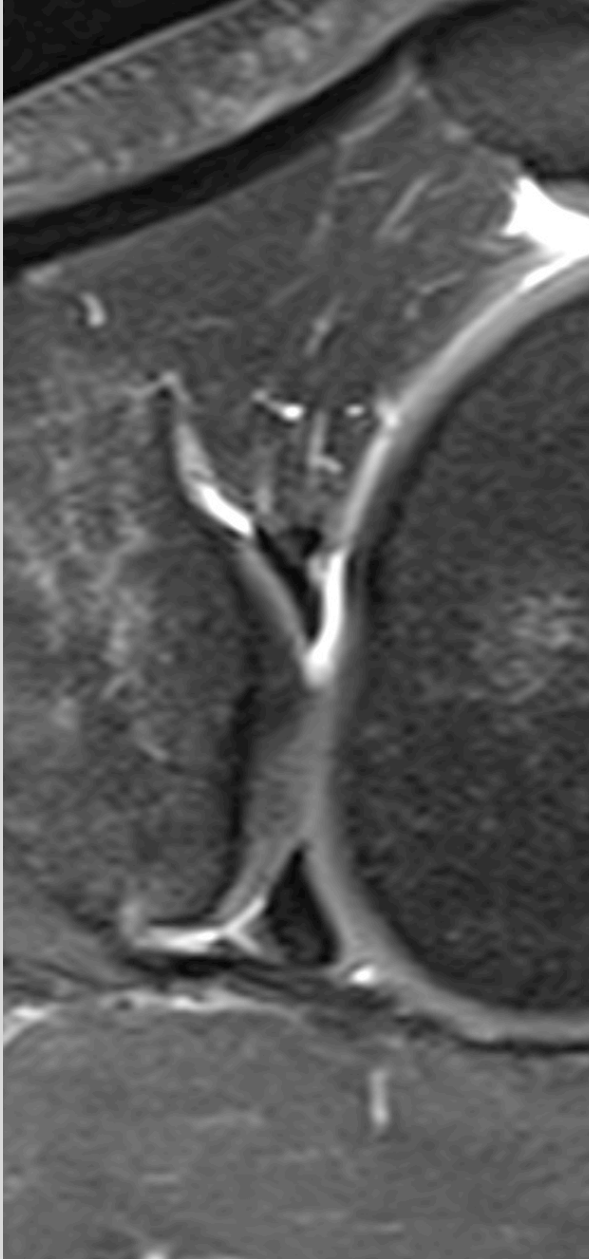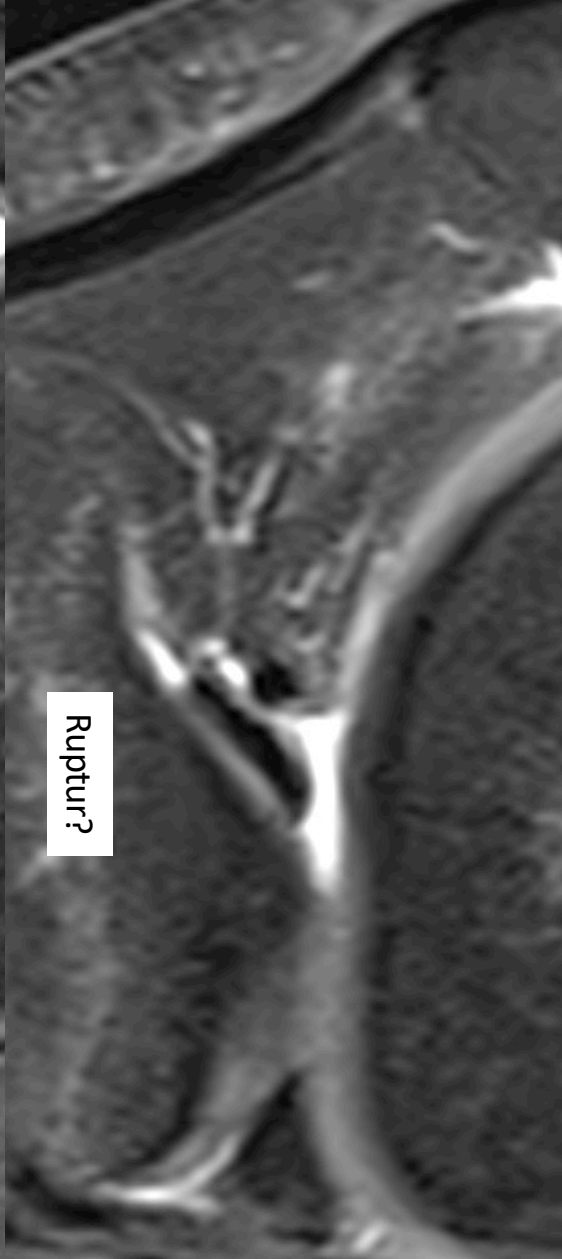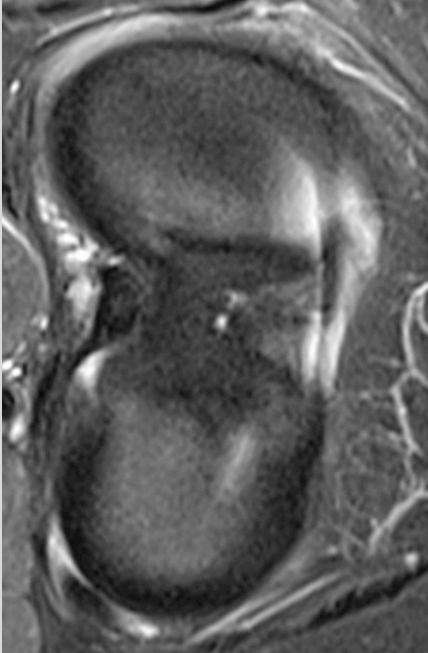
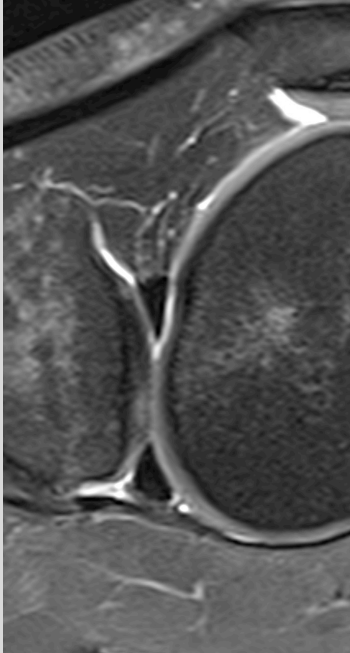
Pitfall



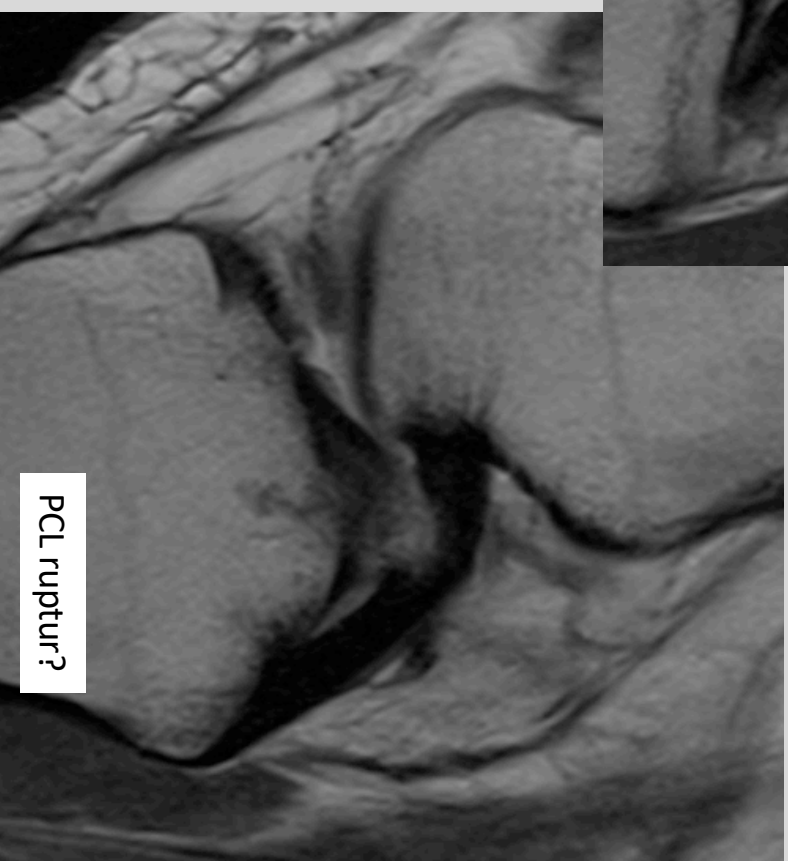
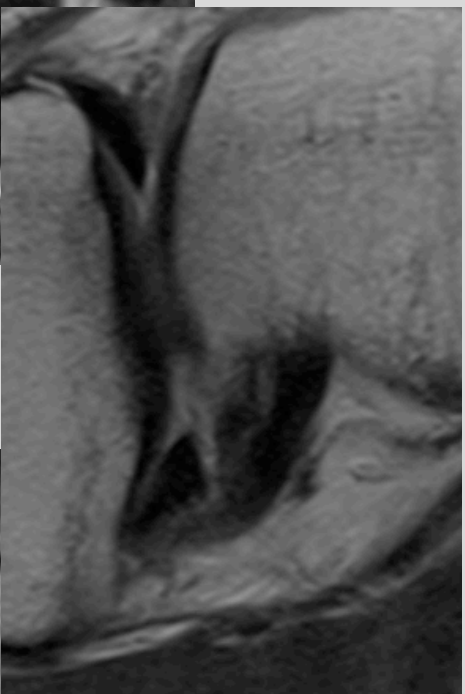
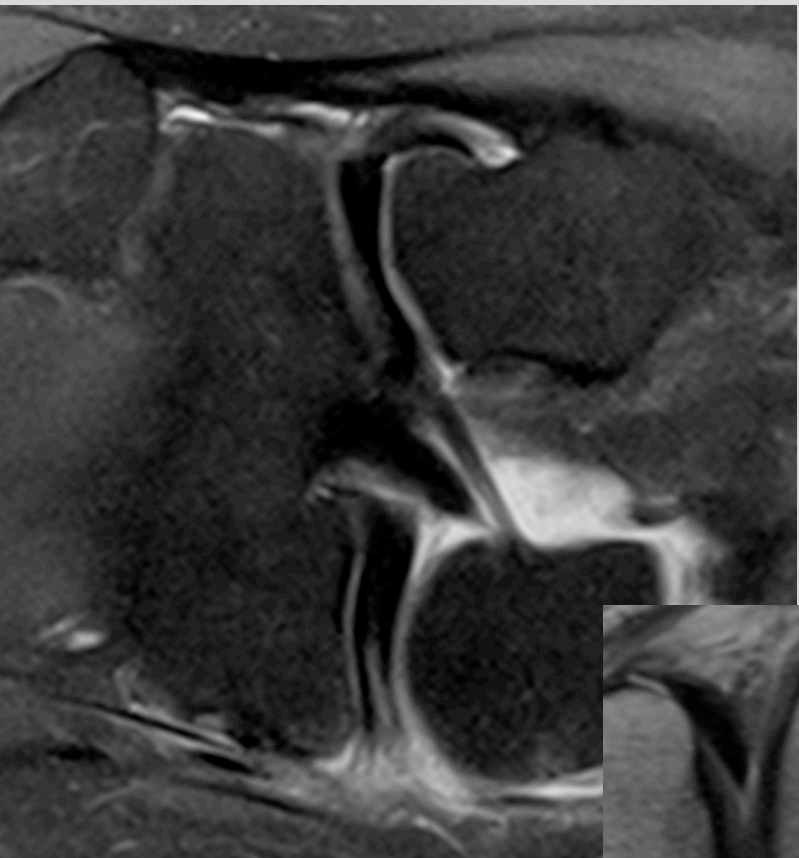
OCD?



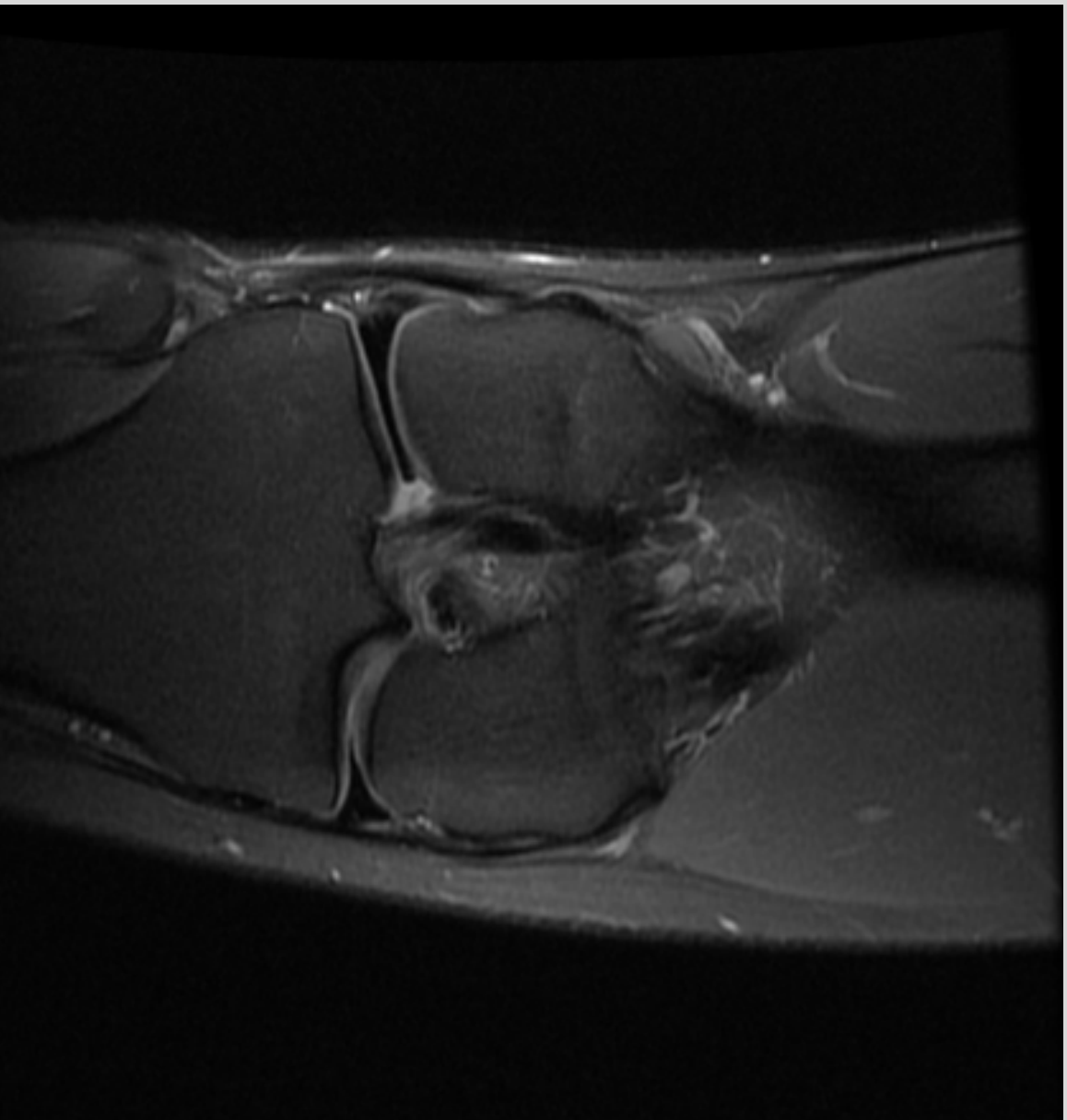
Diffusion



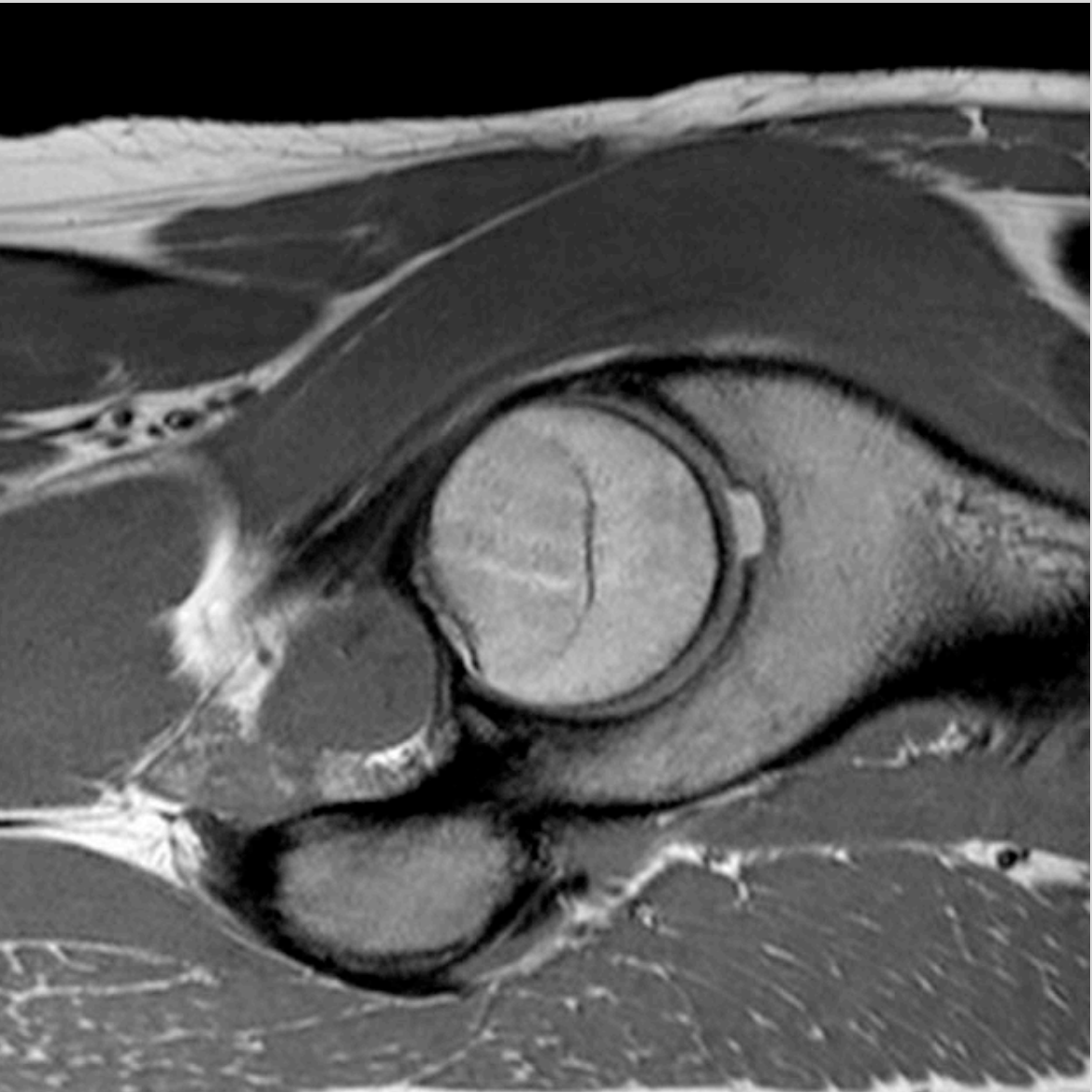
Pitfall



Discoid meniscus

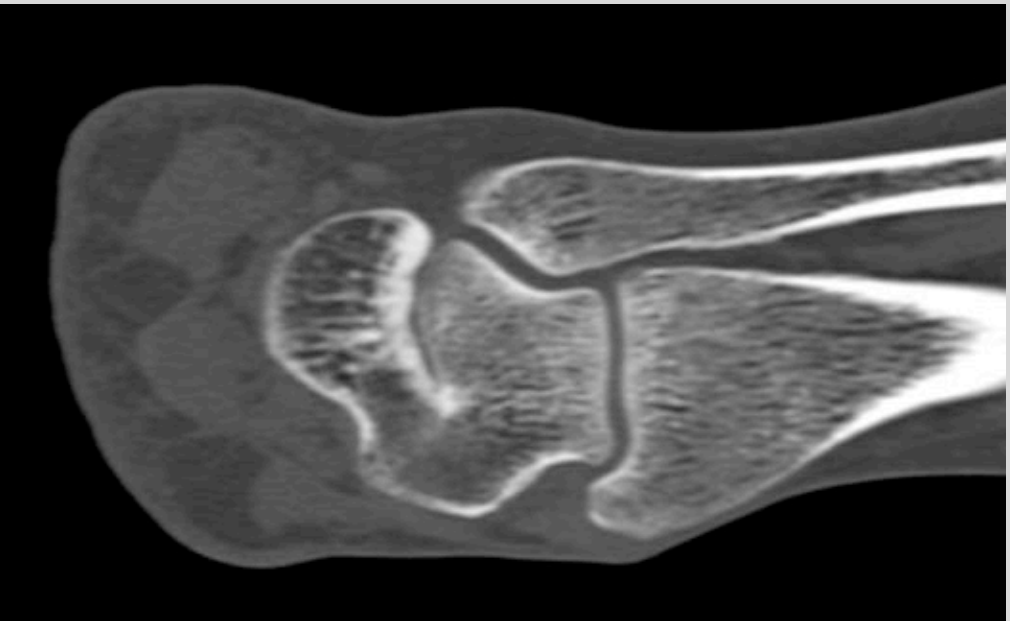

Supra-acetabular fossa

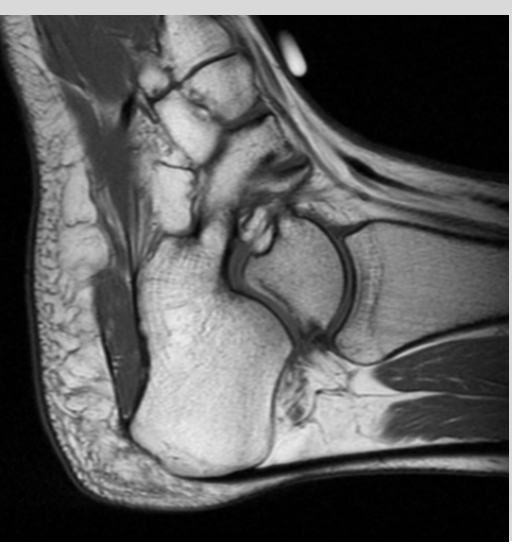
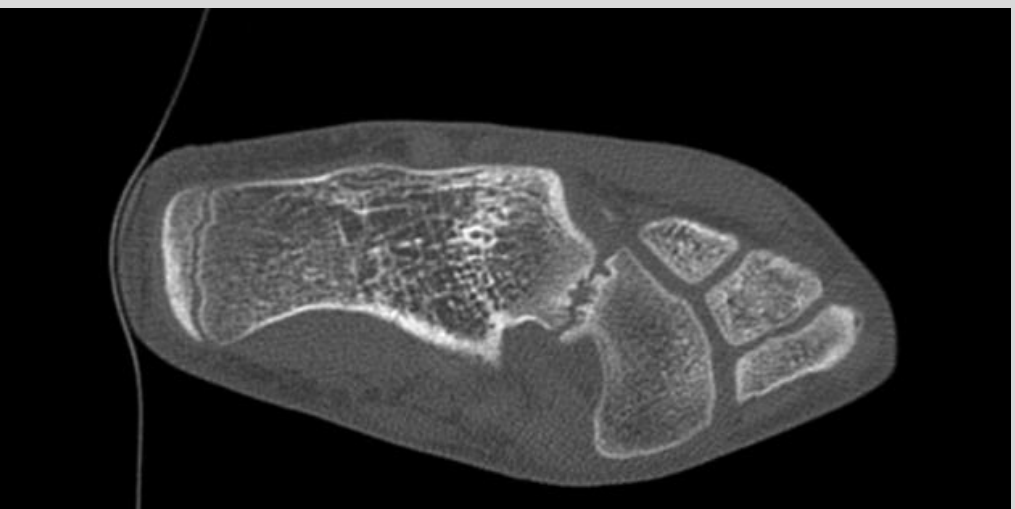
Coalitio

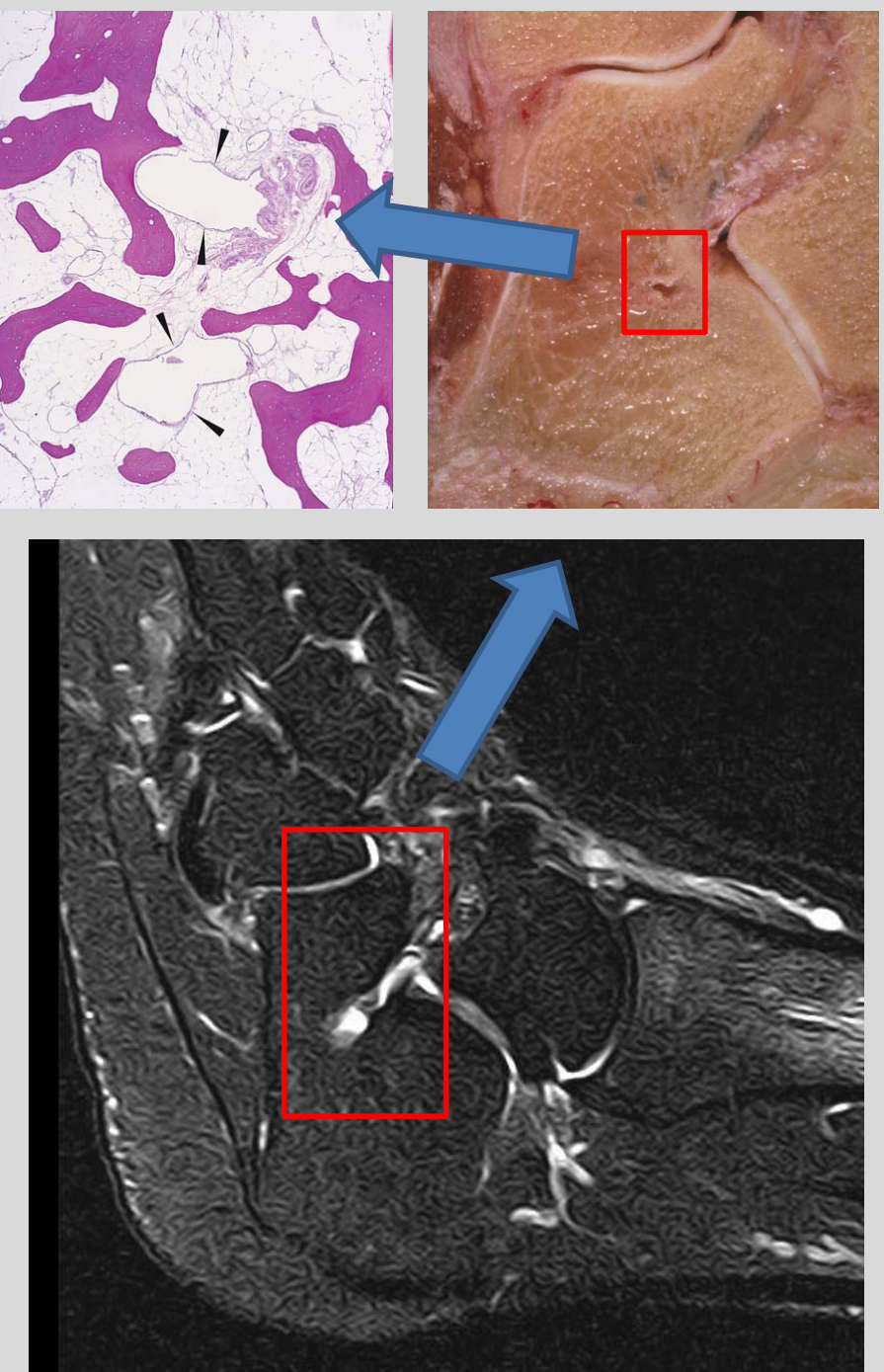
talocalcaneal



calcaneonavicular



Pitfall



Fleming, Dodd, and Helms, "Prominent Vascular Remnants in the Calcaneus Simulating a Lesion on MRI of the Ankle."

Lunotriquetral coalitio

