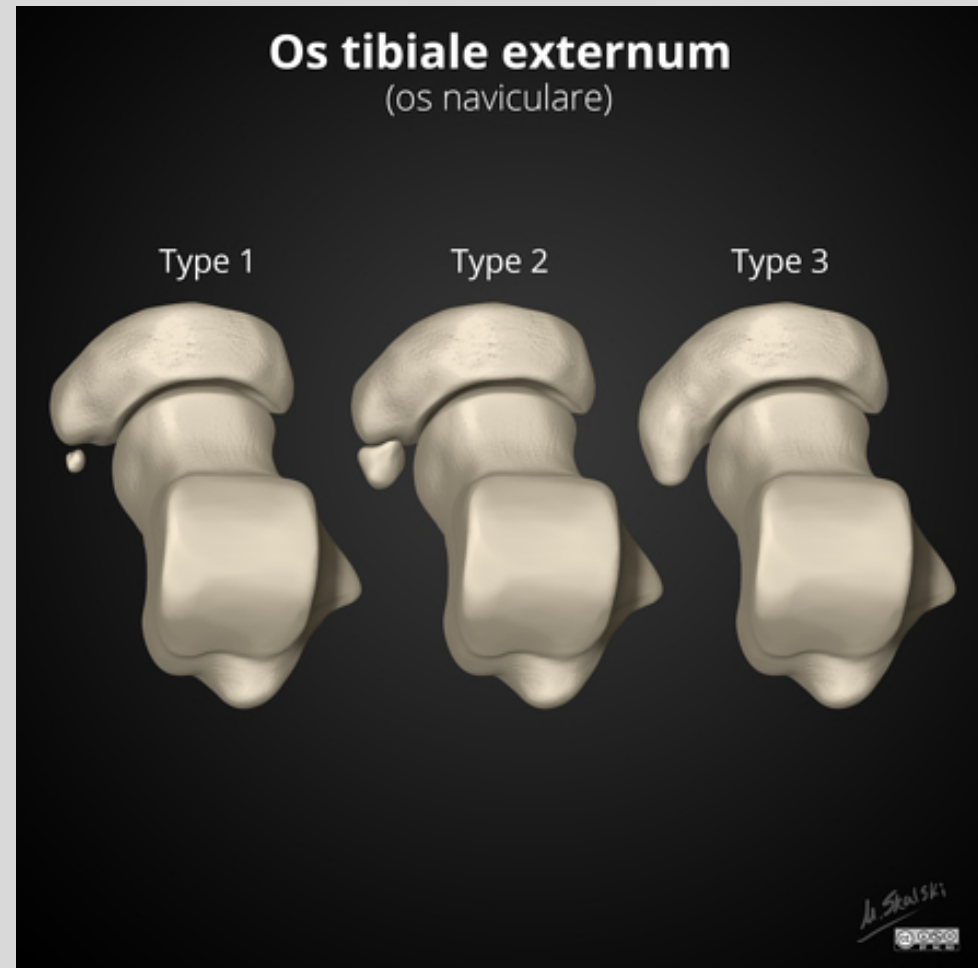


- Case på PostDicom

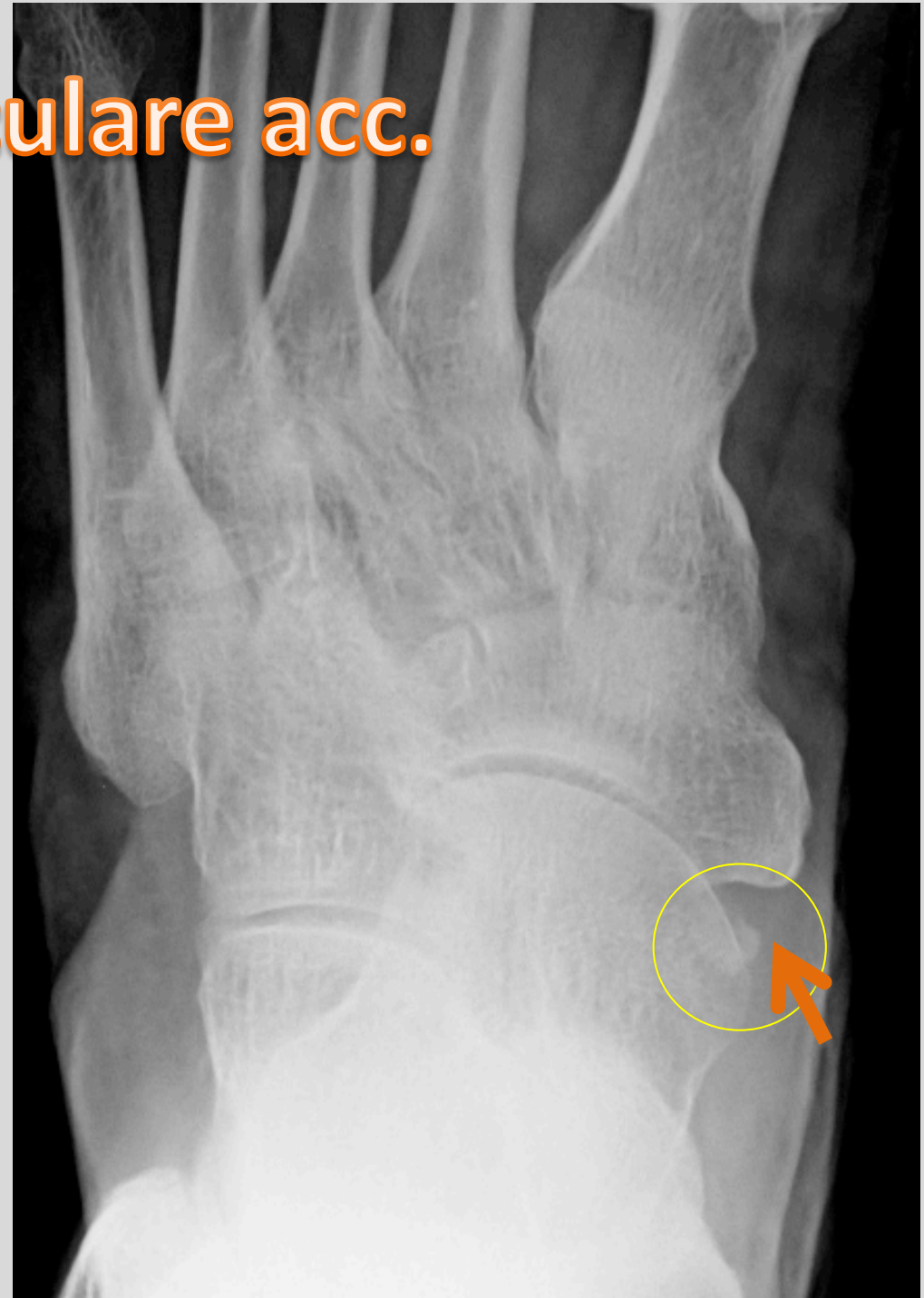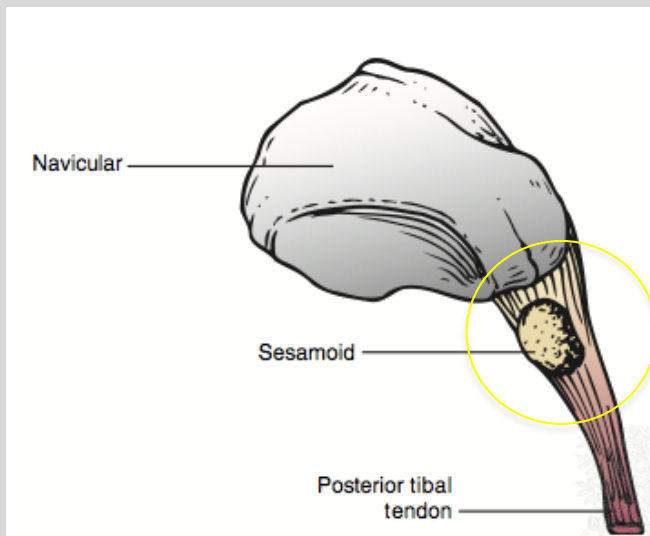
Ett litet benfragment i anslutning till os naviculare

- os naviculare
accessorium
 - typ 1- in i tibialis
posterior sena
 - typ 2
 - typ 3



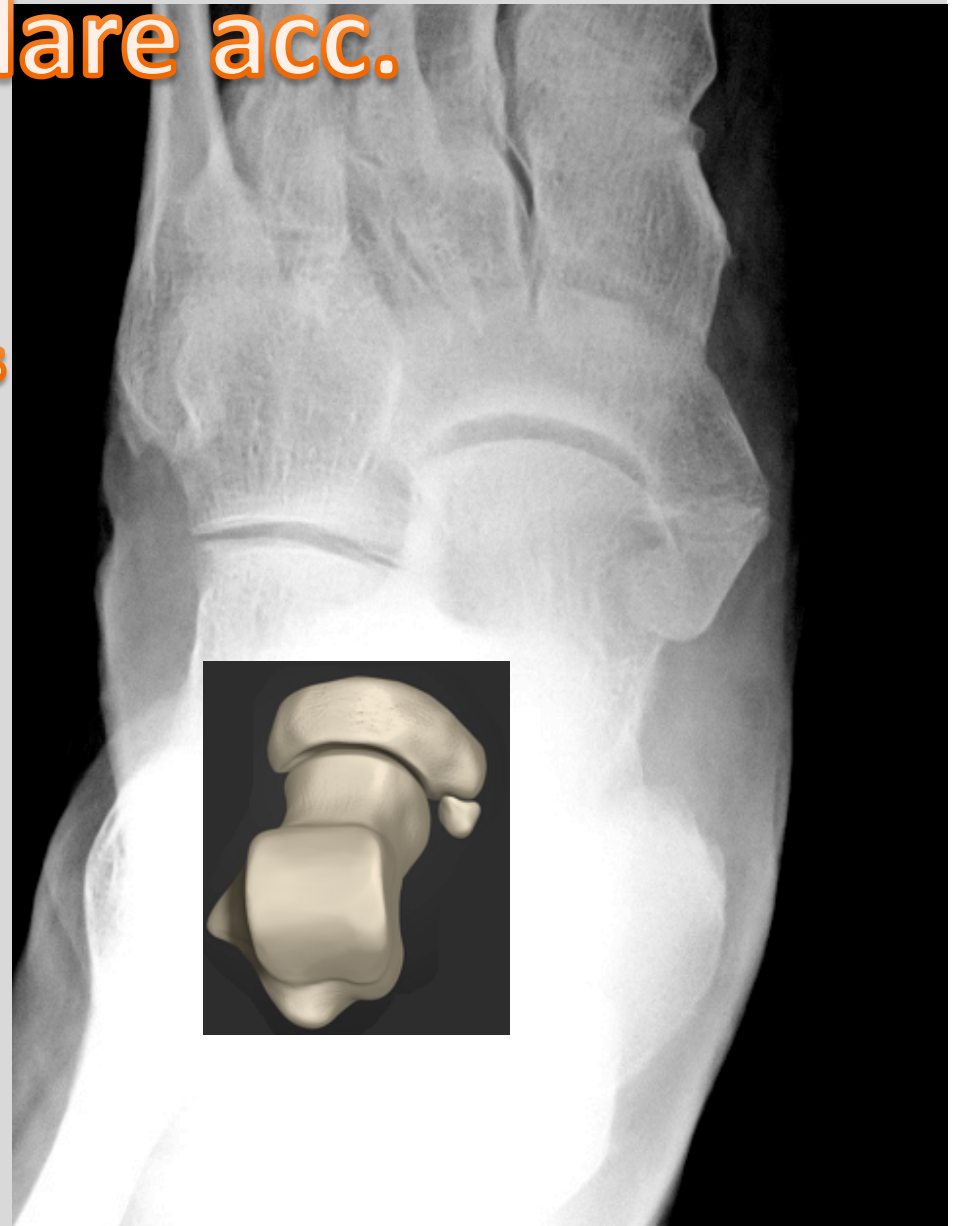
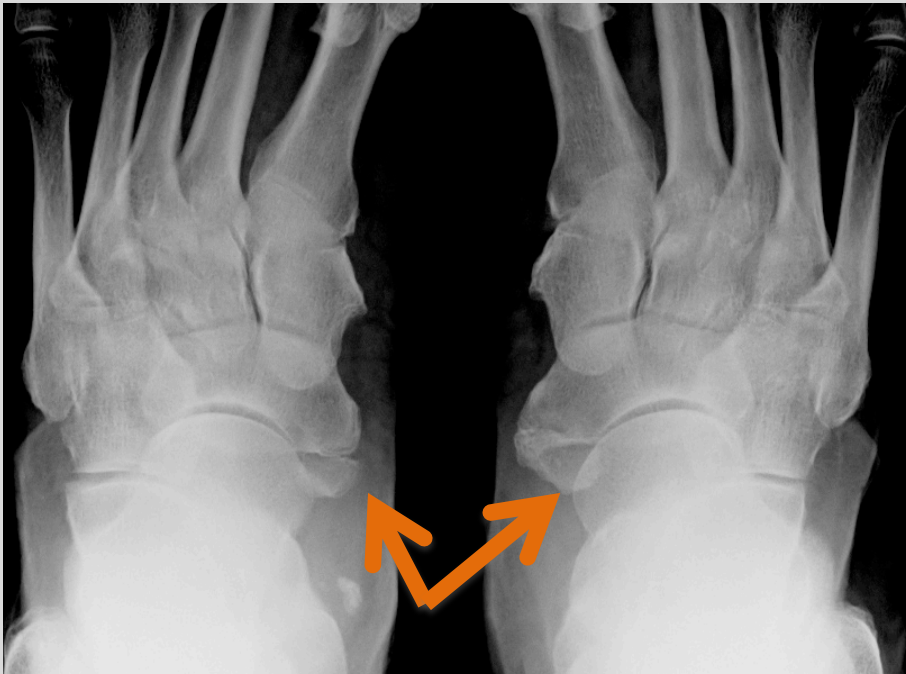Os naviculare acc.

- Type I
 - Sesamoid bone i tibialis posterior sena

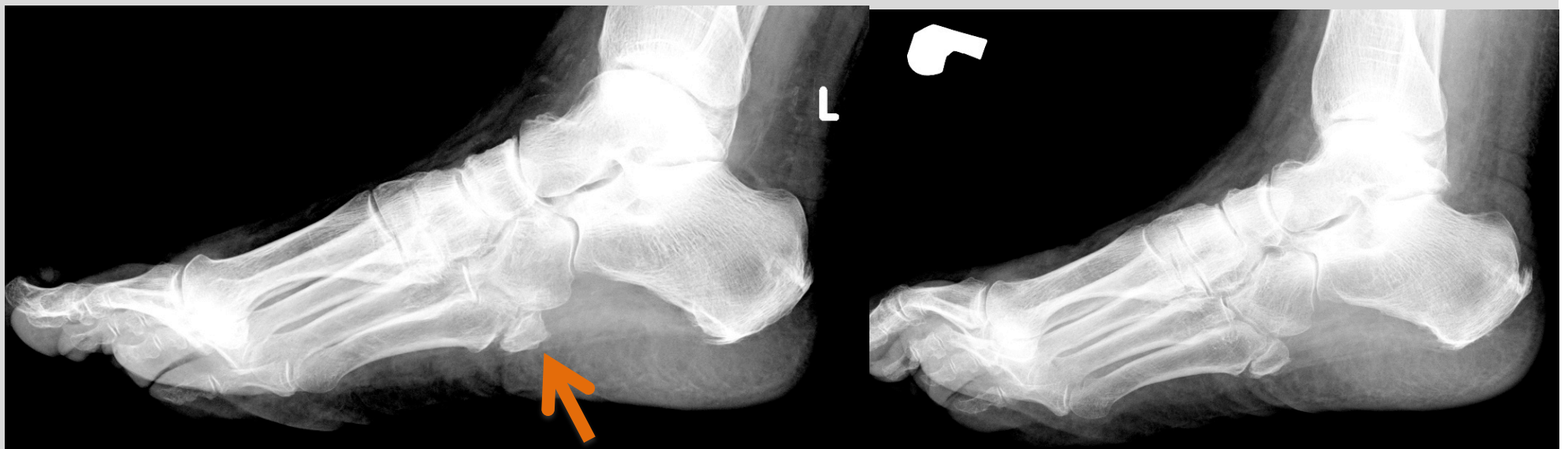
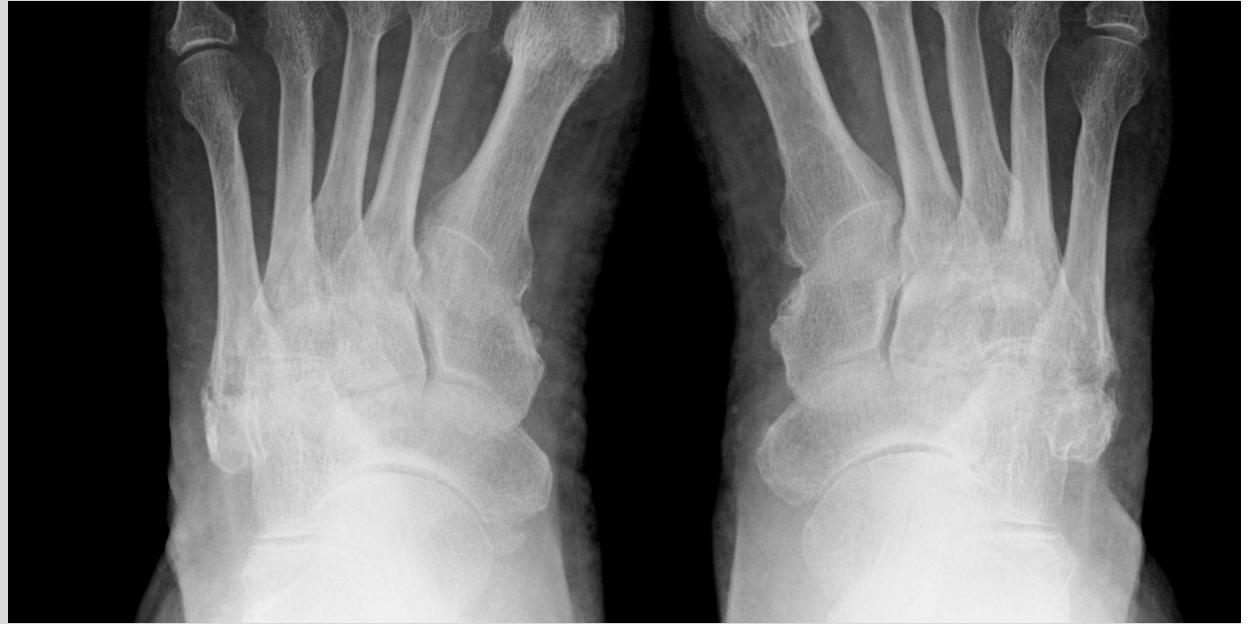

Os naviculare acc.

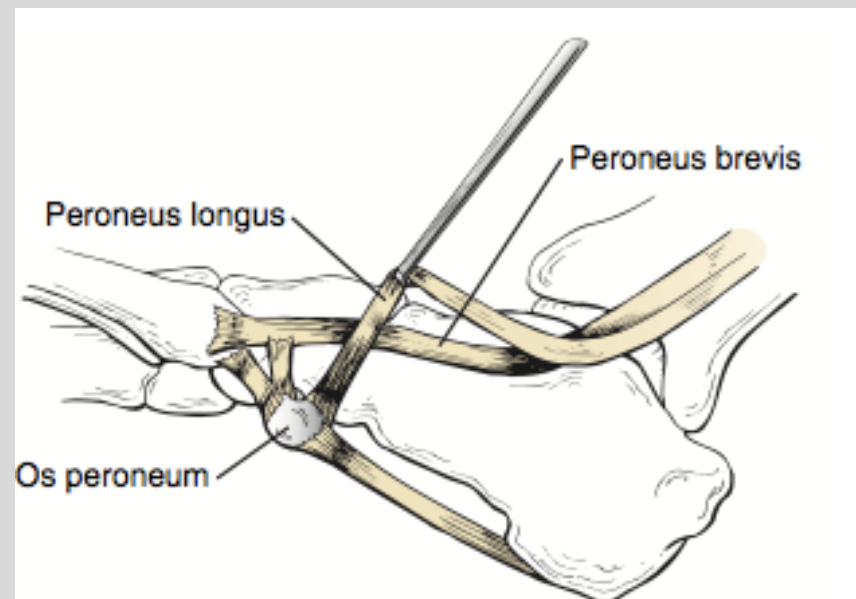
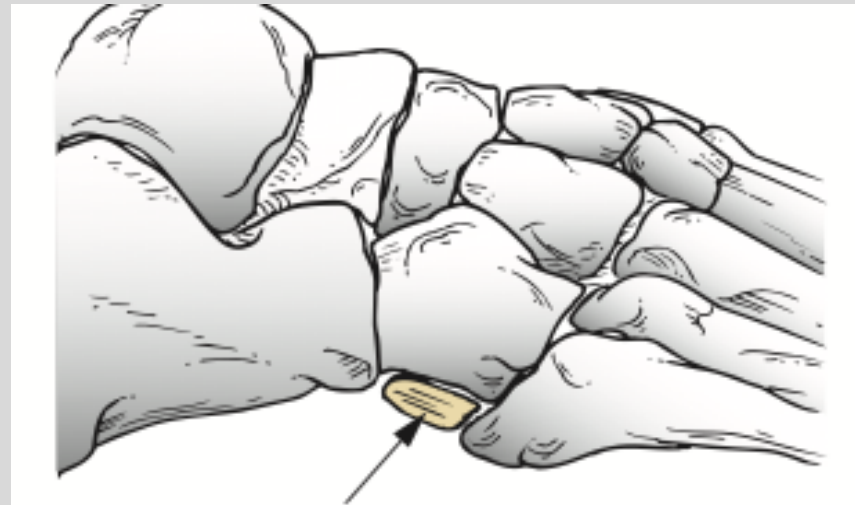
- Type II
 - I anslutning till tuberositas (fibrocartilage eller hyalinbrosk)



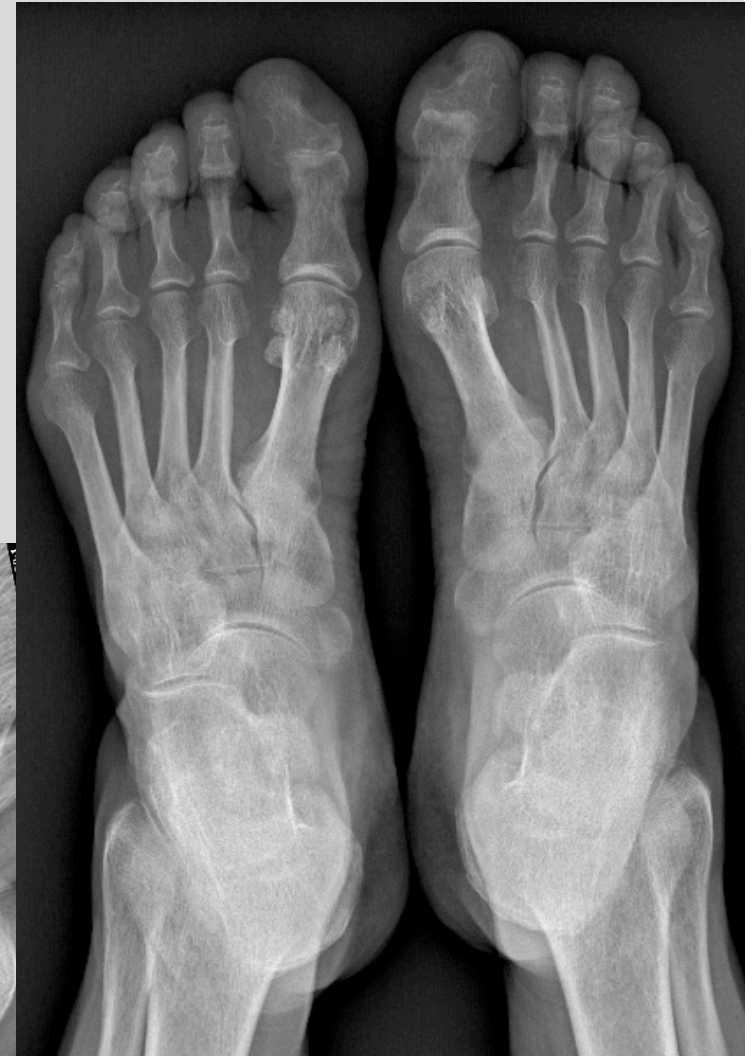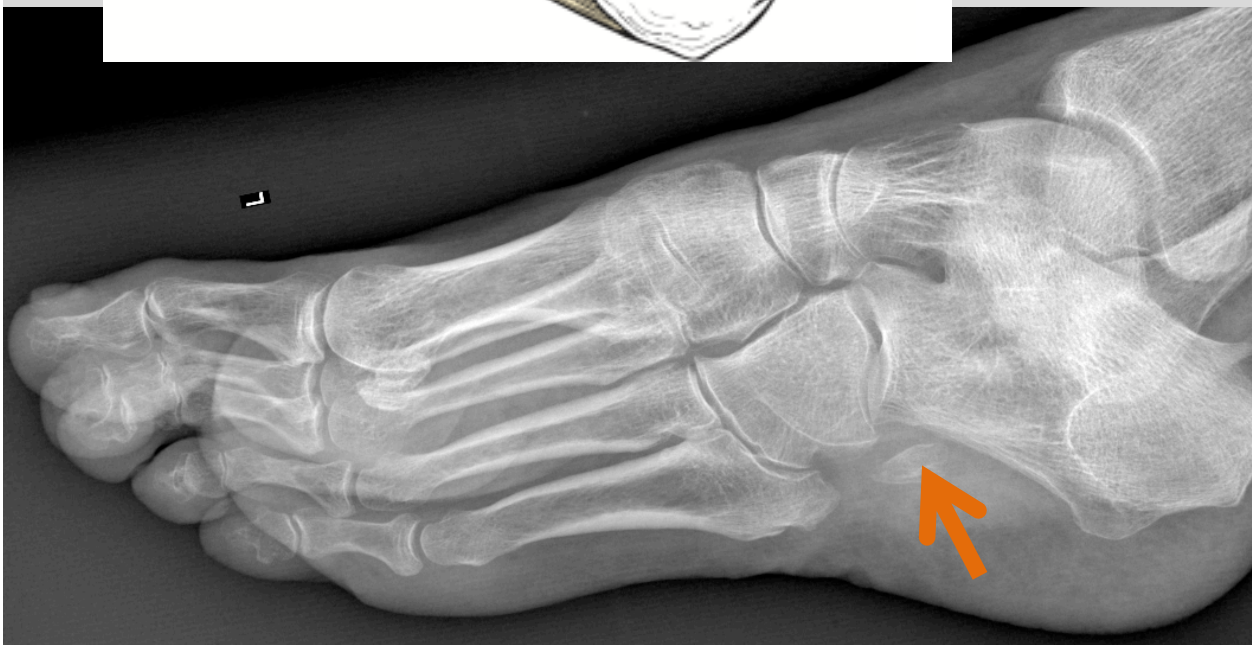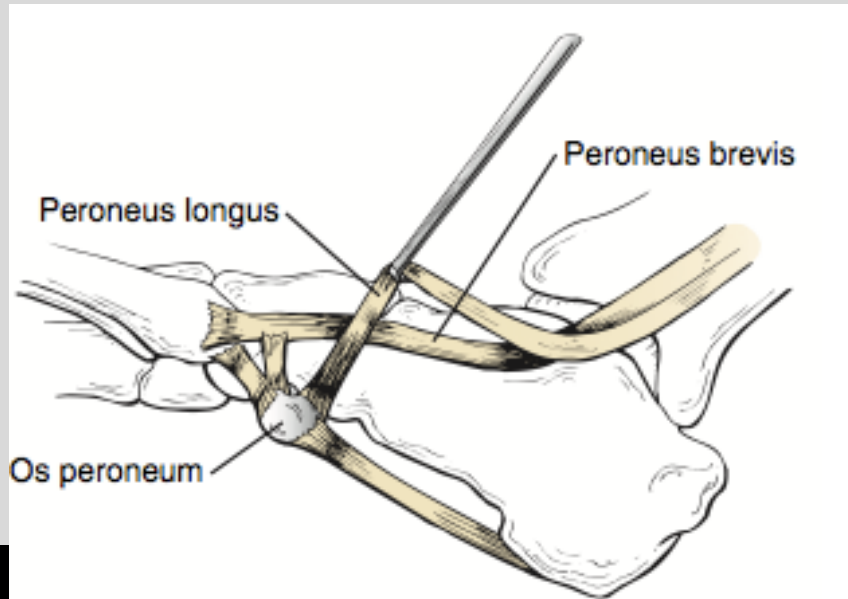
Os vesalianum



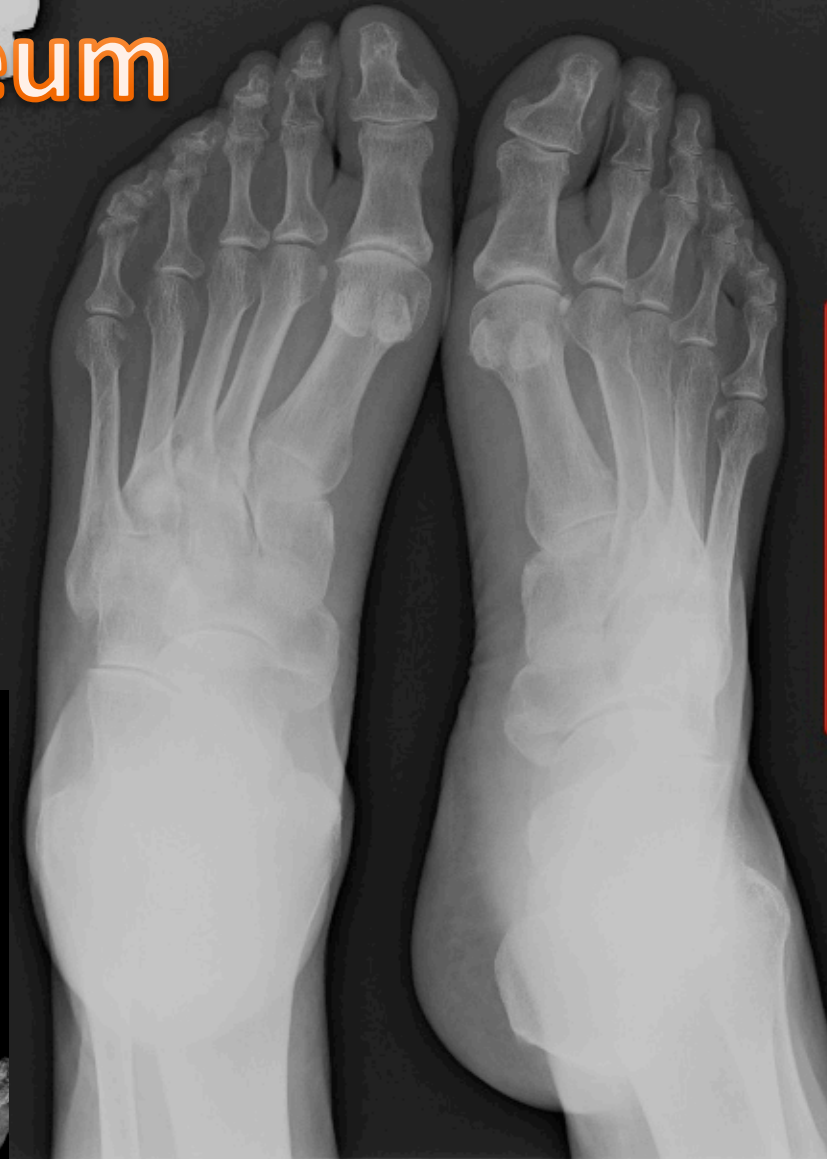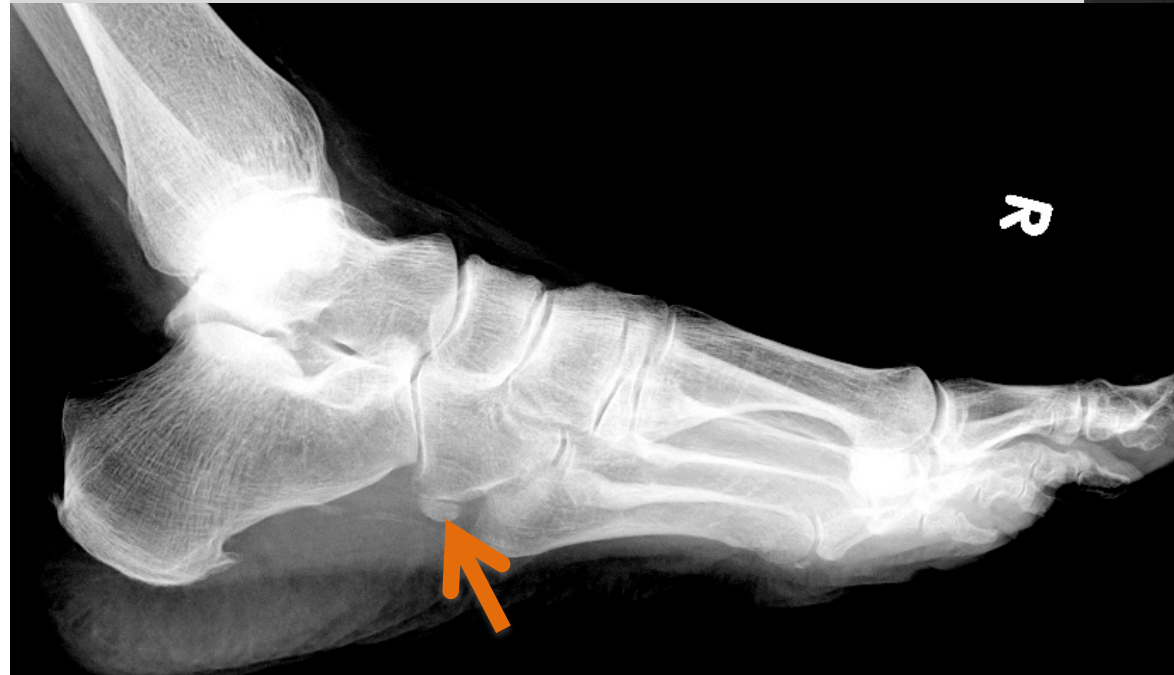Os peroneum



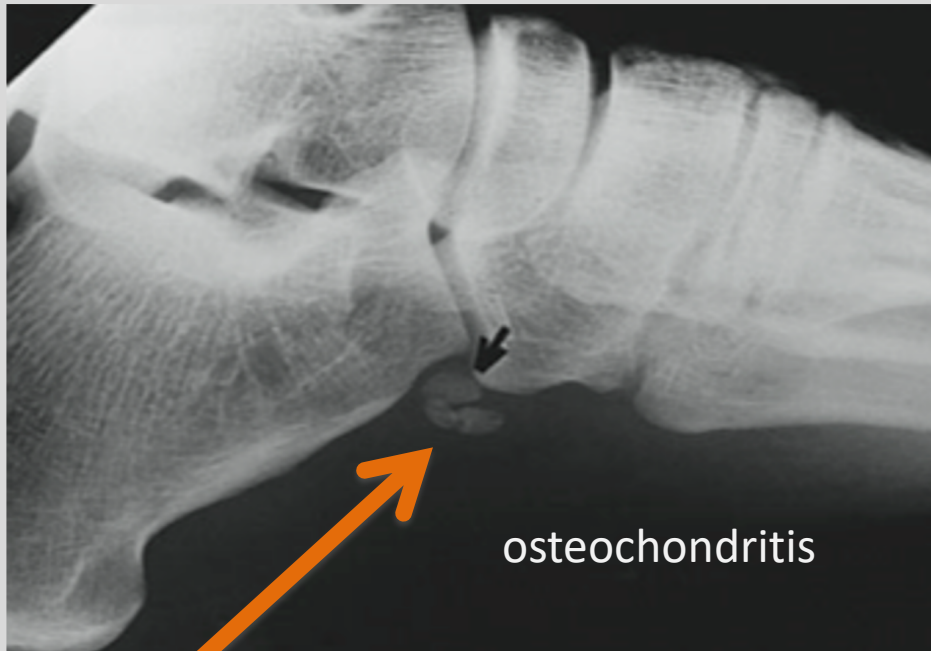
Os peroneum



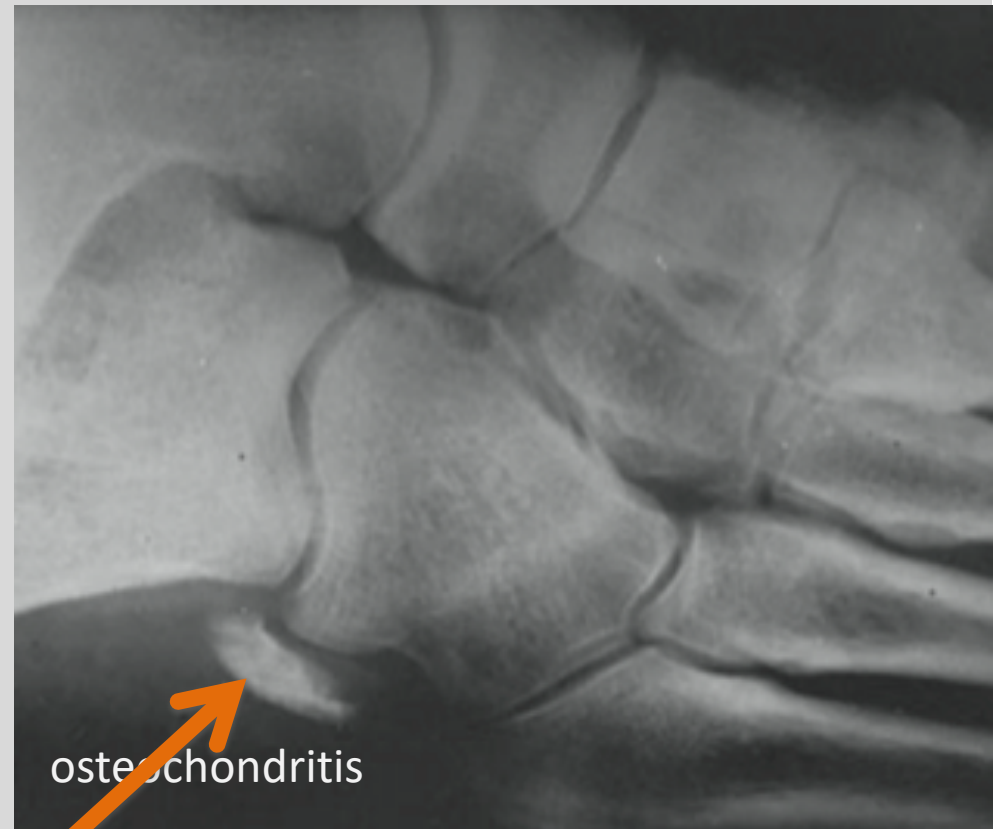
Os peroneum



Symptomatisk os peroneum

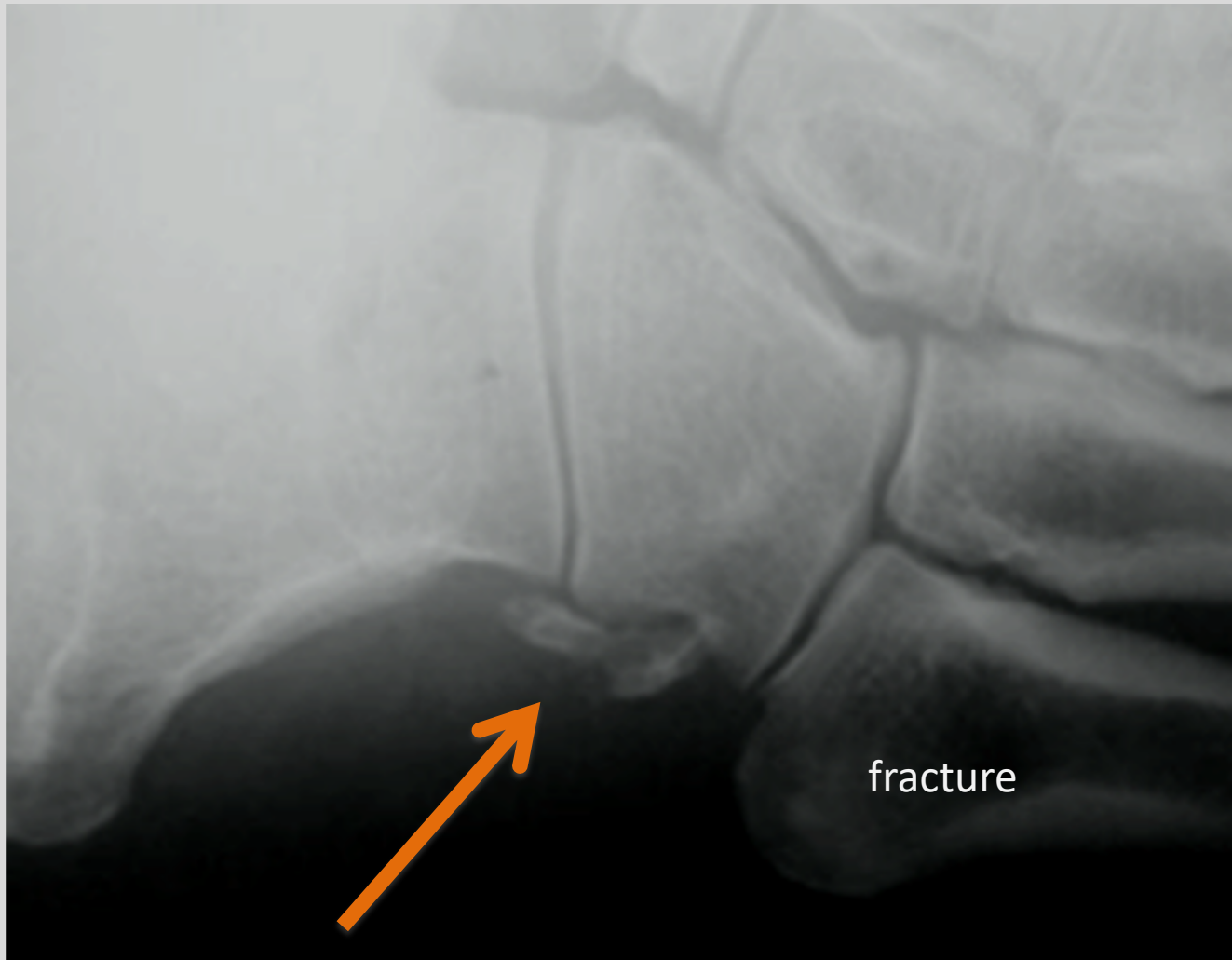


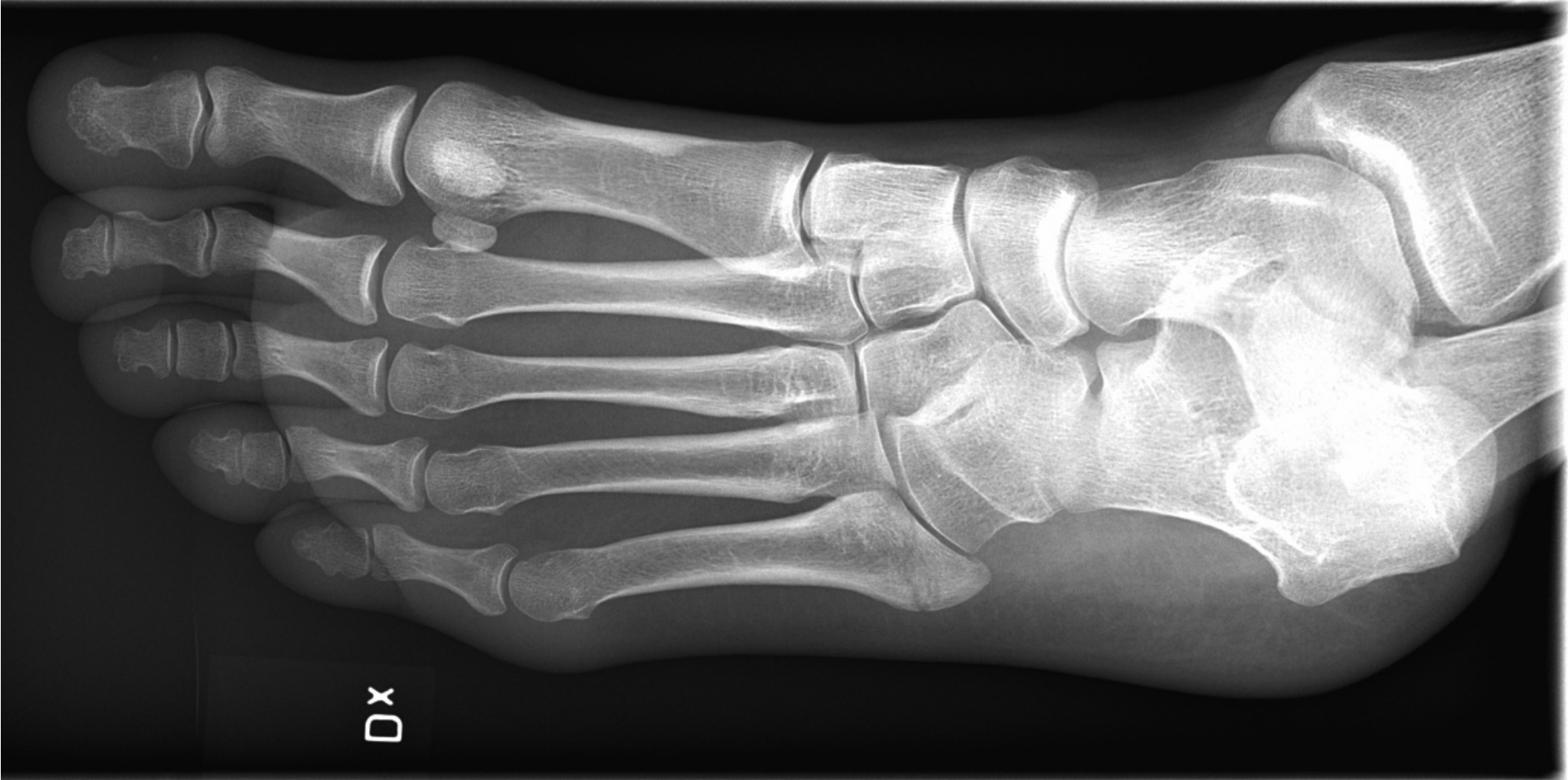osteochondritis



osteochondritis

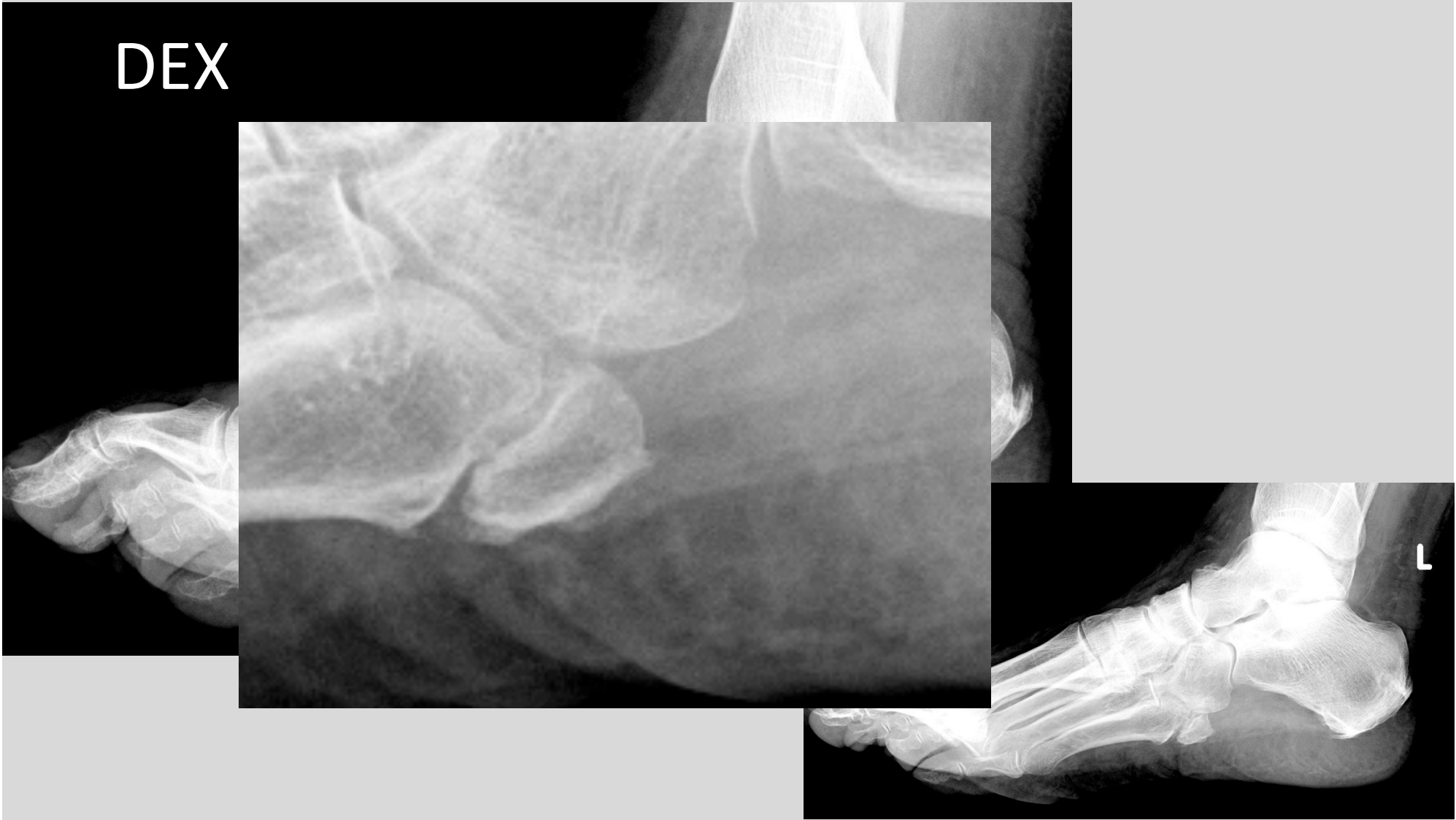Symptomatisk os peroneum

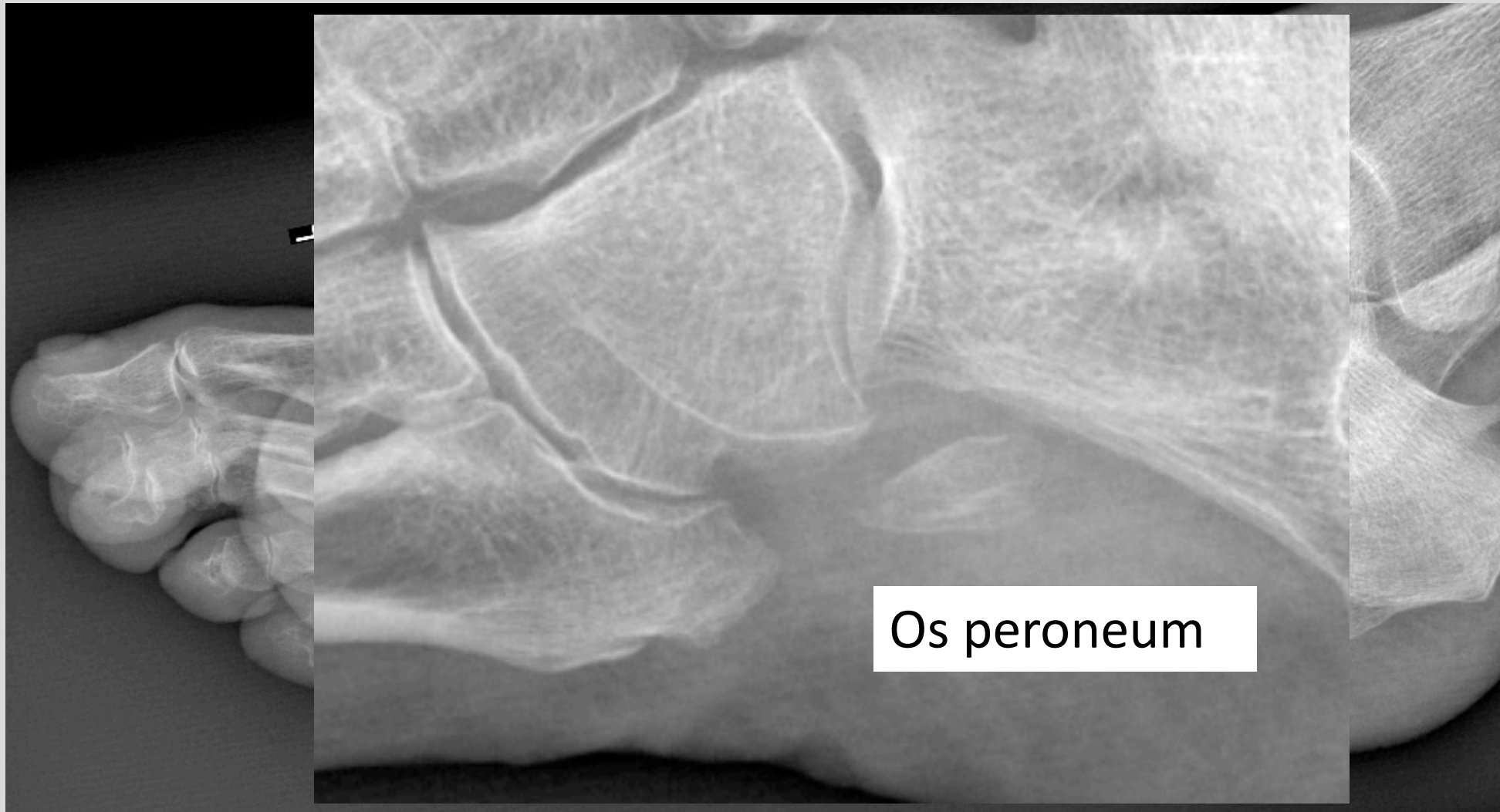



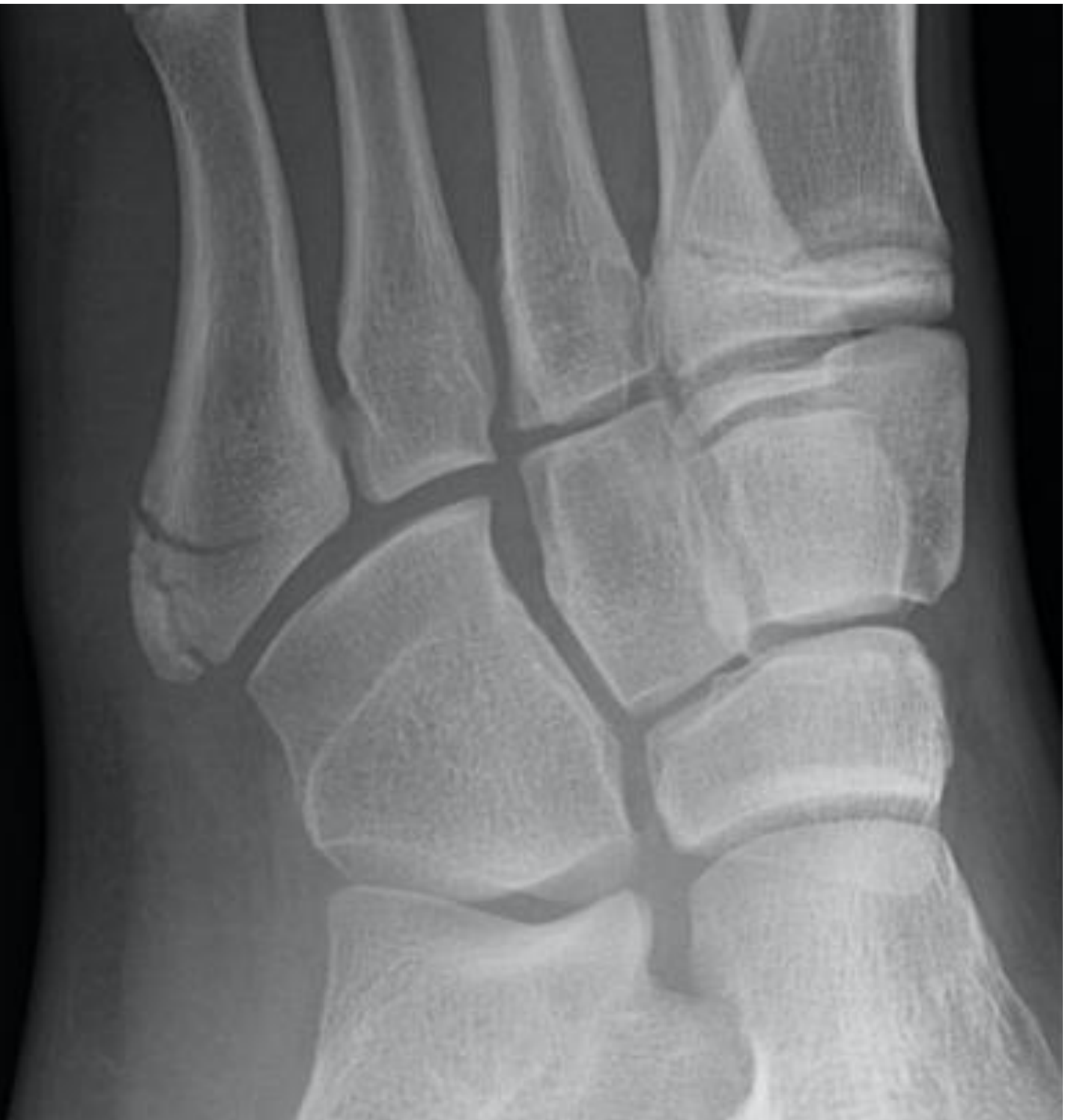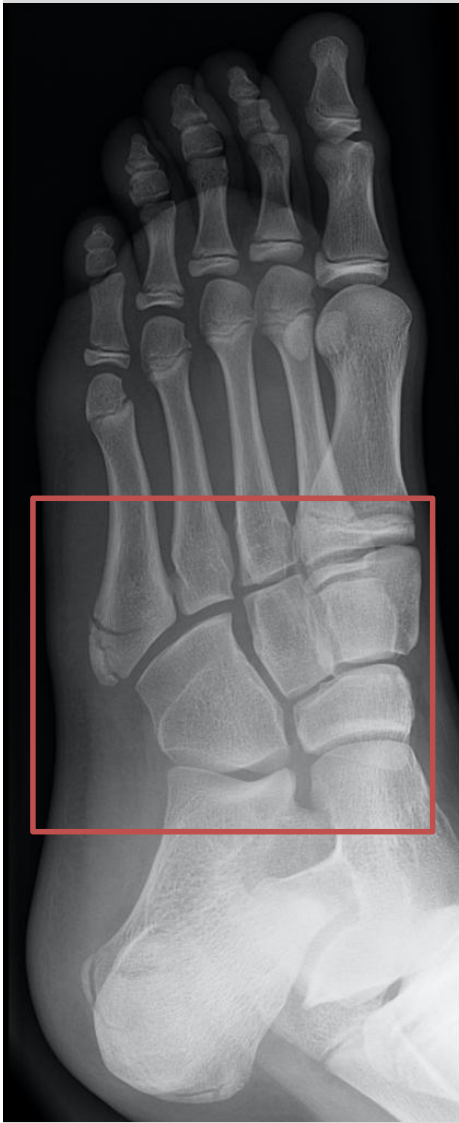Dx

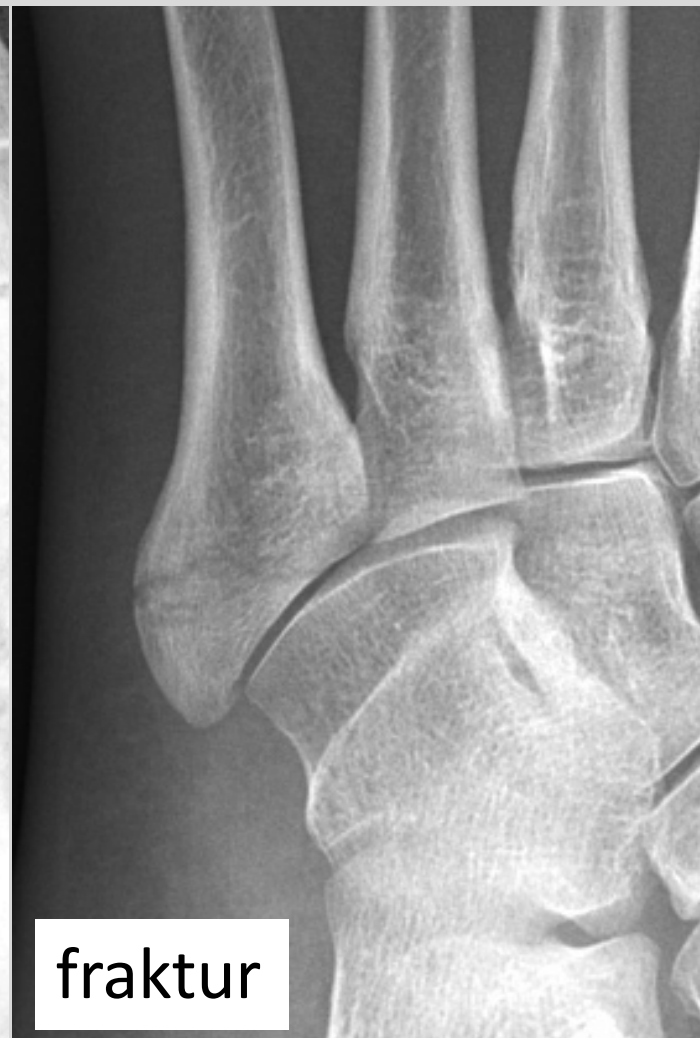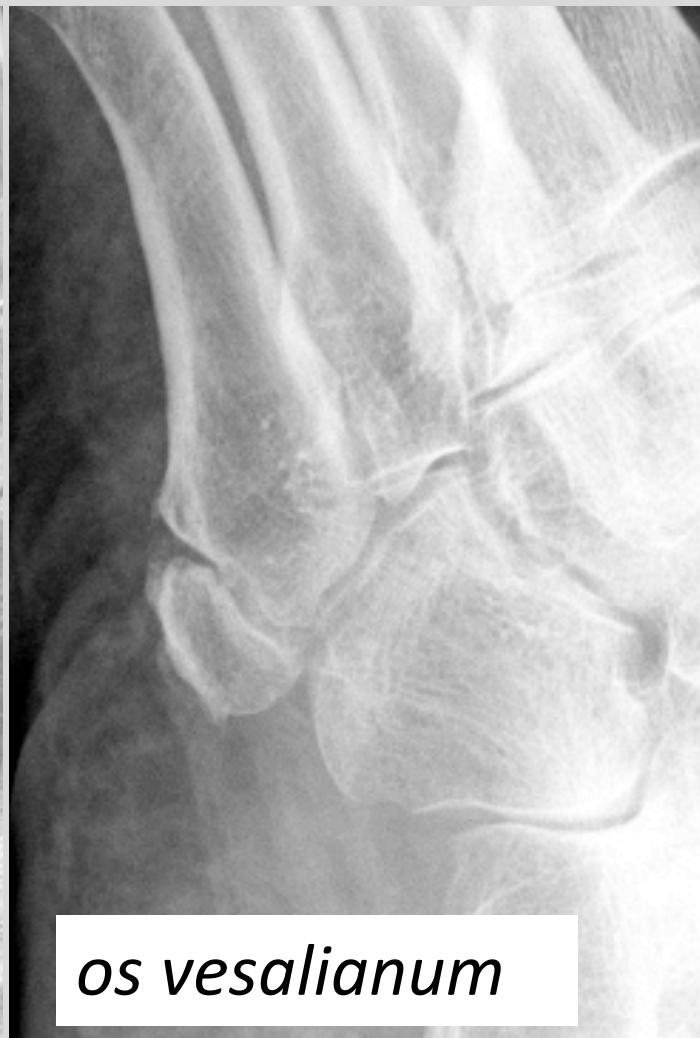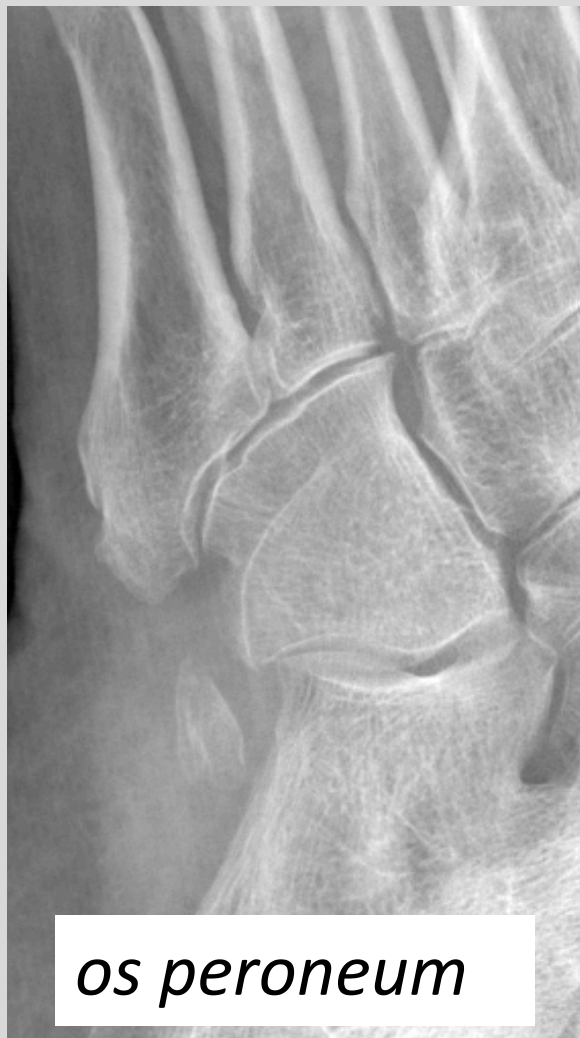DEX





Os peroneum





Os acetabuli

