

A grayscale MRI scan of a knee joint, showing the femur, tibia, and surrounding soft tissue structures. The image is centered and serves as the background for the text.

# MRI Knä

Pawel Szaro, med dr  
Avdelningen för radiologi,  
Sahlgrenska Universitetssjukhuset, Mölndal  
[pawel.szaro@gu.se](mailto:pawel.szaro@gu.se)

# Utlåtande

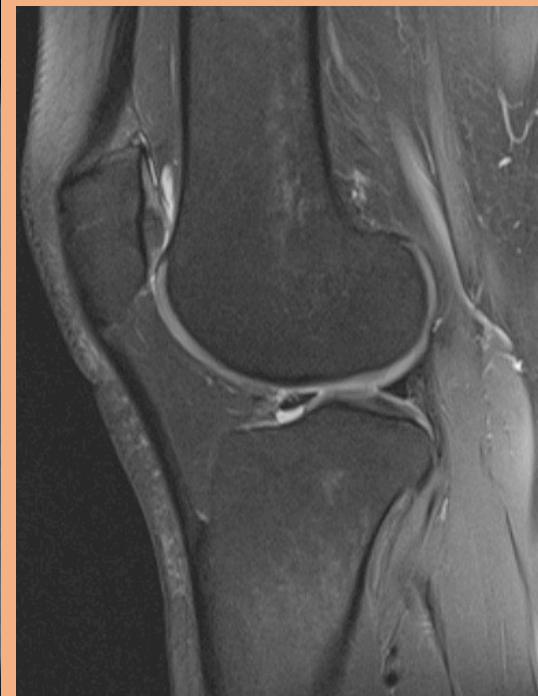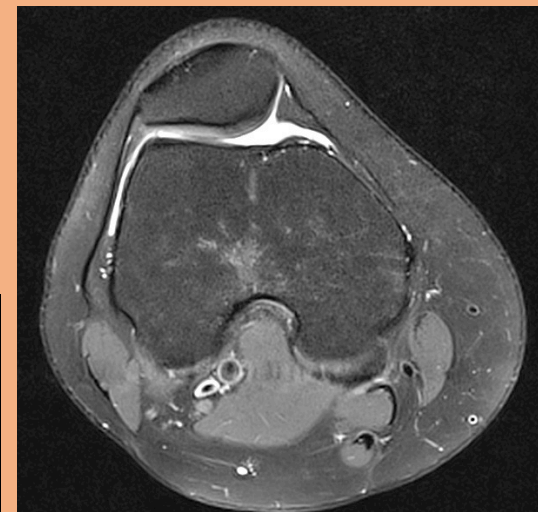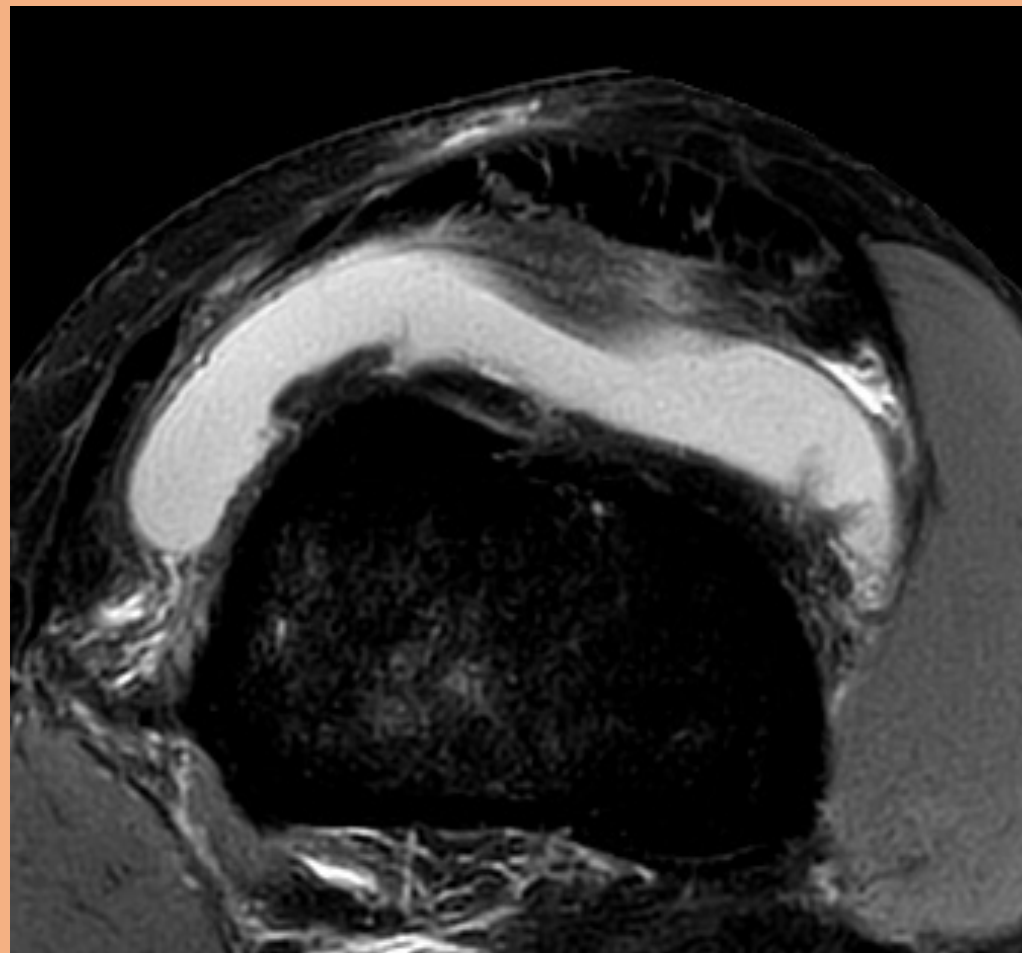
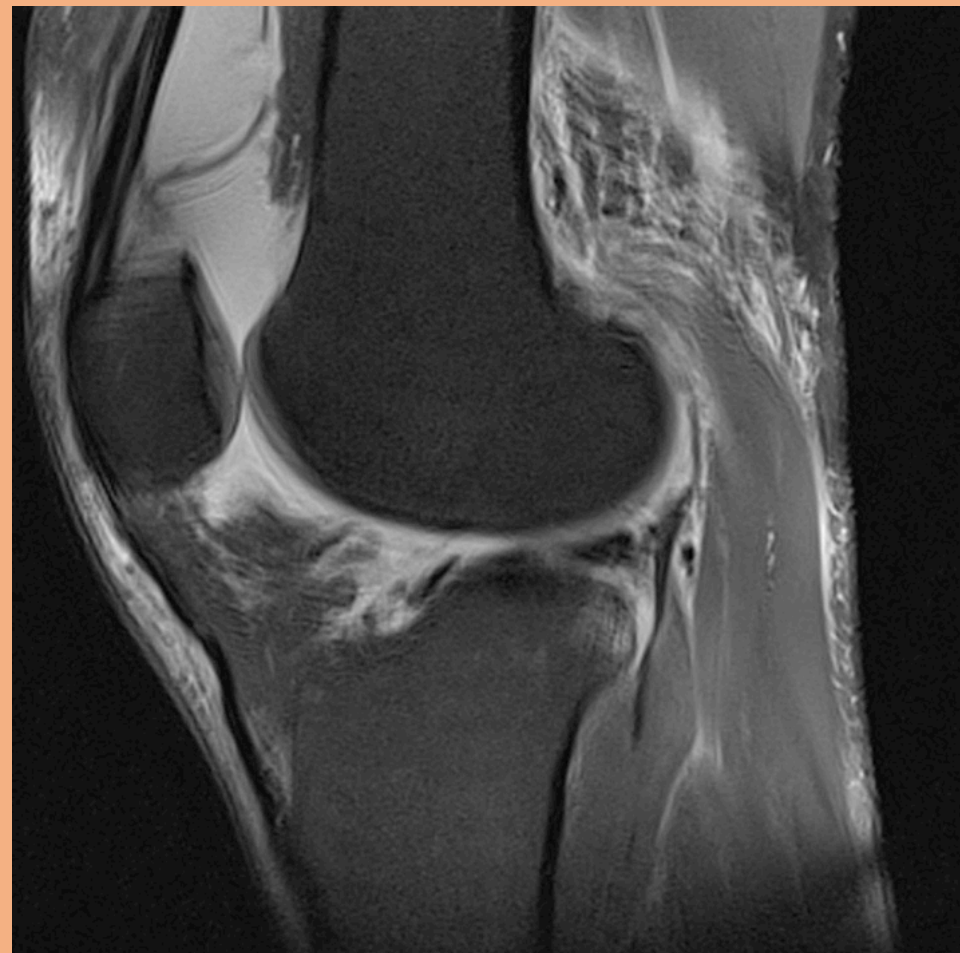## Standardsvar MR knäled

Jämförelse med föregående undersökning...

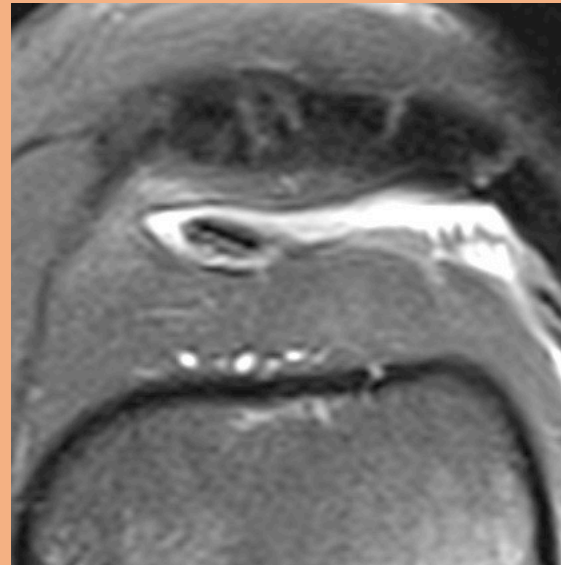
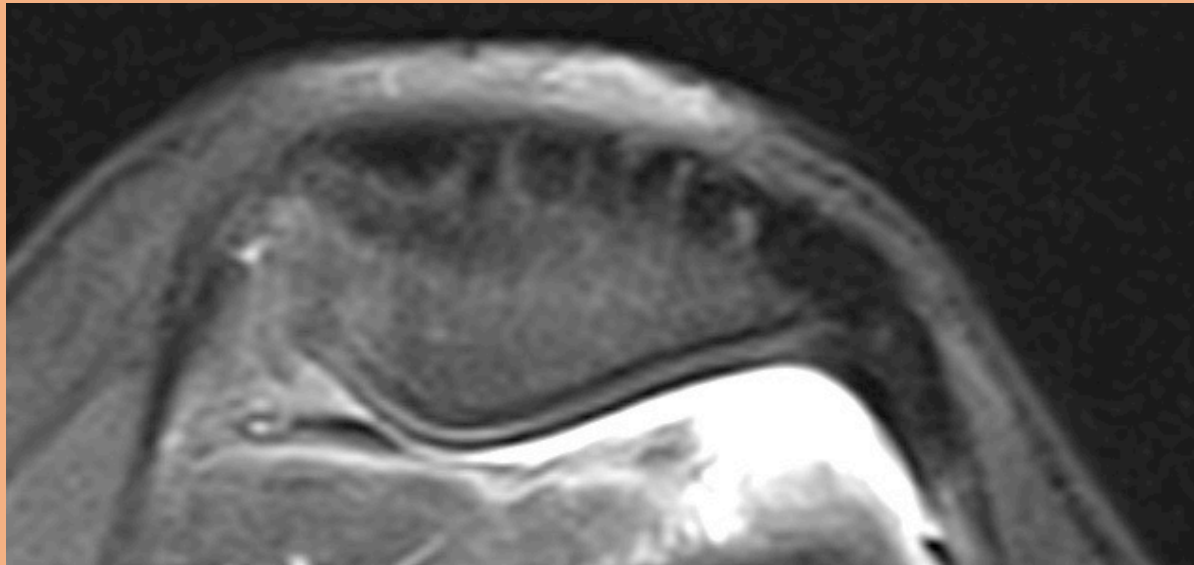
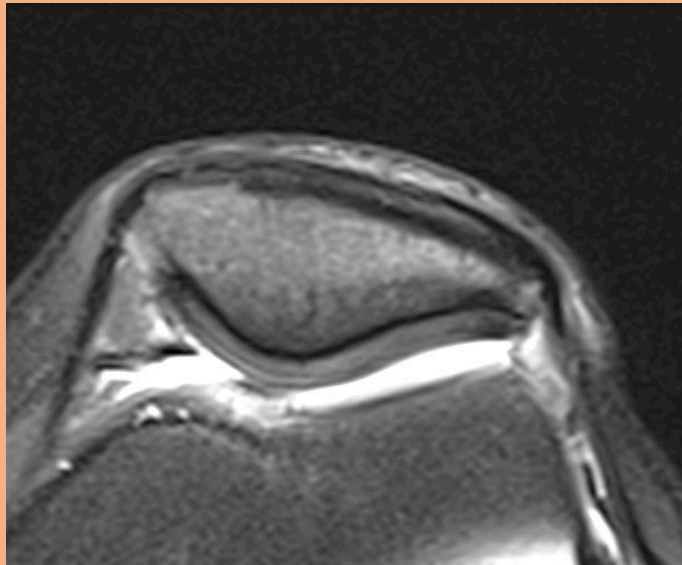
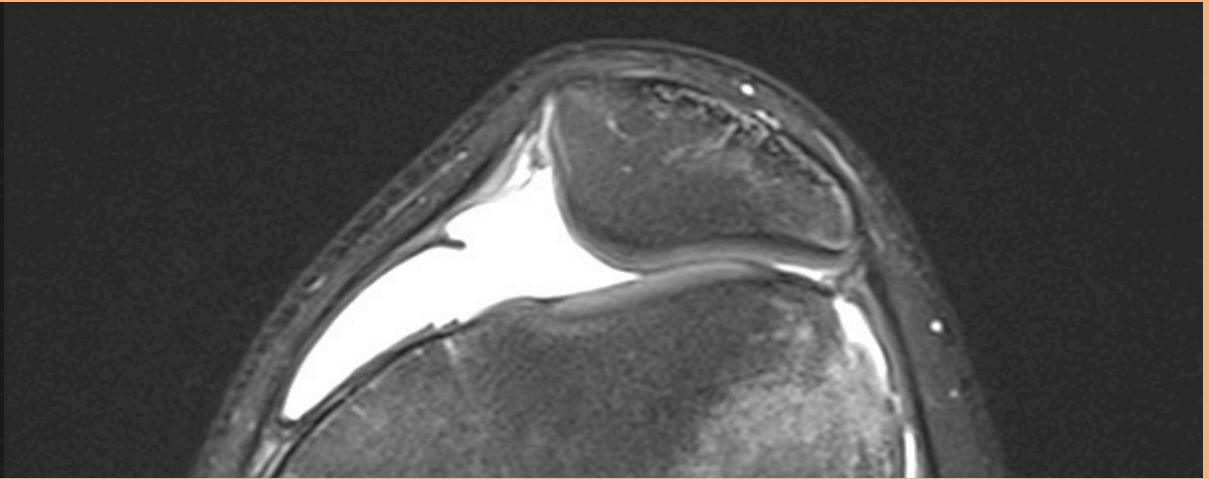
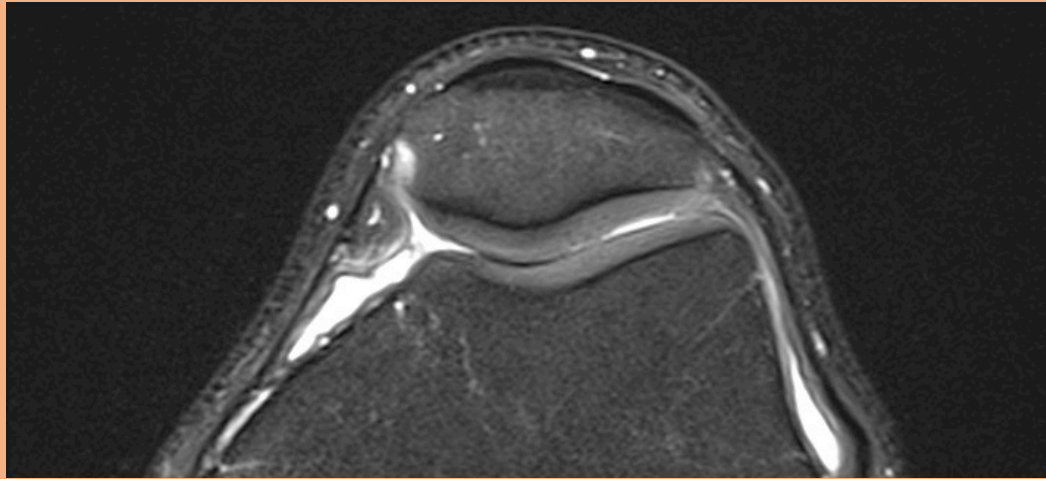
1. Skelett och läge: Inget benmärgsödem. Ingen dislokation.	1
2. Ledvätska, mjukdelar och fettstrukturer: Ingen utgjutning eller Bakercysta.	
3. Ledbrosk: Normalt	
4. Främre korsband: Intakt	2
5. Bakre korsband: Intakt	
6. Mediala menisken:	3
7. Lateral menisken:	
8. Kollateralligament medialt:	1
9. Kollateralligament lateralt:	
10. Posterolaterala strukturer:	
11. Patella och extensorstrukturer: Intakta extensorsenor. Normalt läge av patella. Retinakulum intakt.	

Slutsats: ...

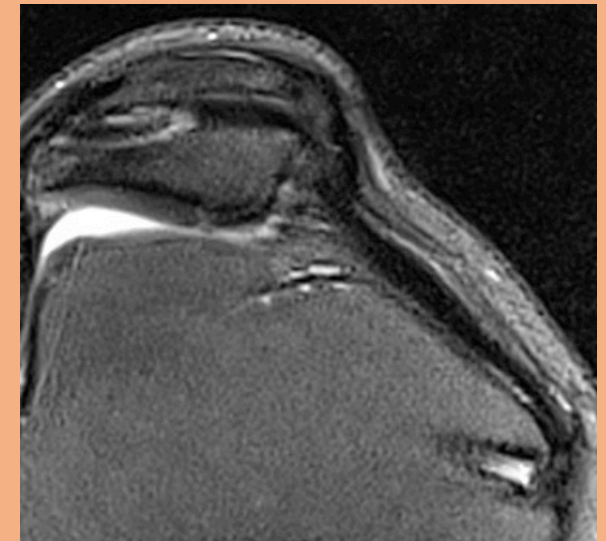
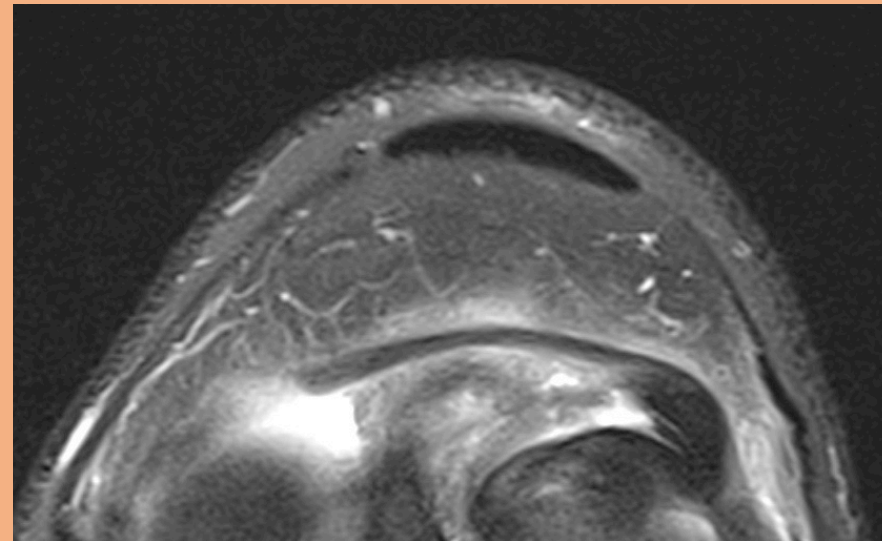
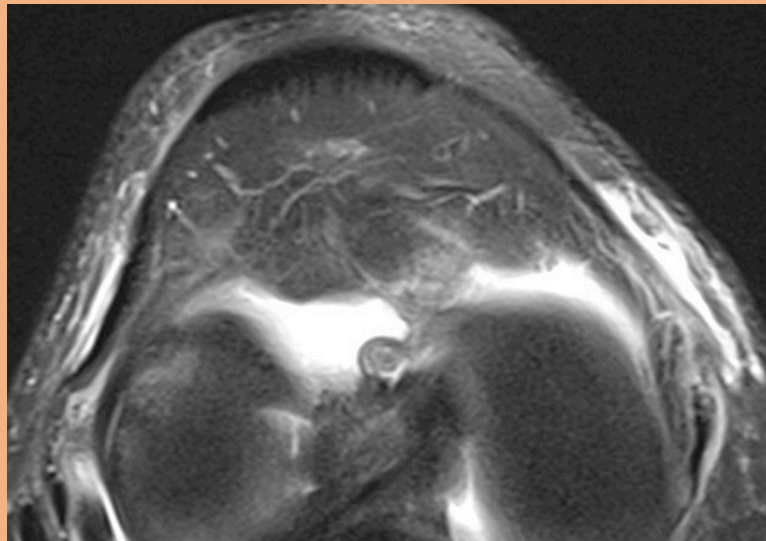
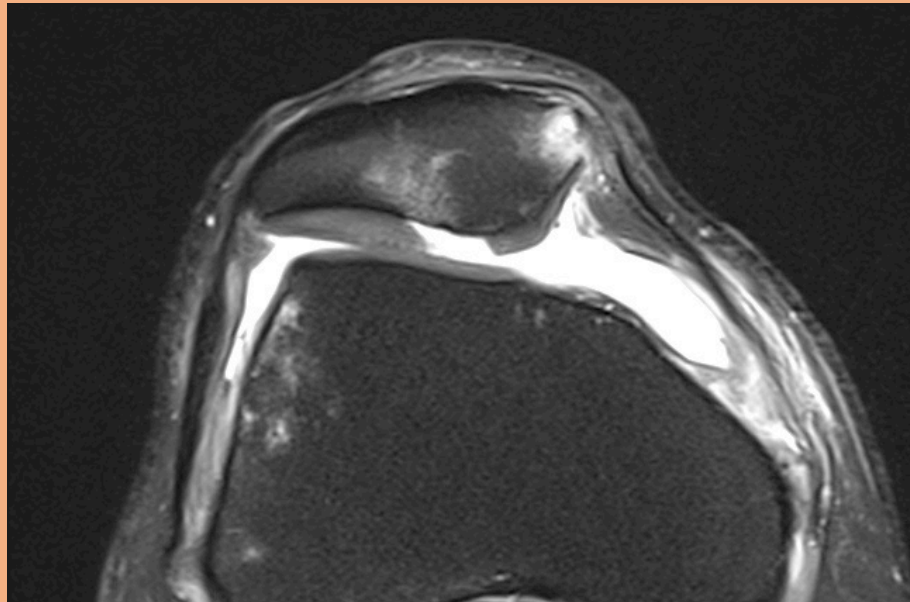
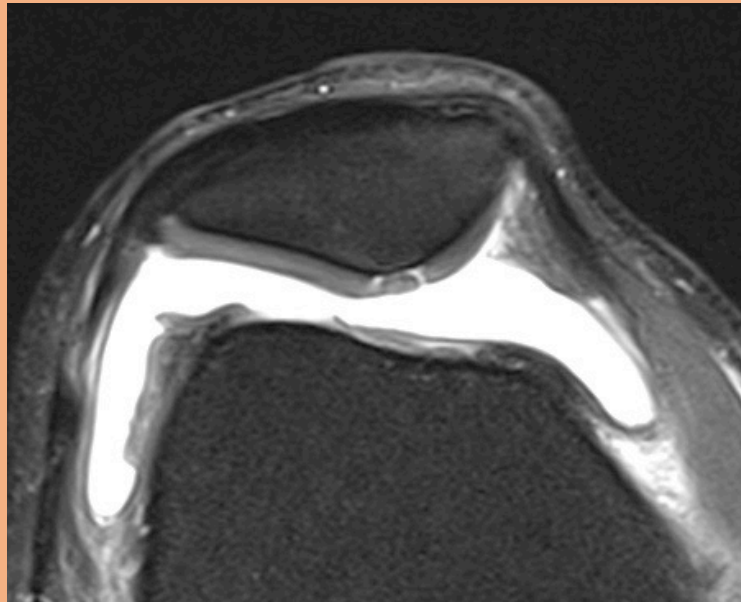
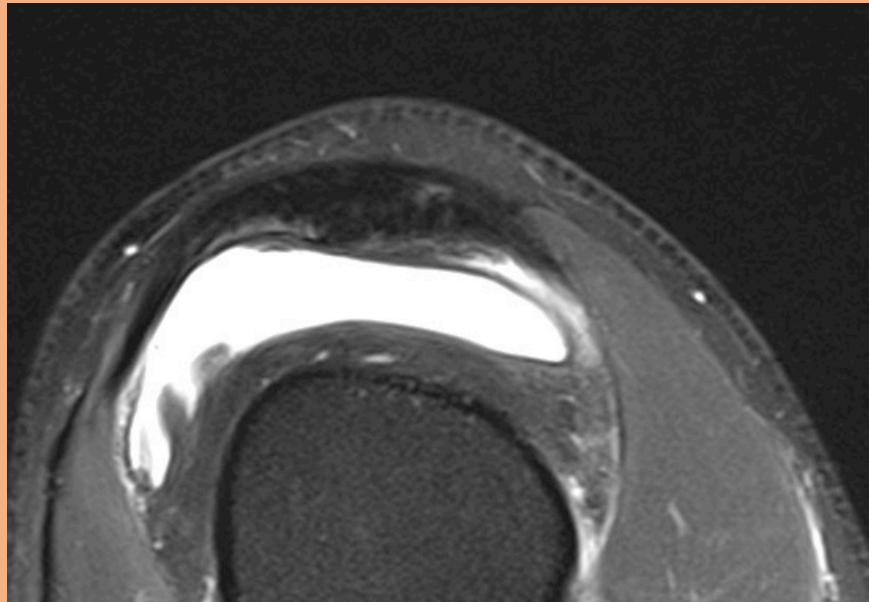
# Utgjutning och synovit



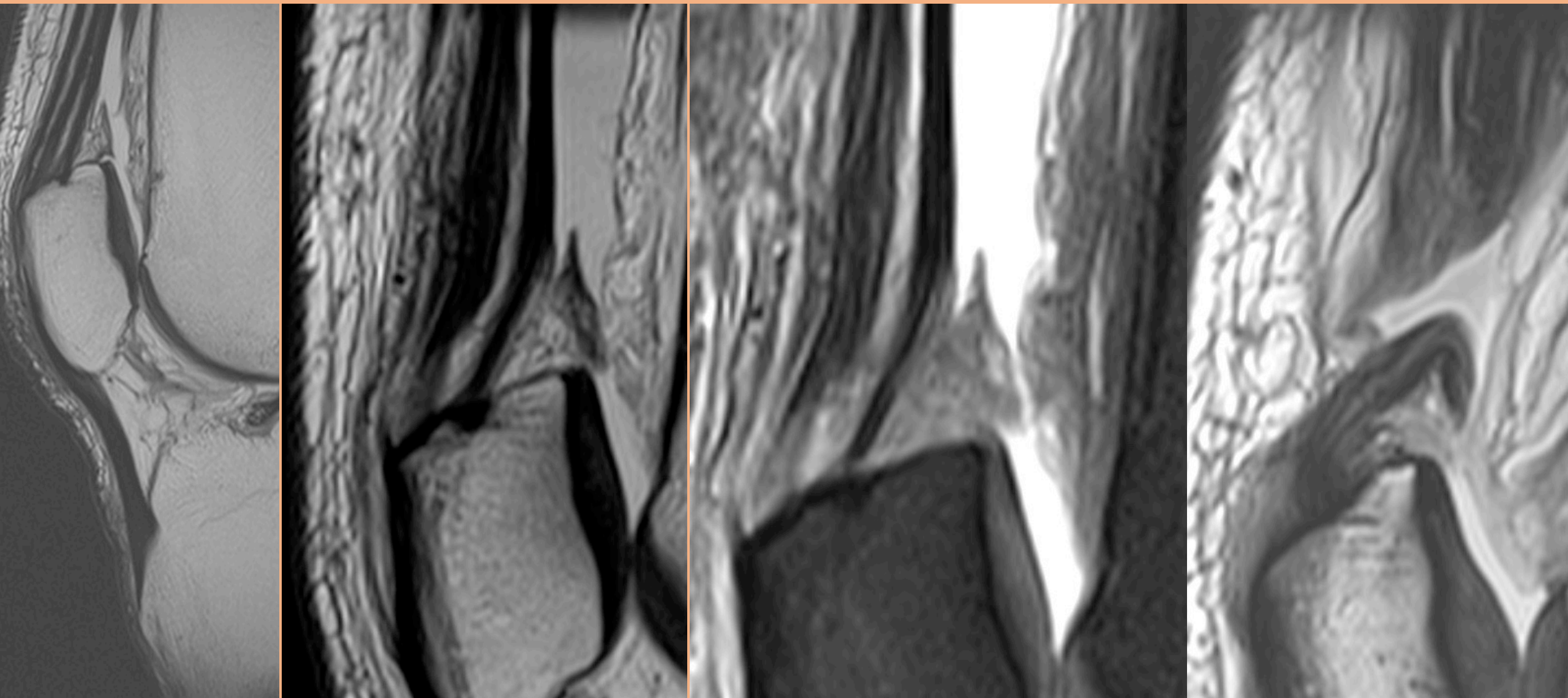
# Patellofemoralled



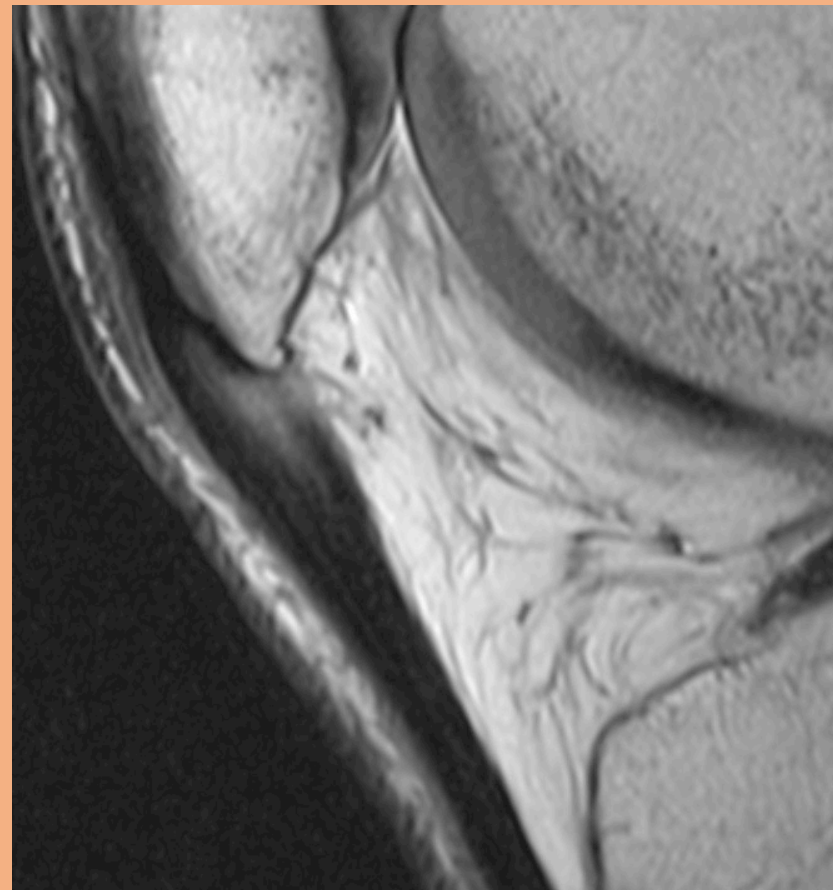
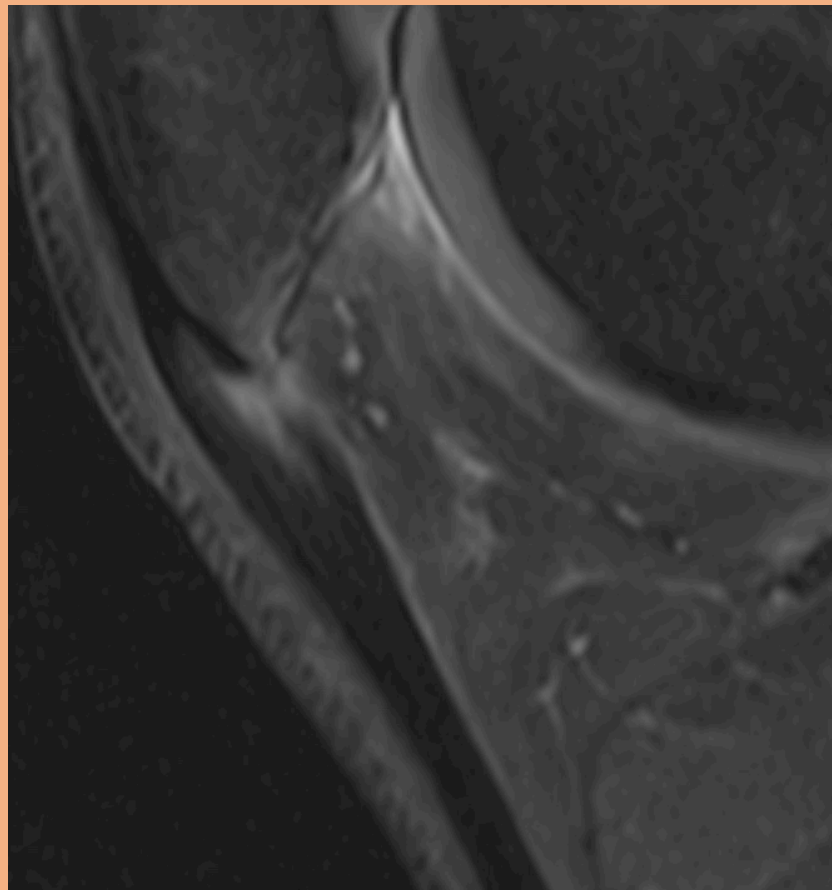
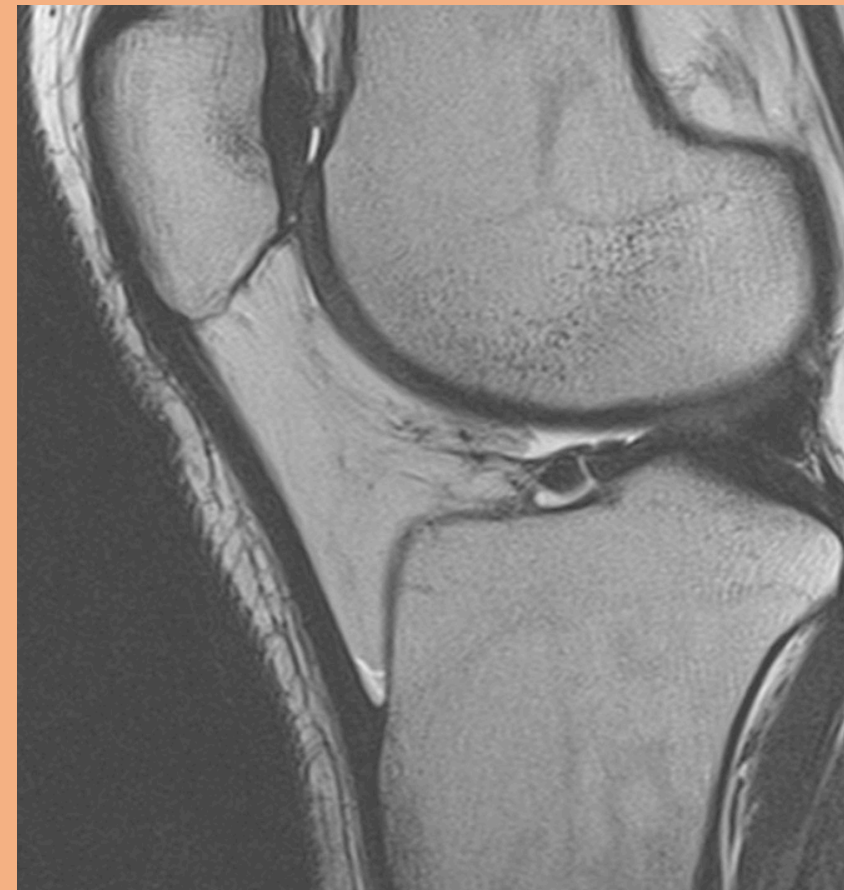# Extensormechanism inkl. MPFL



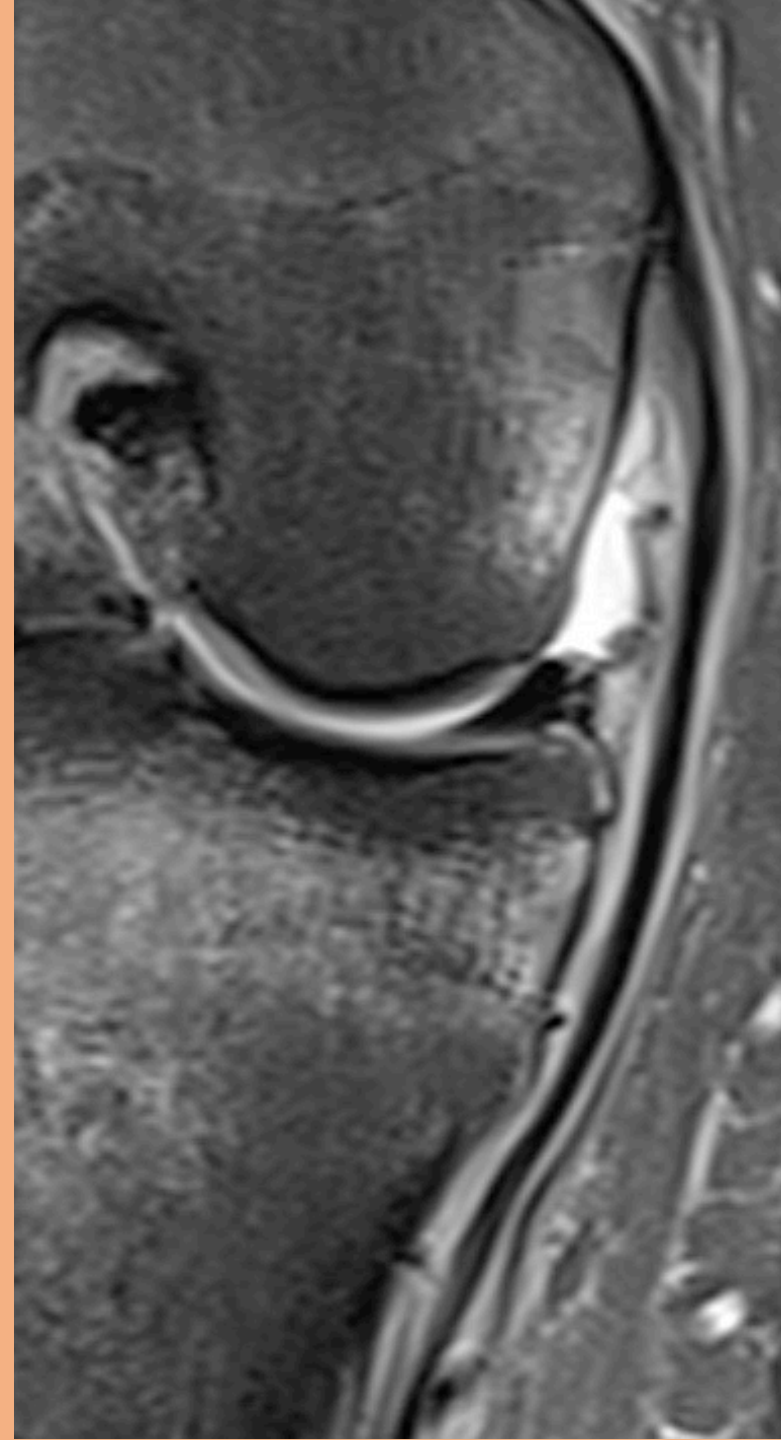
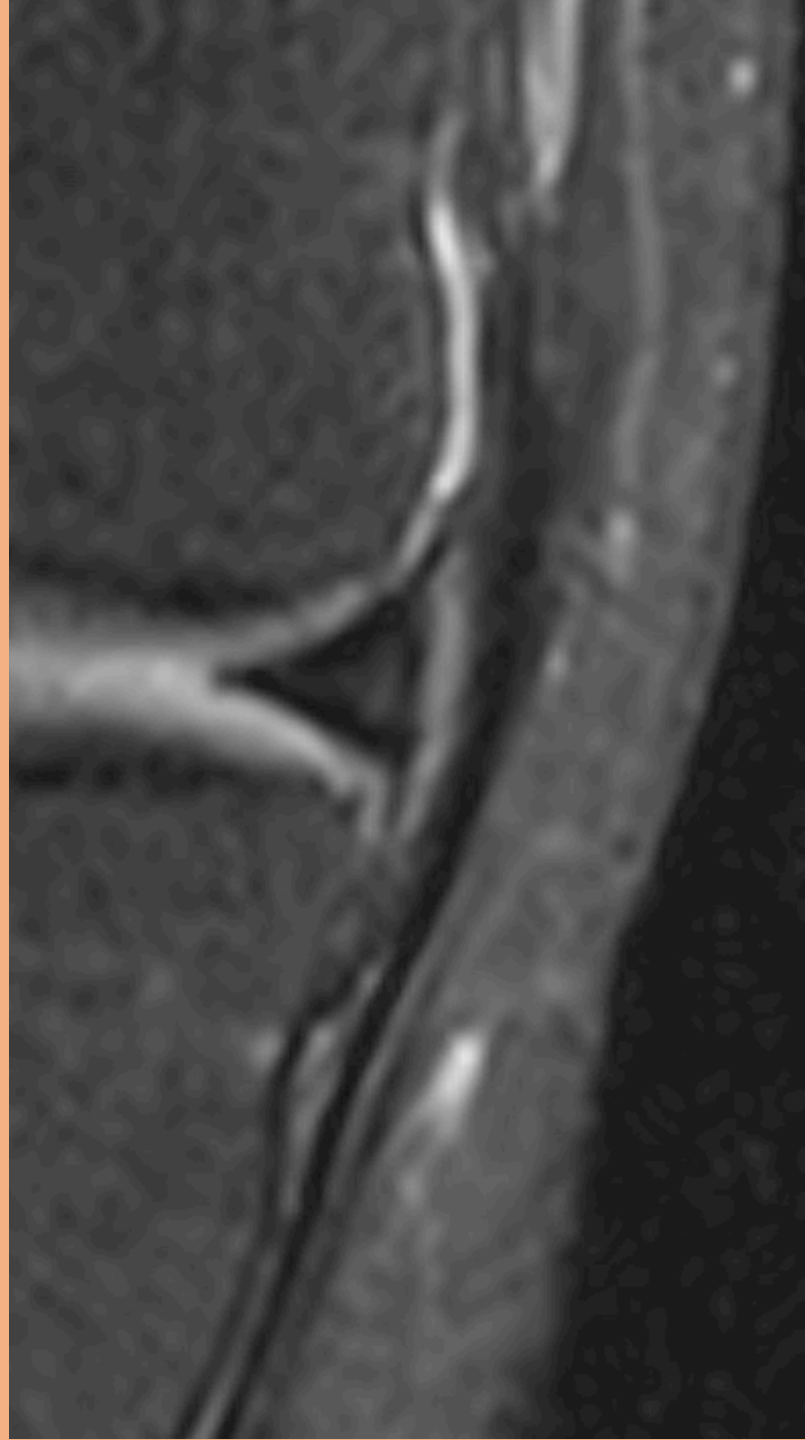
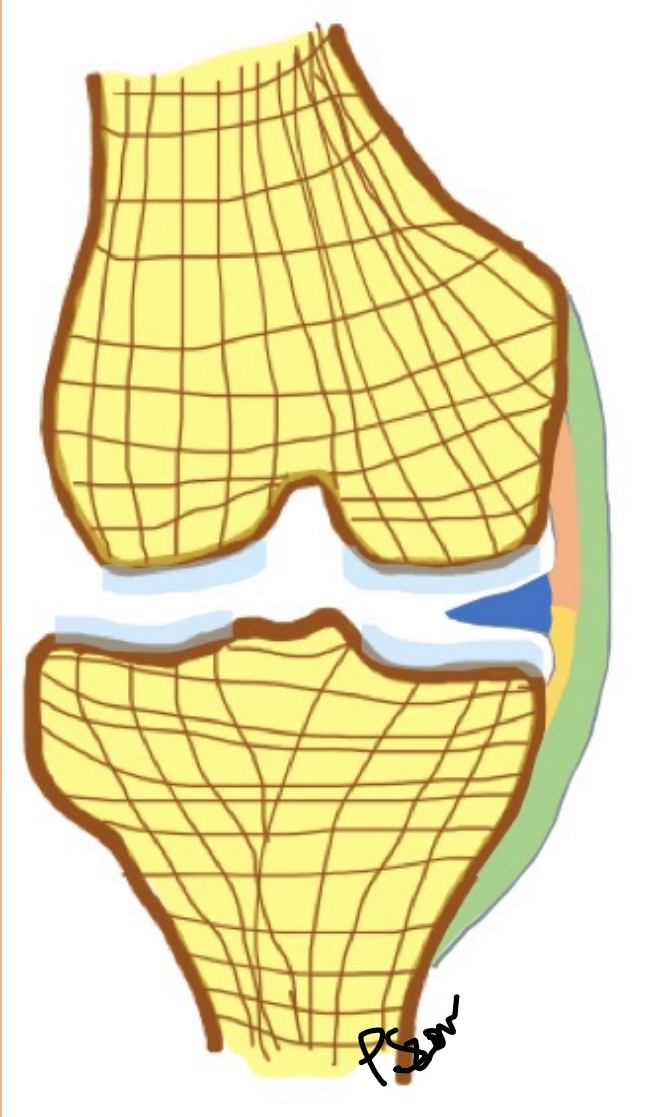
# Quadriceps senan



# Ligamentum patellae

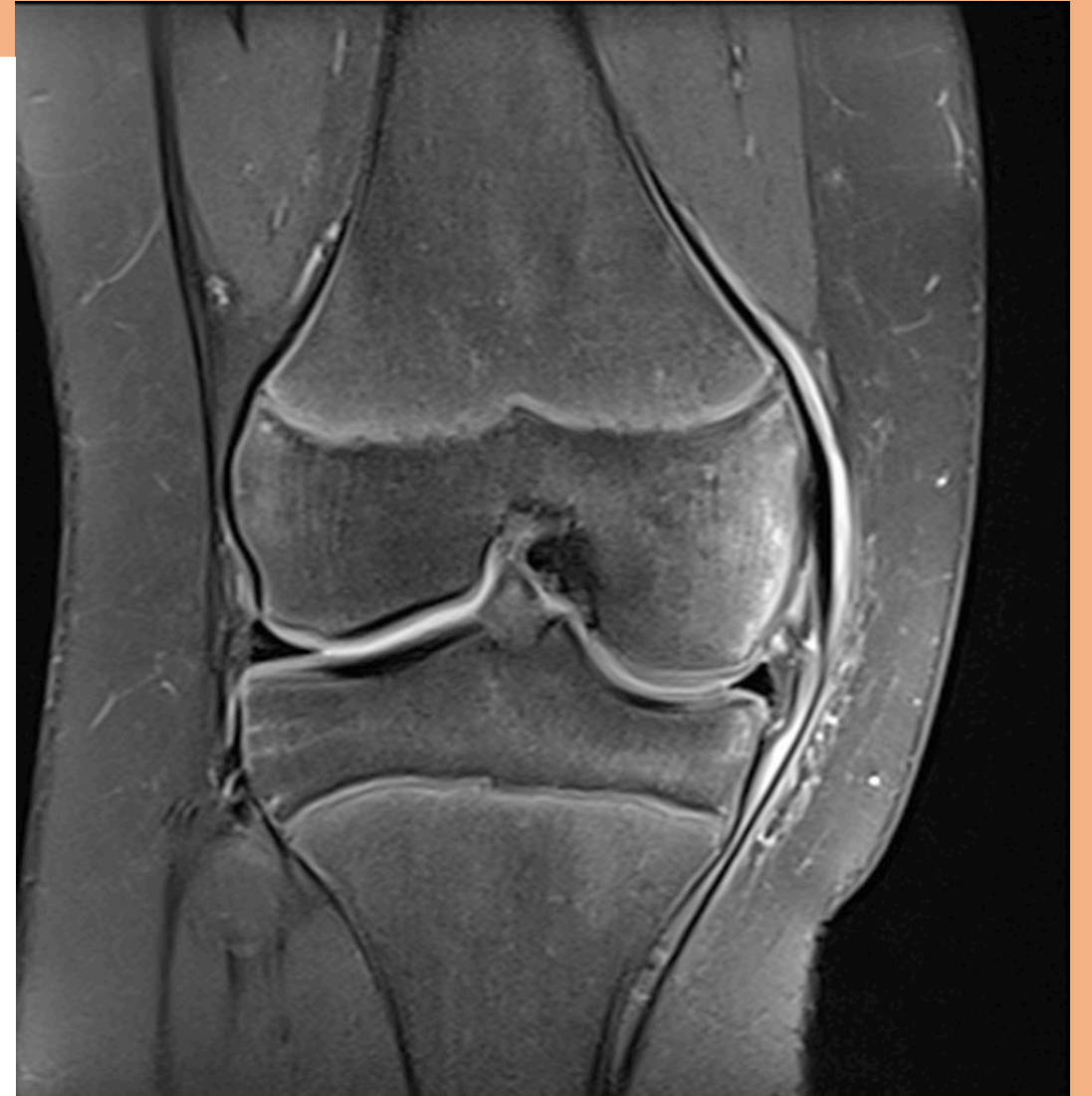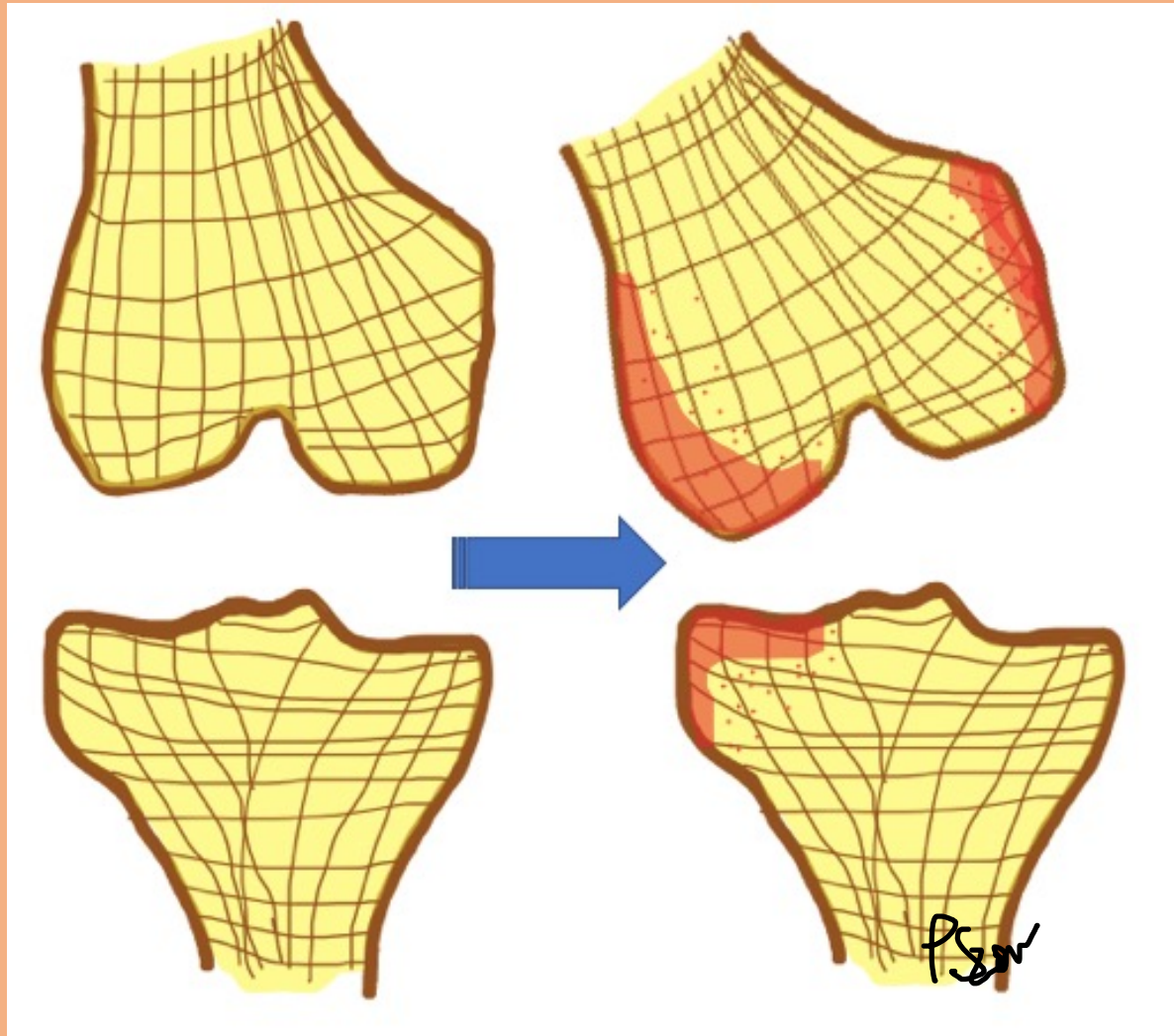


# MCL





# Clip injury

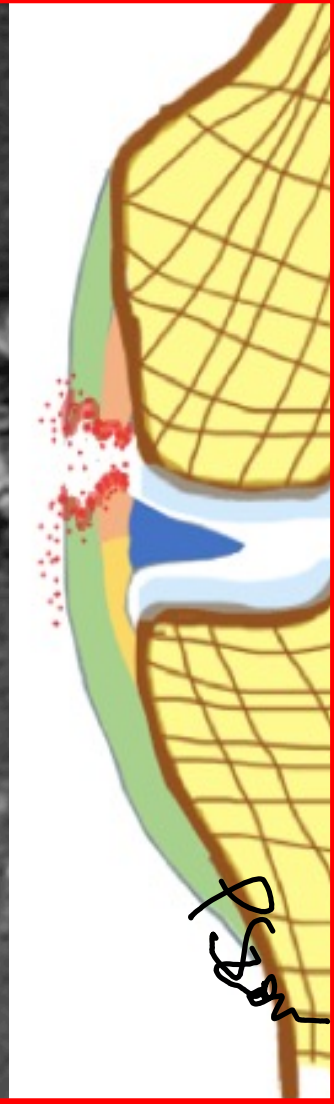
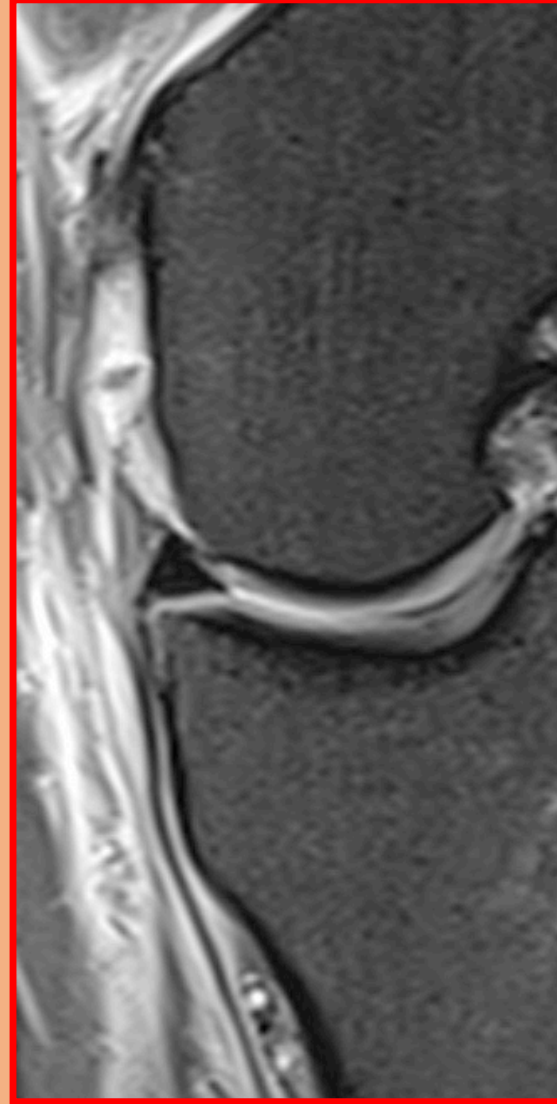
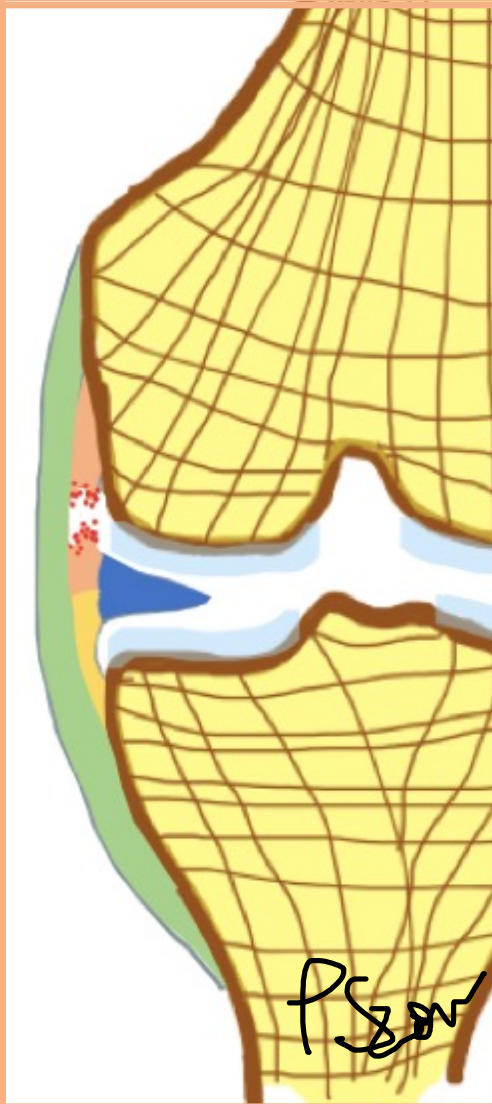
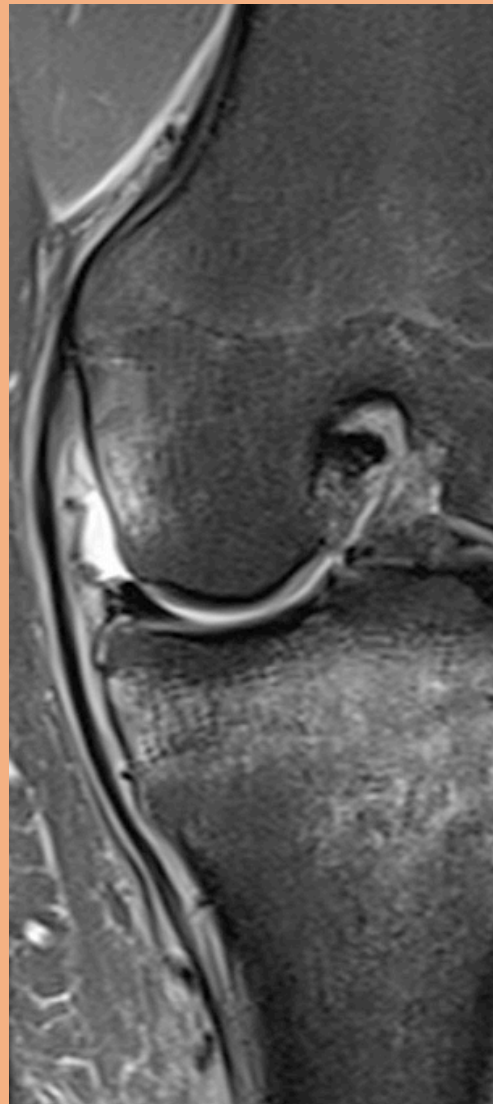
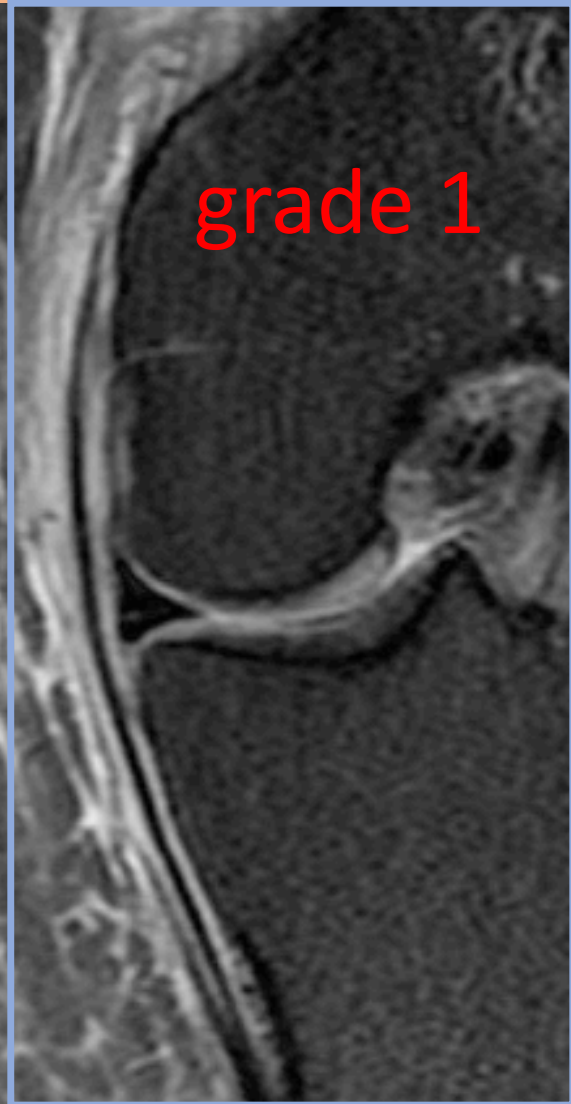

MCL

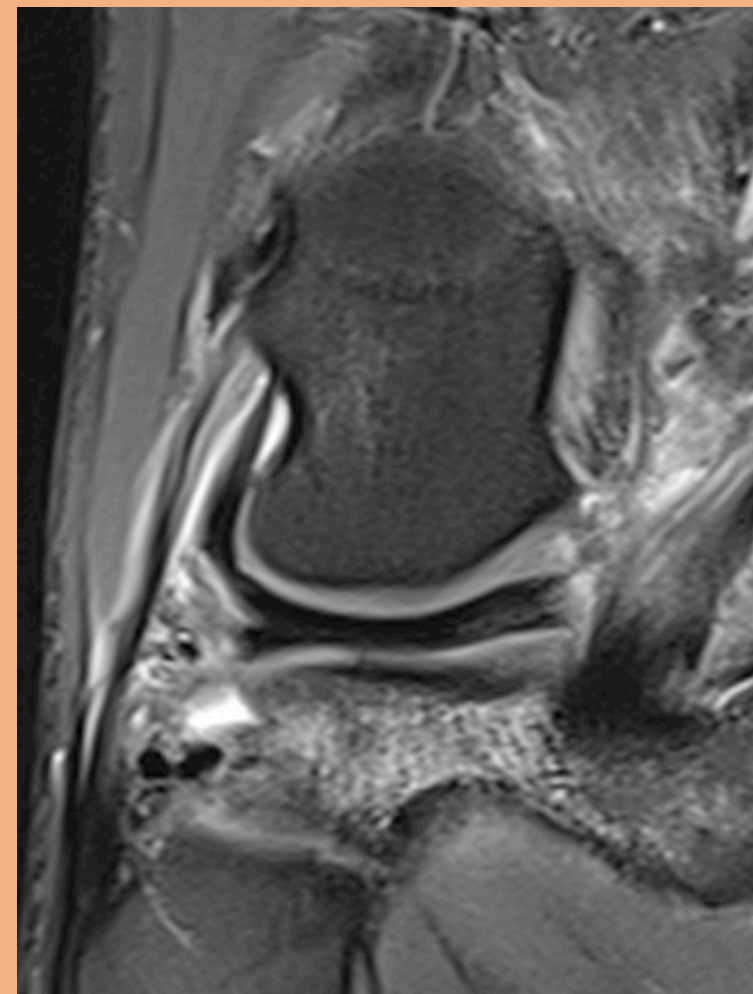
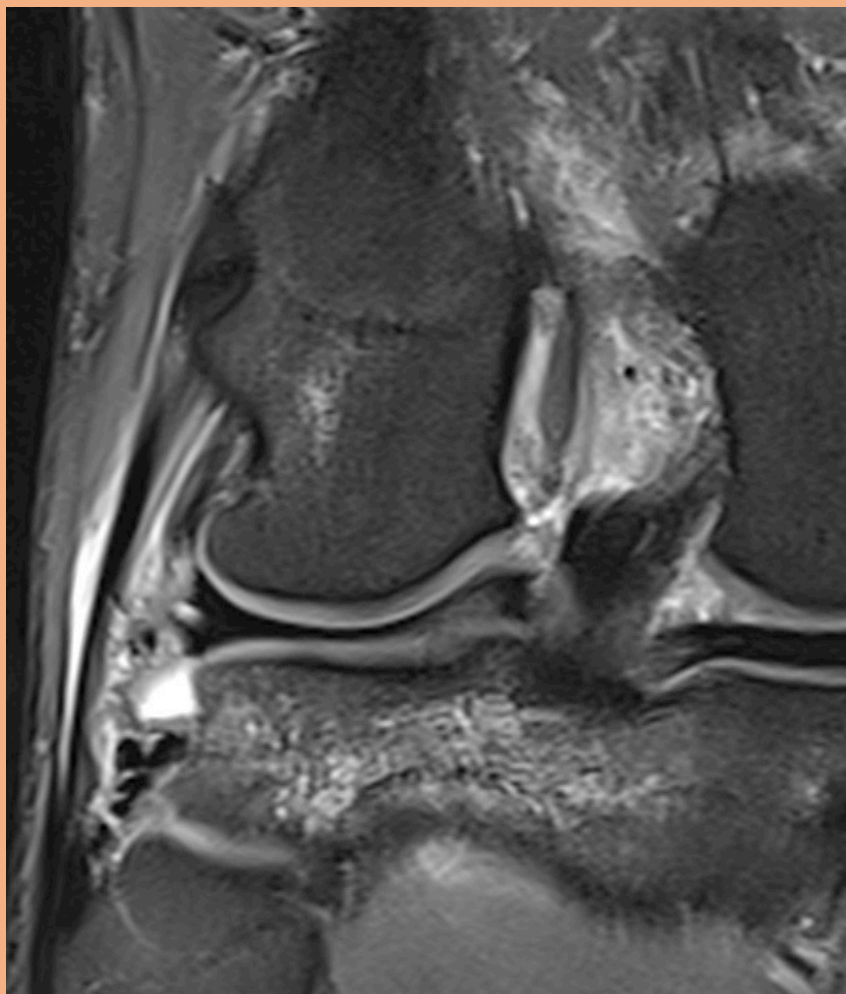
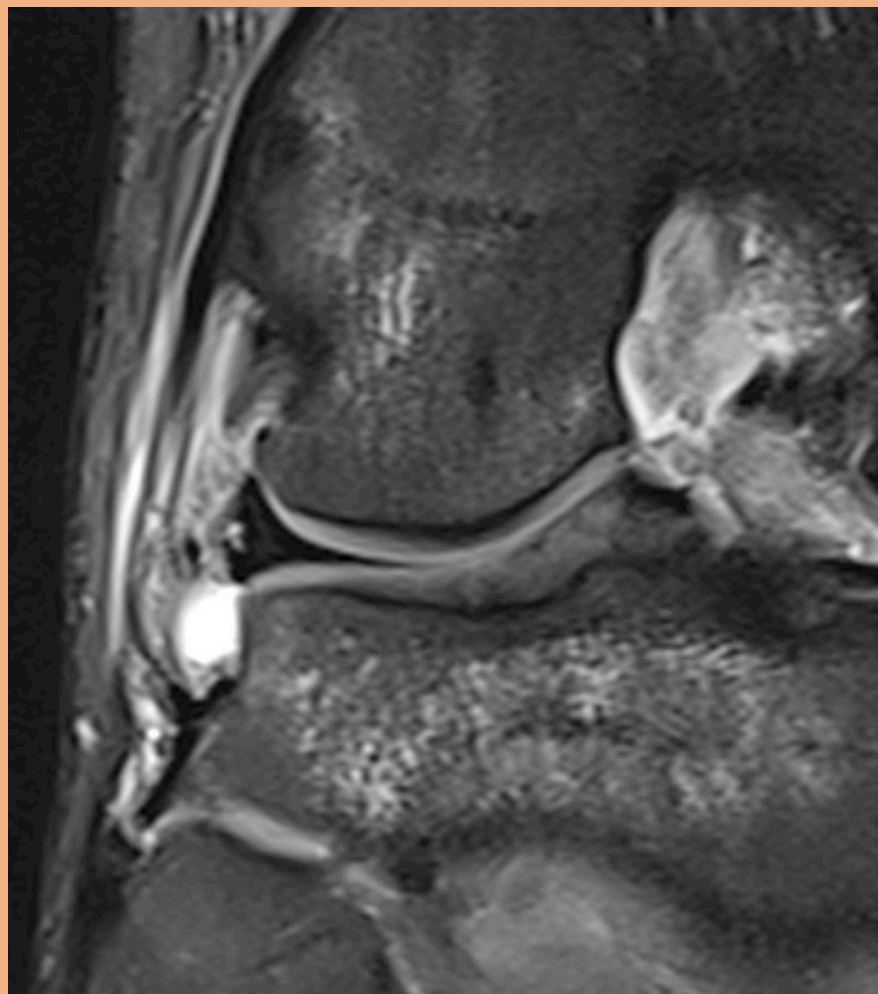
grade 2

grade 3

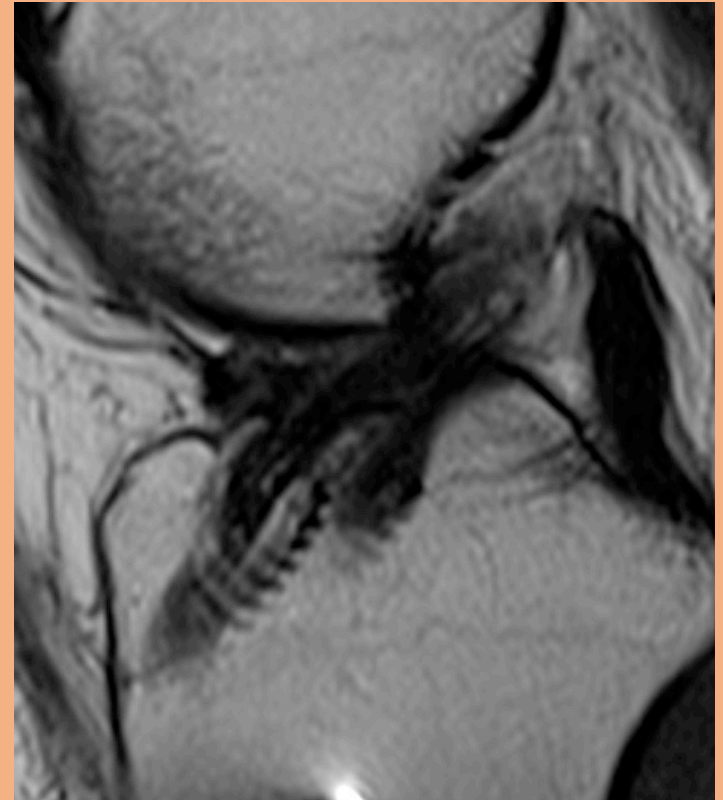
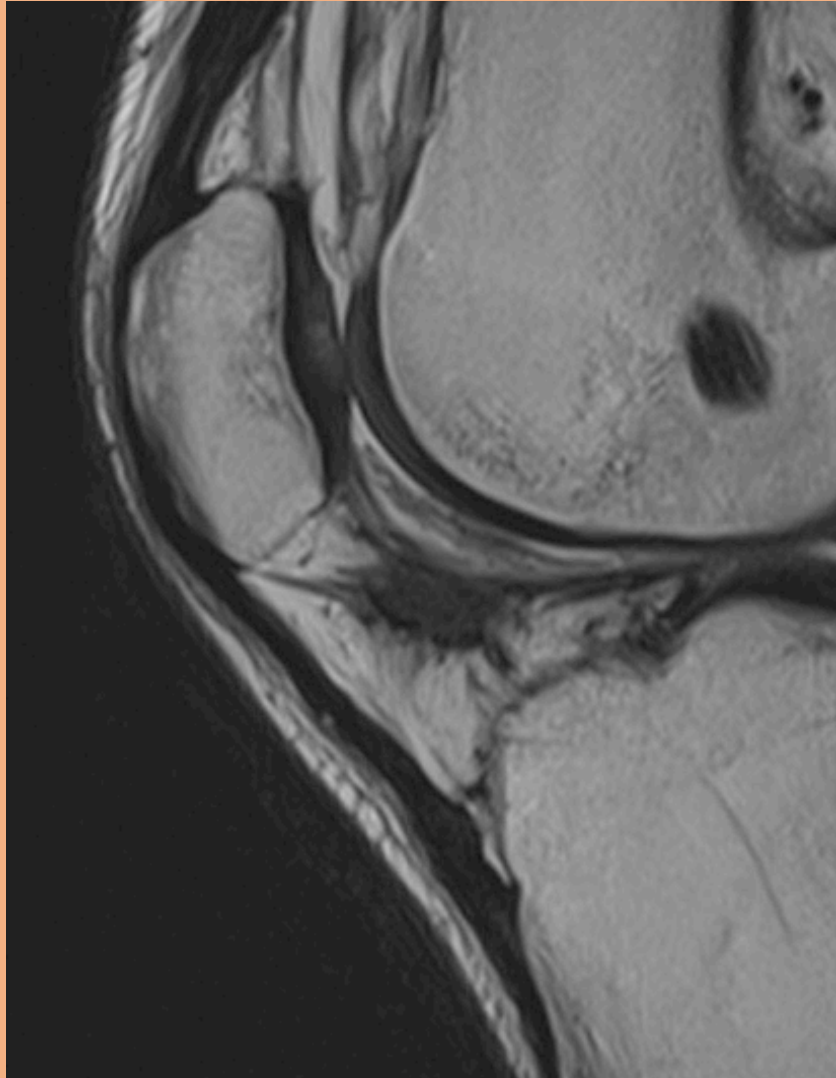
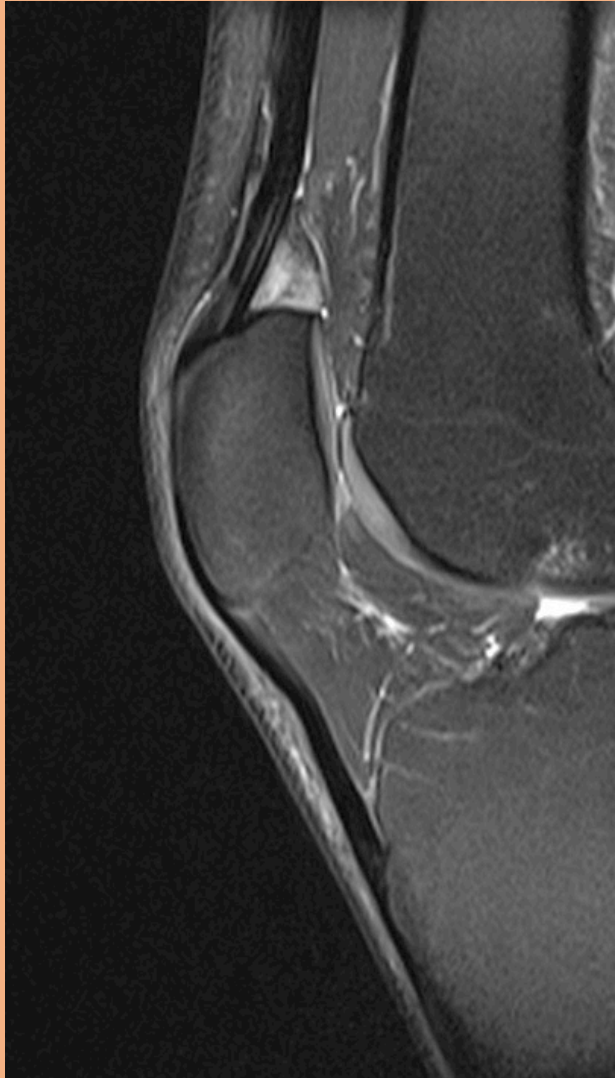
grade 1



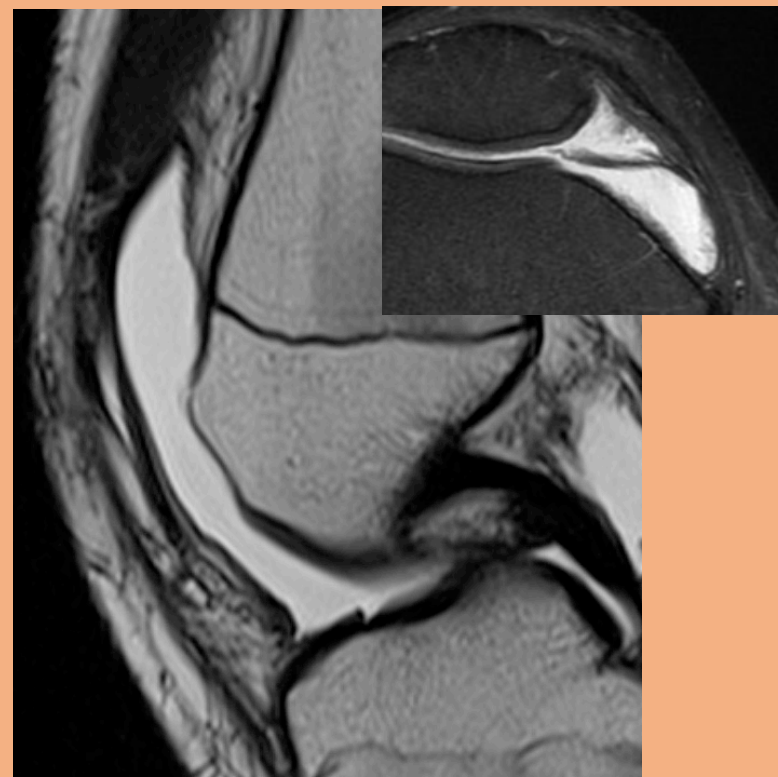
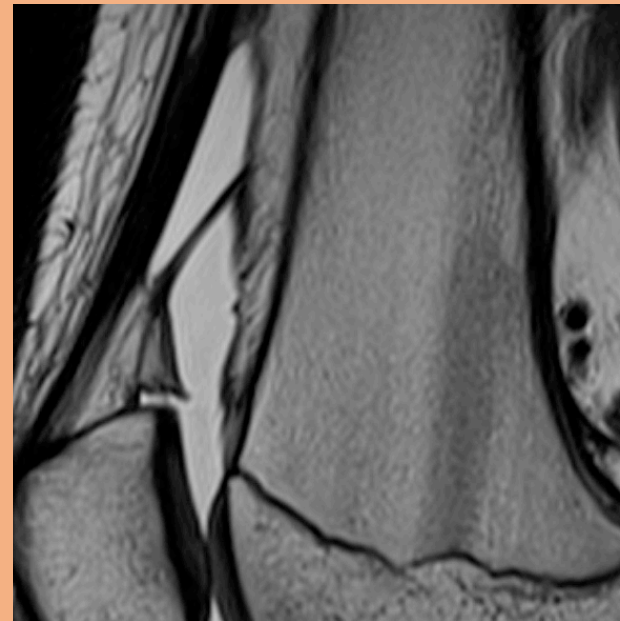
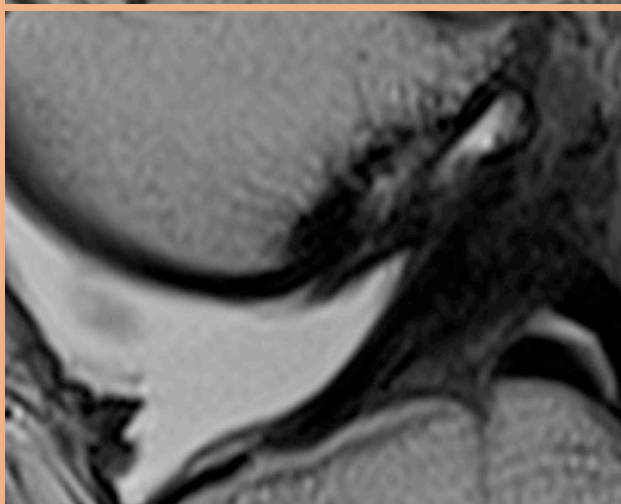
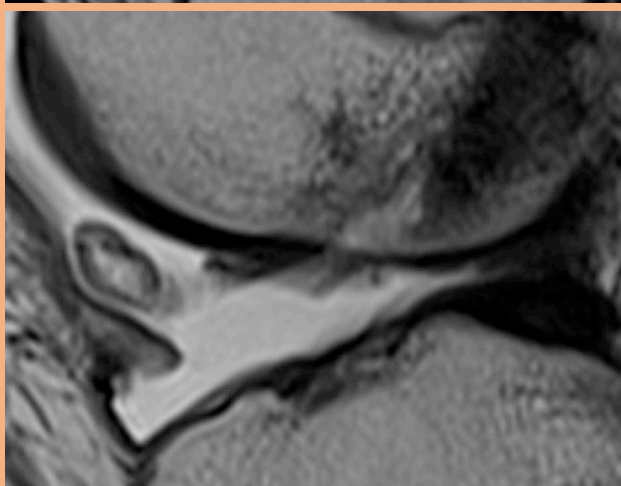
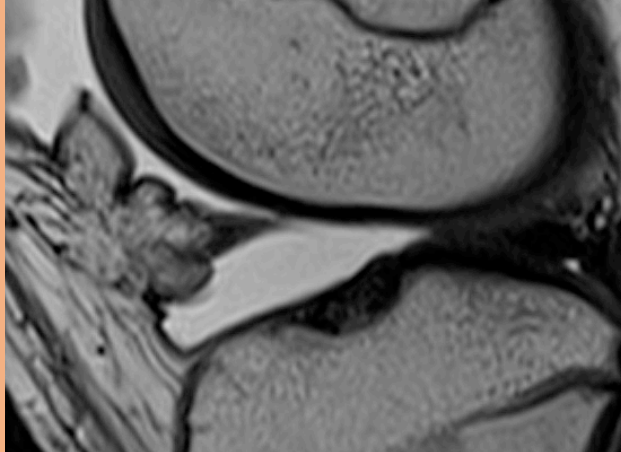
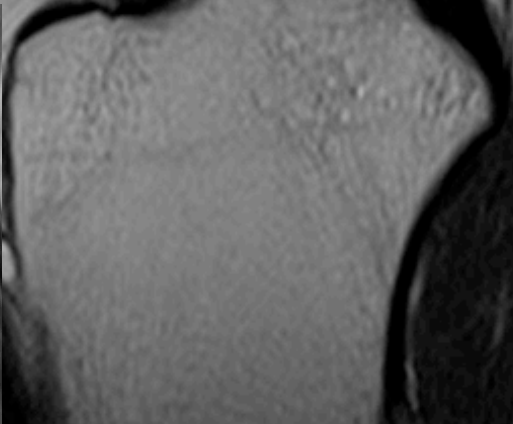
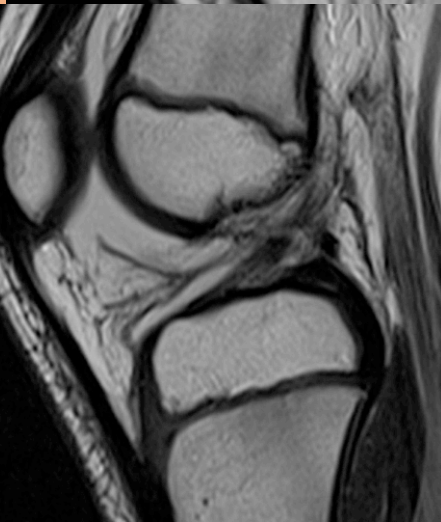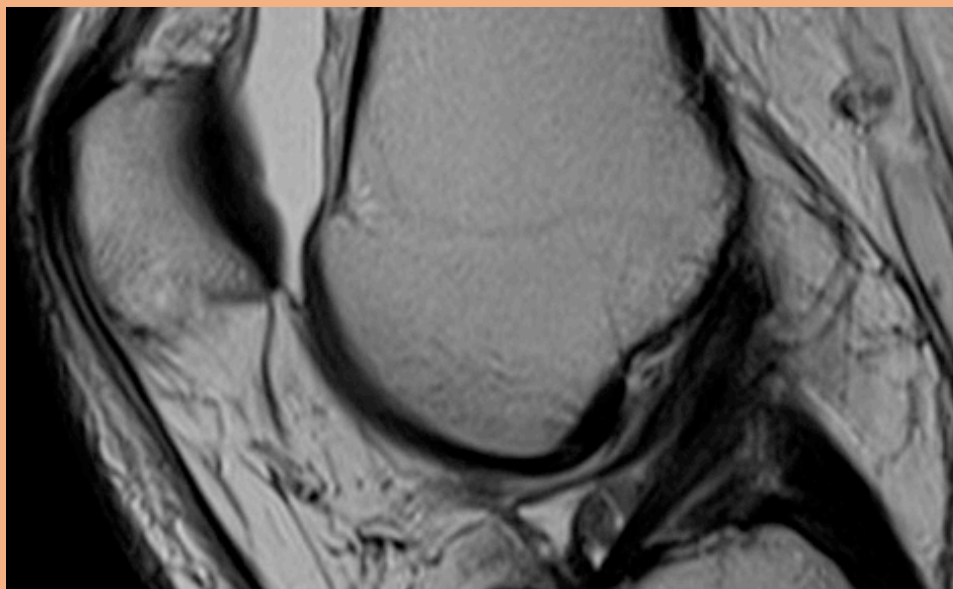
LCL



# Fettkuddar



# Plica

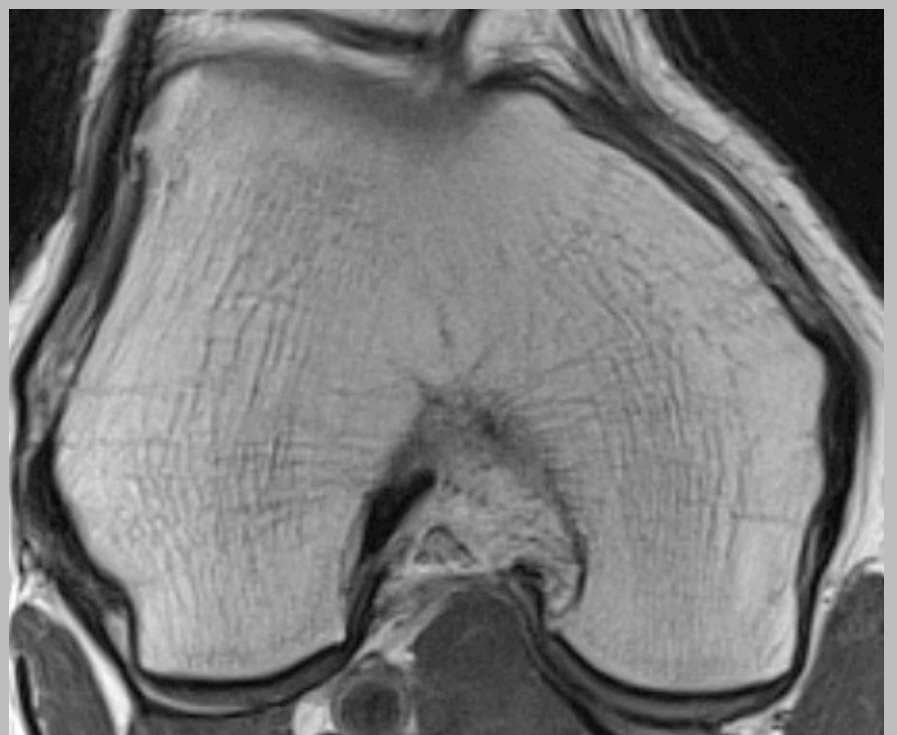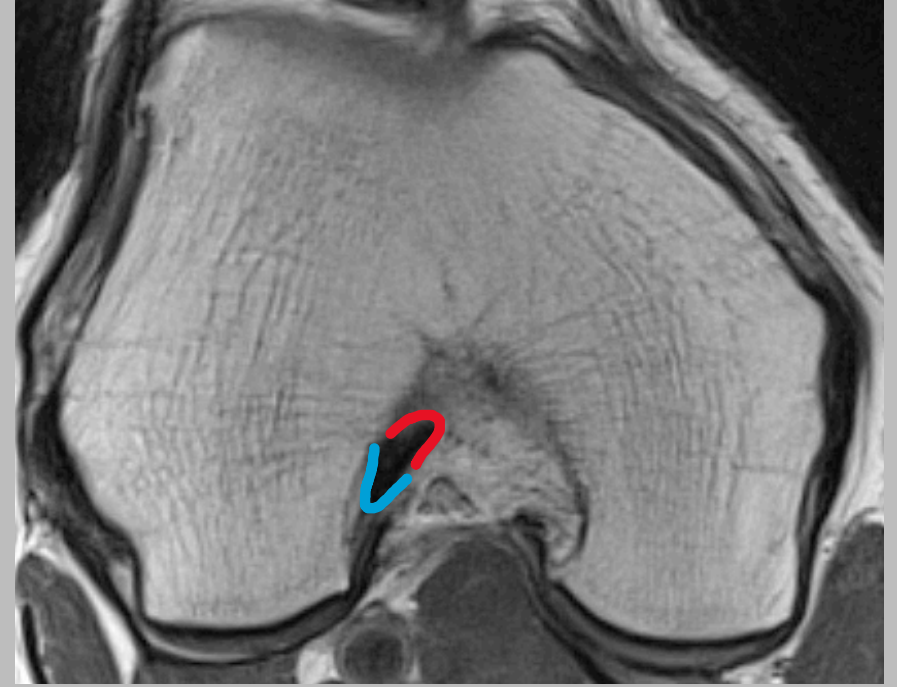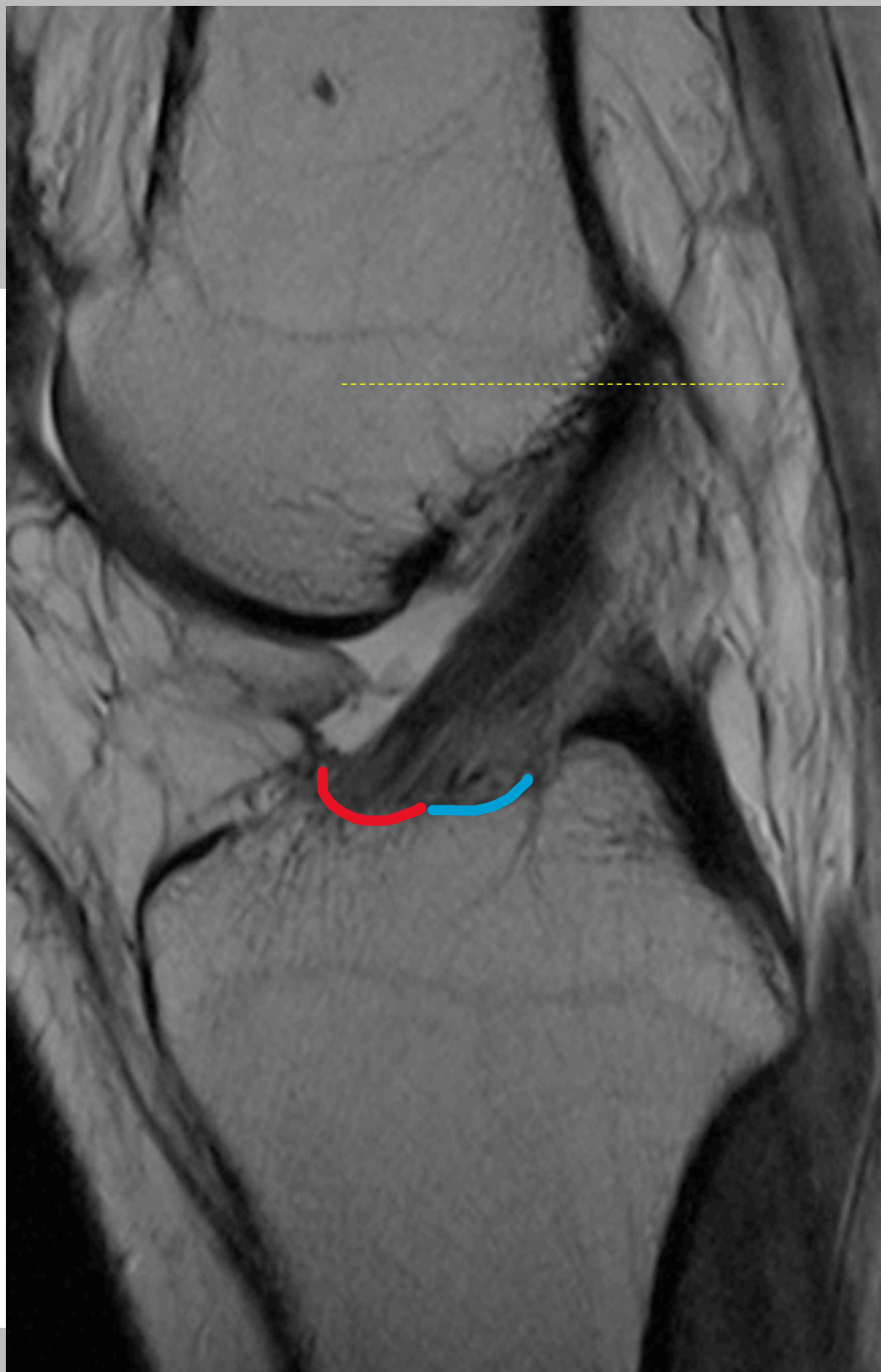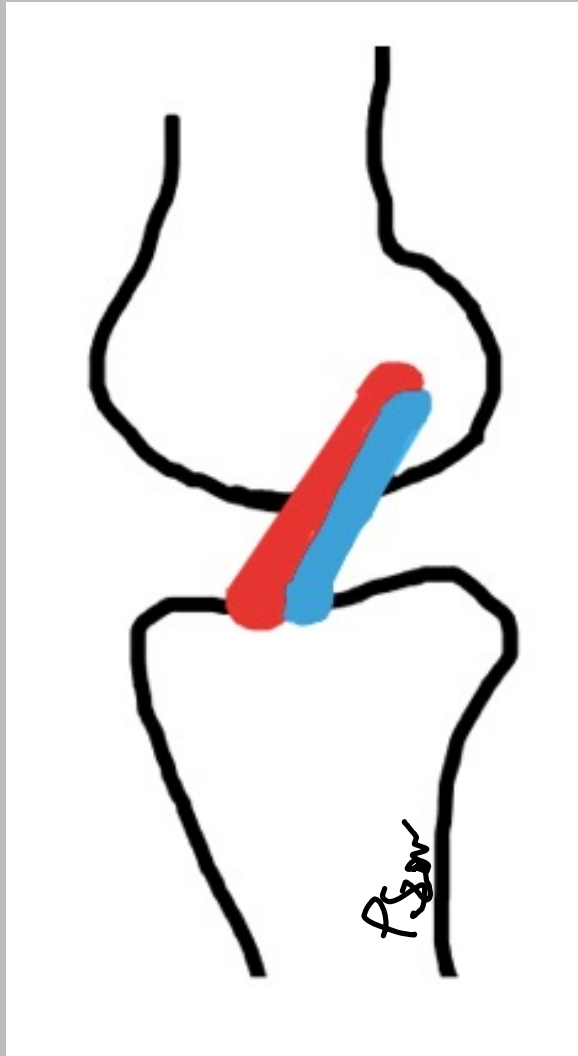


# Korsband

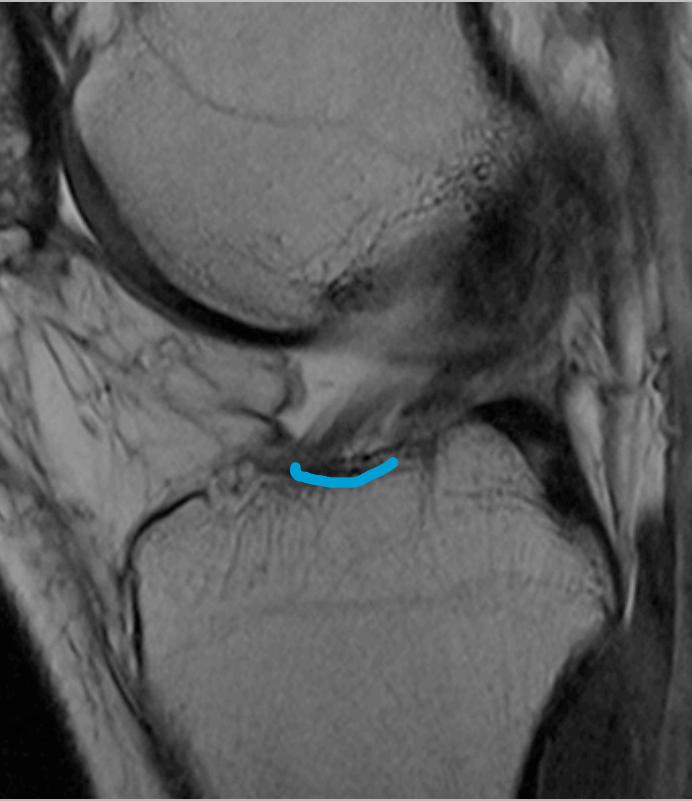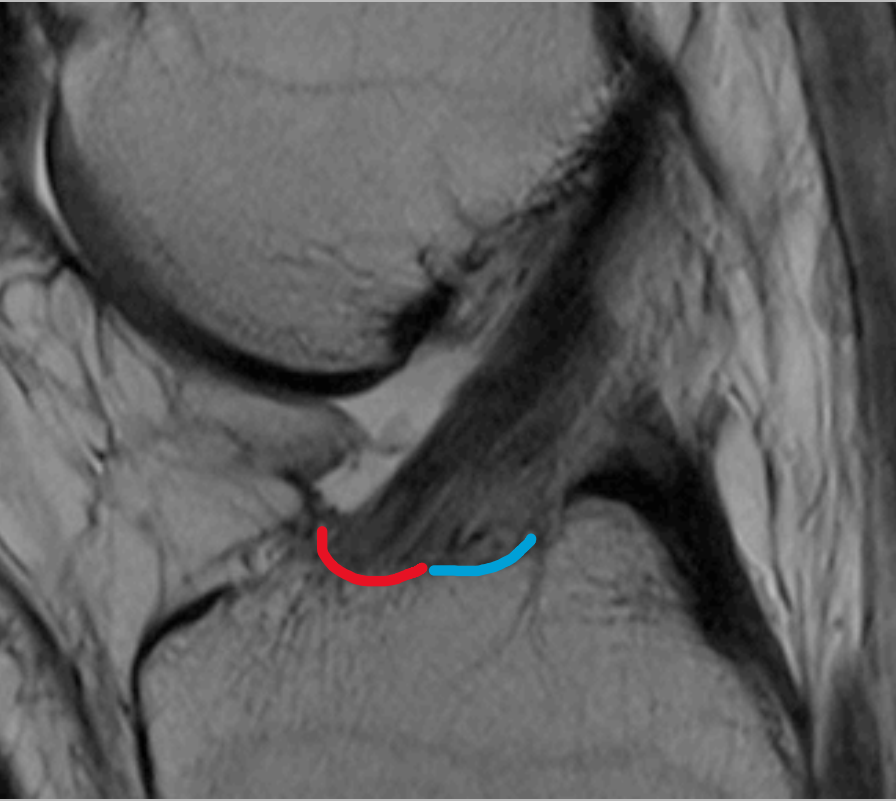
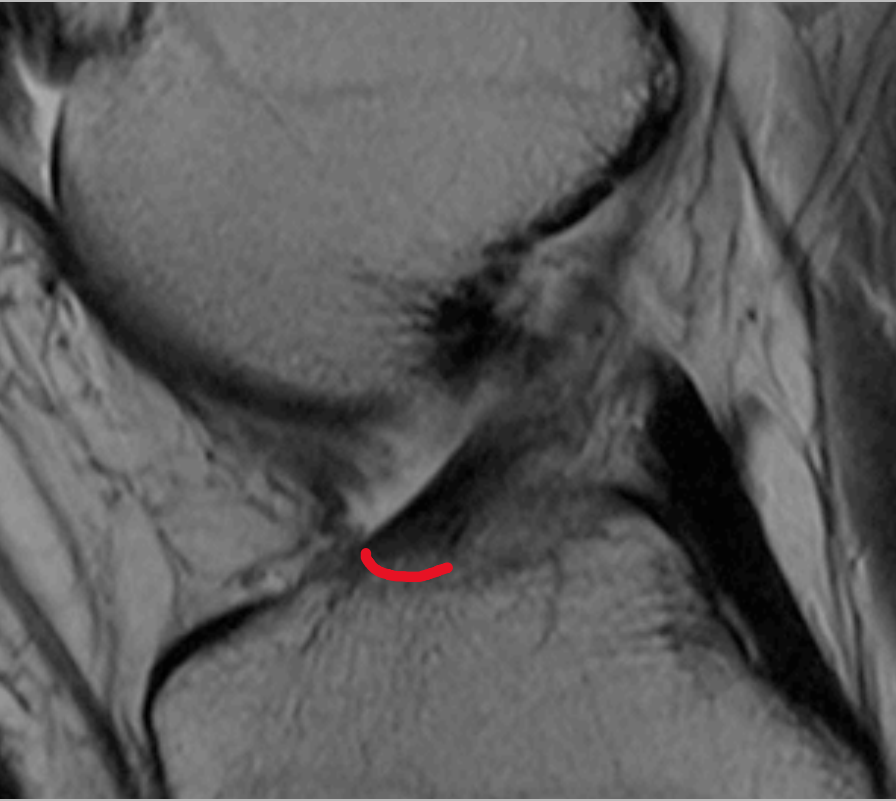
# Posterolaterala hörnet

Pawel Szaro, med dr  
Avdelningen för radiologi,  
Sahlgrenska Universitetssjukhuset, Mölndal  
[pawel.szaro@gu.se](mailto:pawel.szaro@gu.se)

ACL

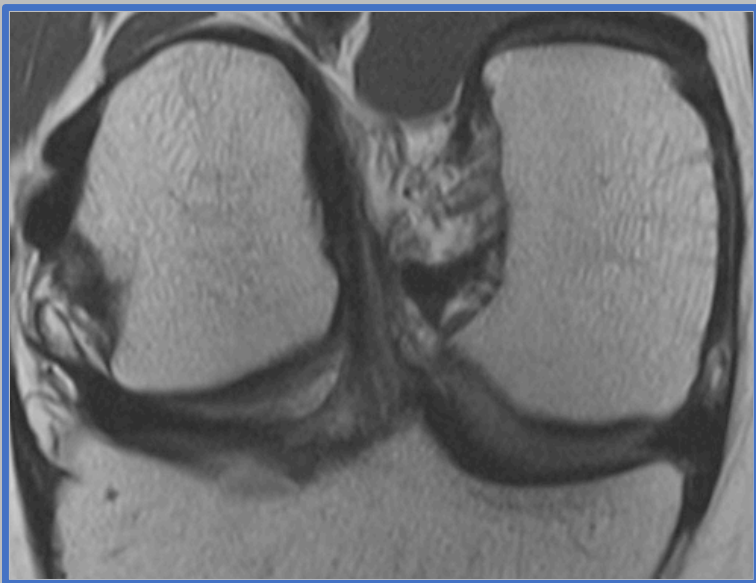
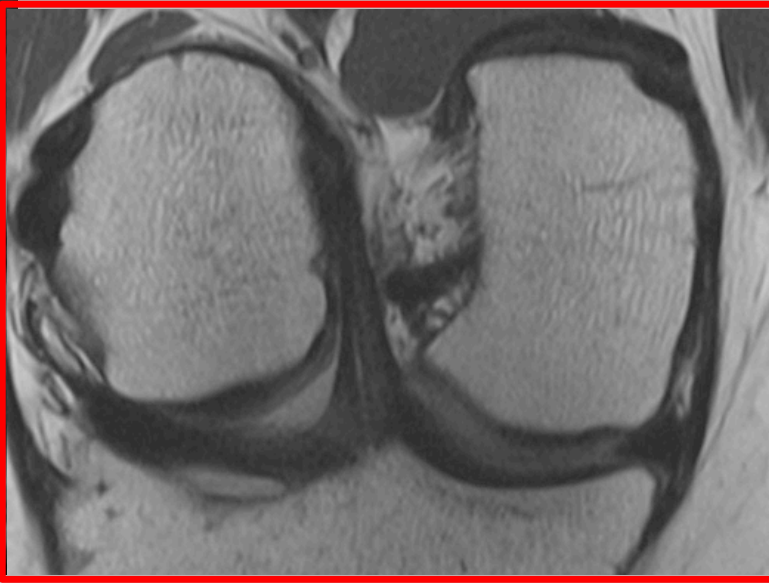
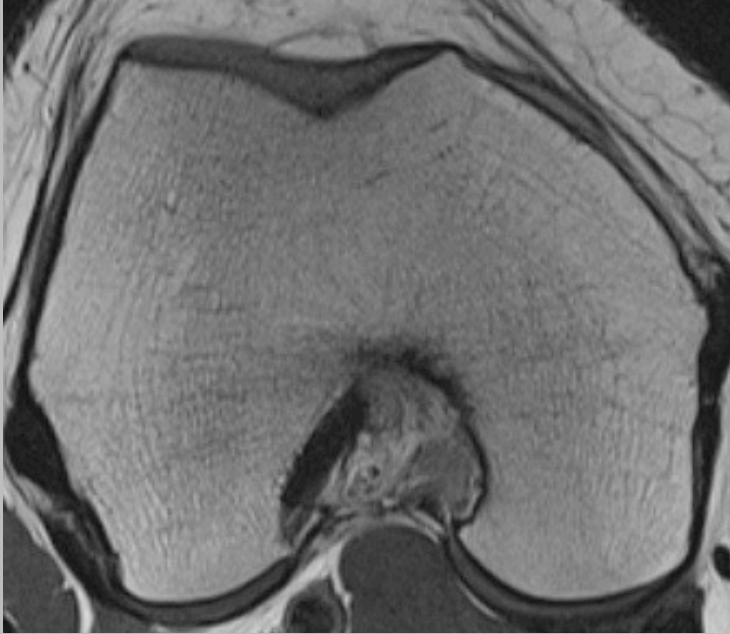
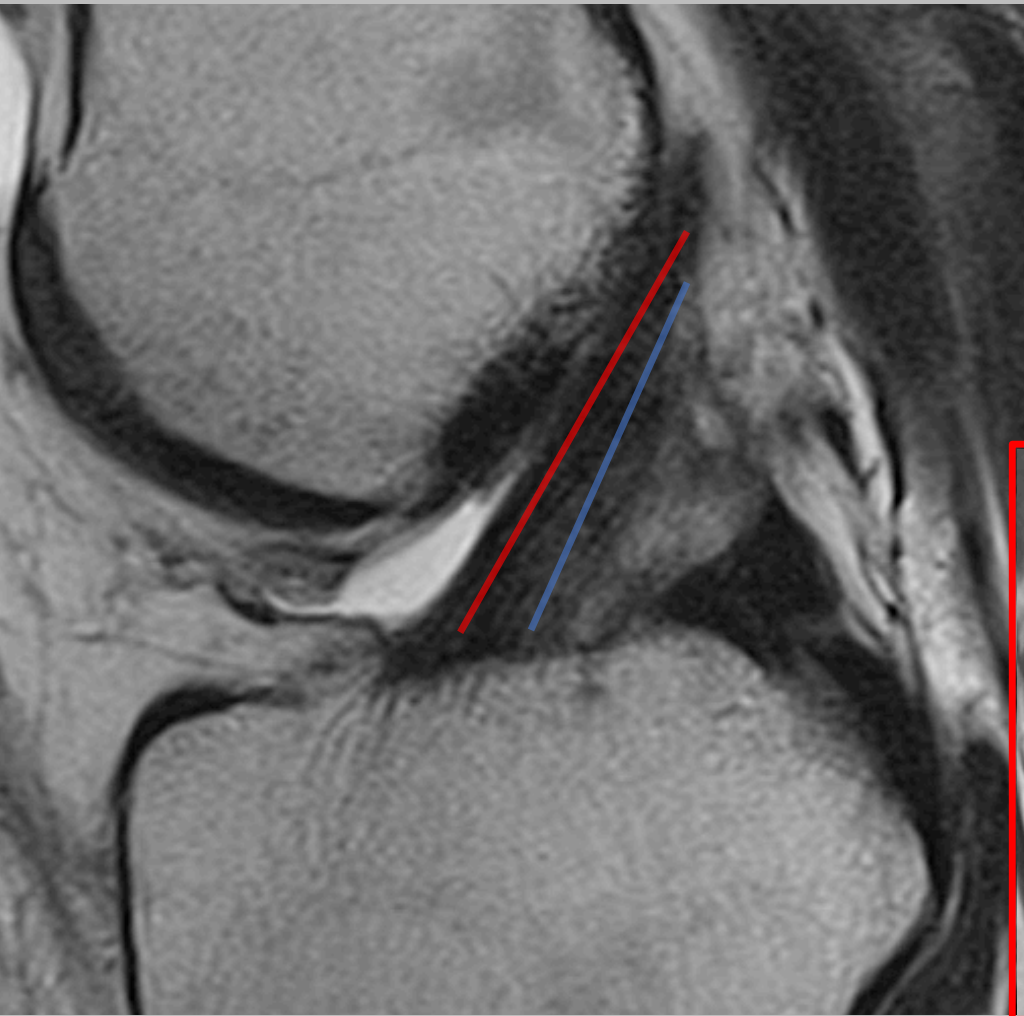


# ACL: AM och PL

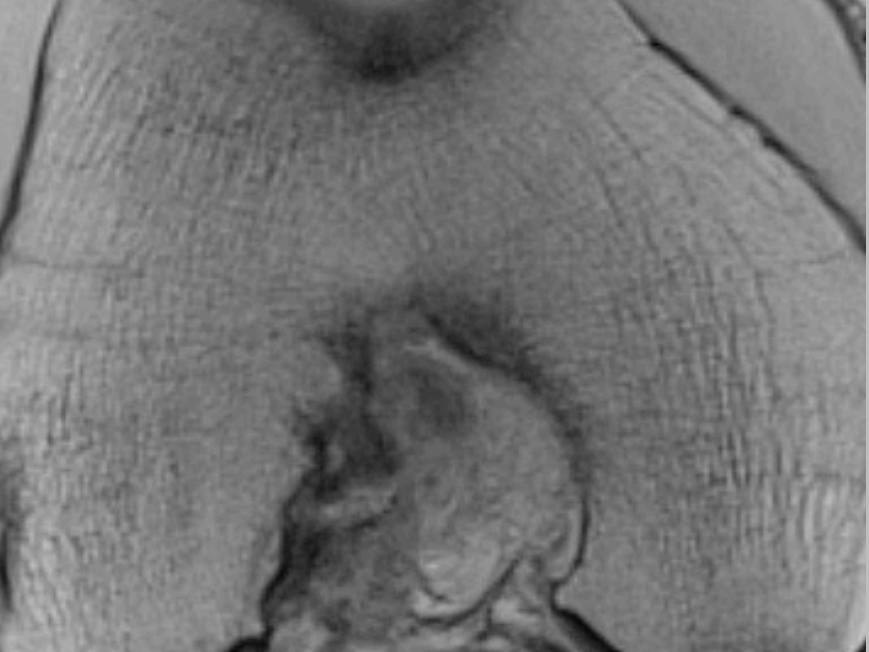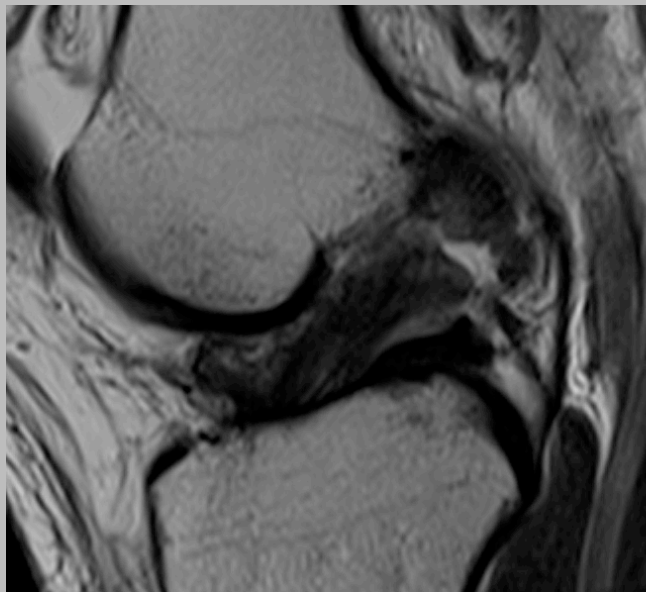
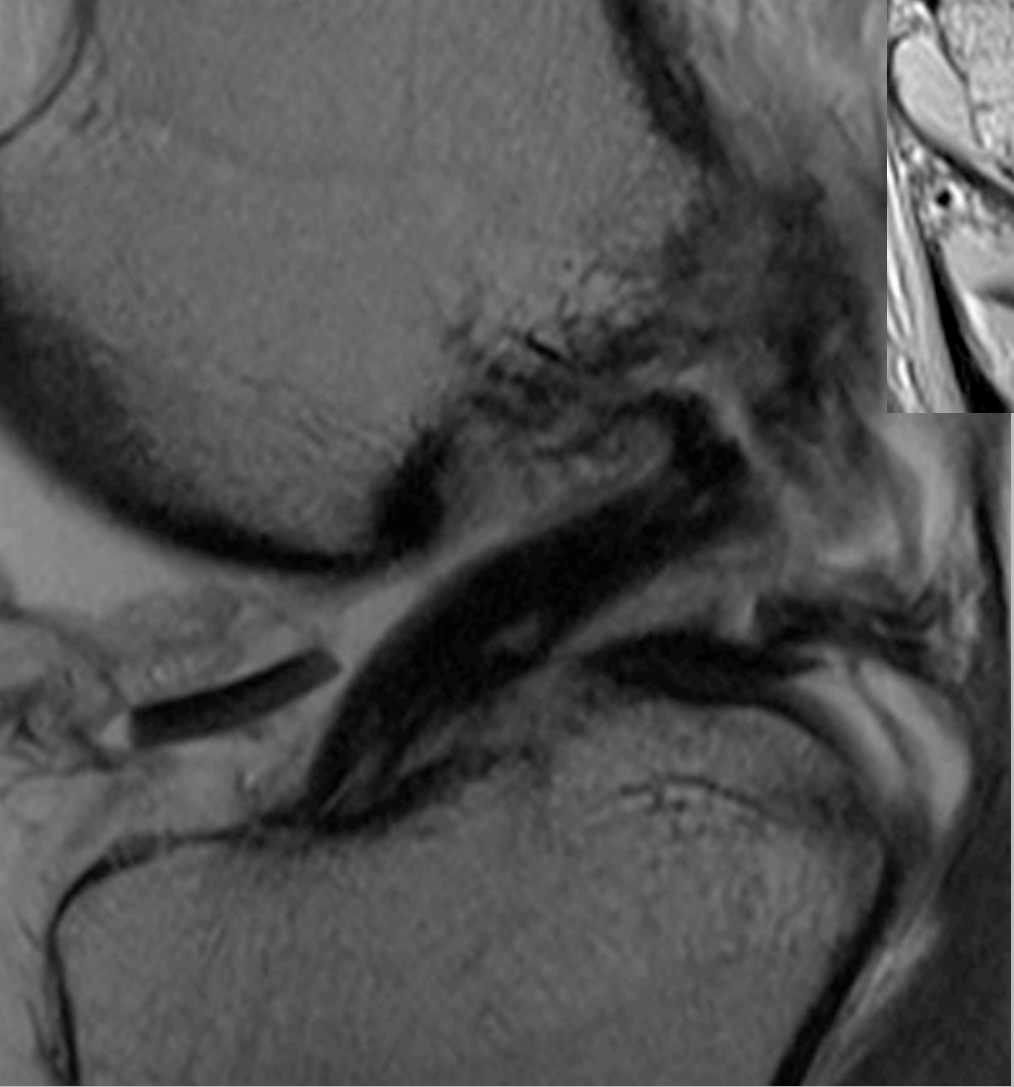
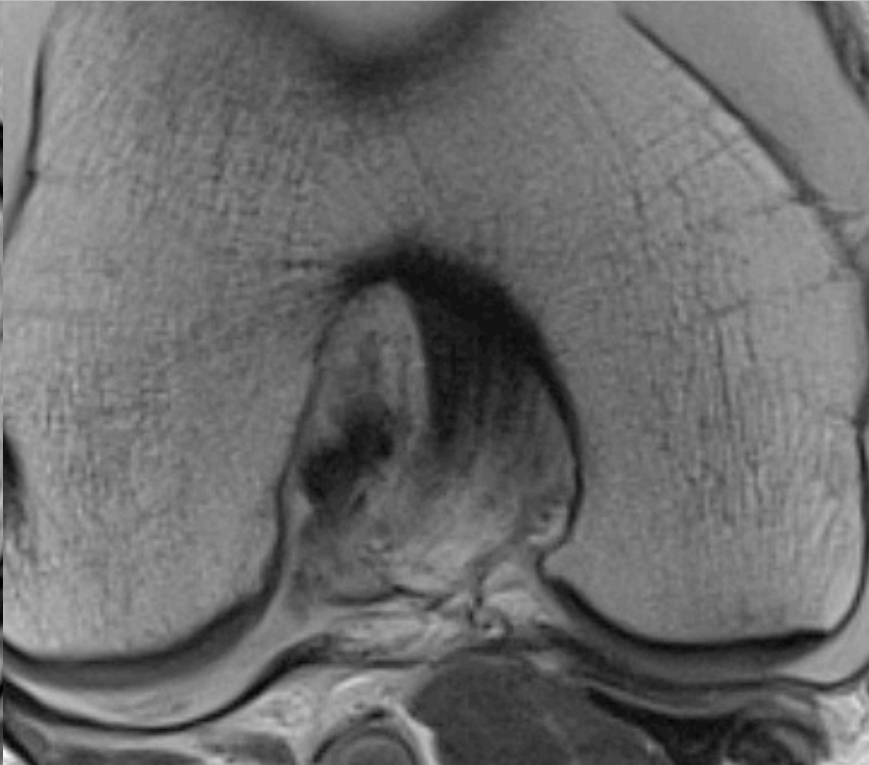
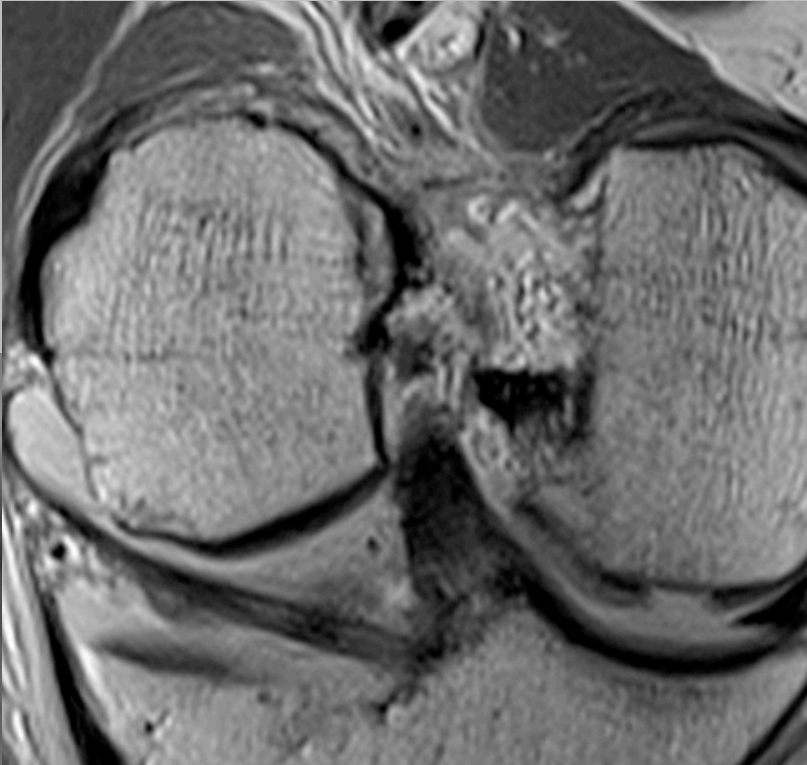




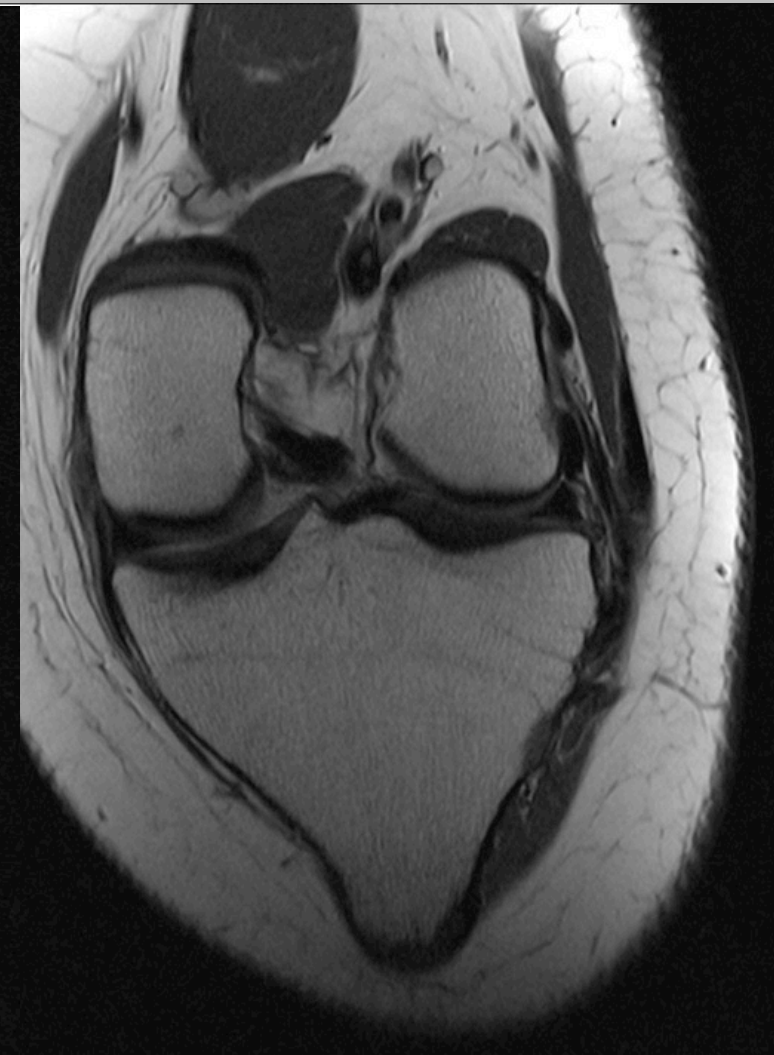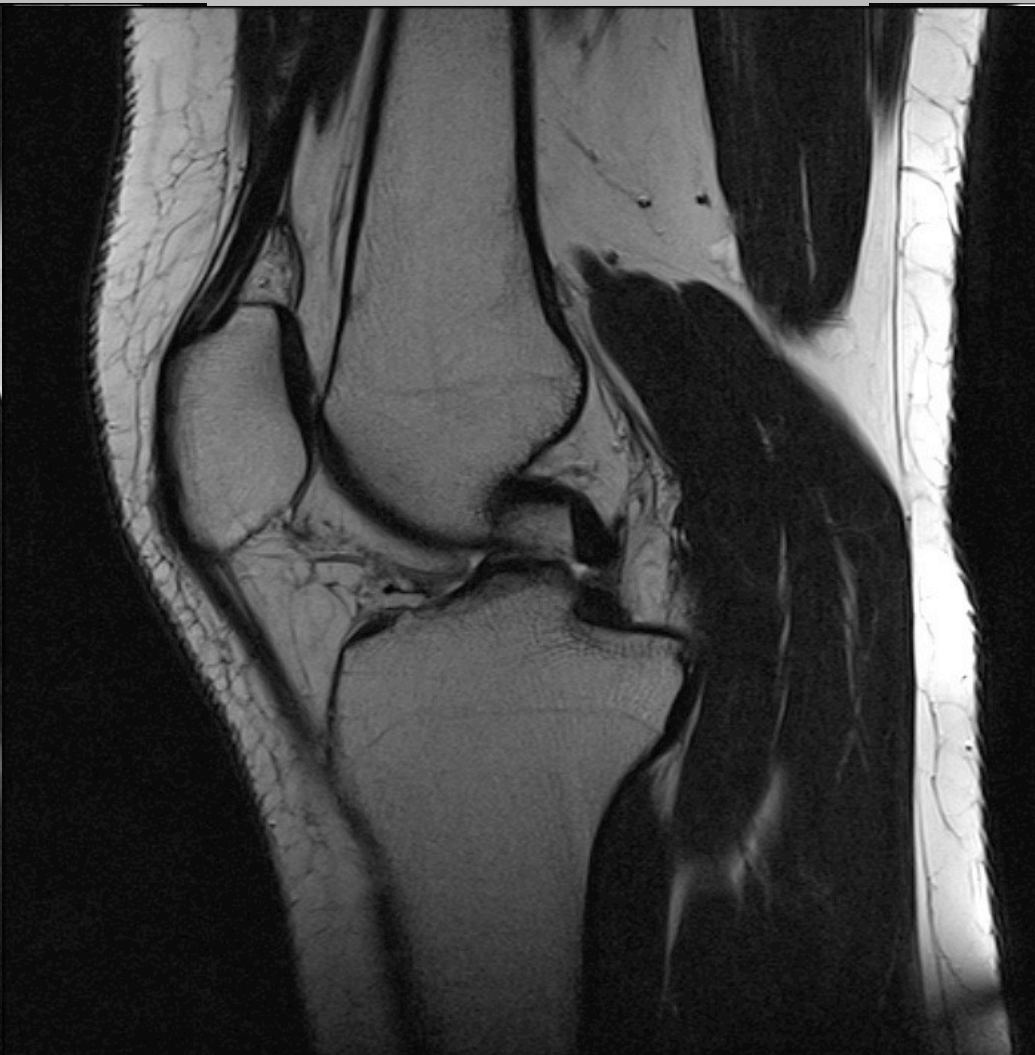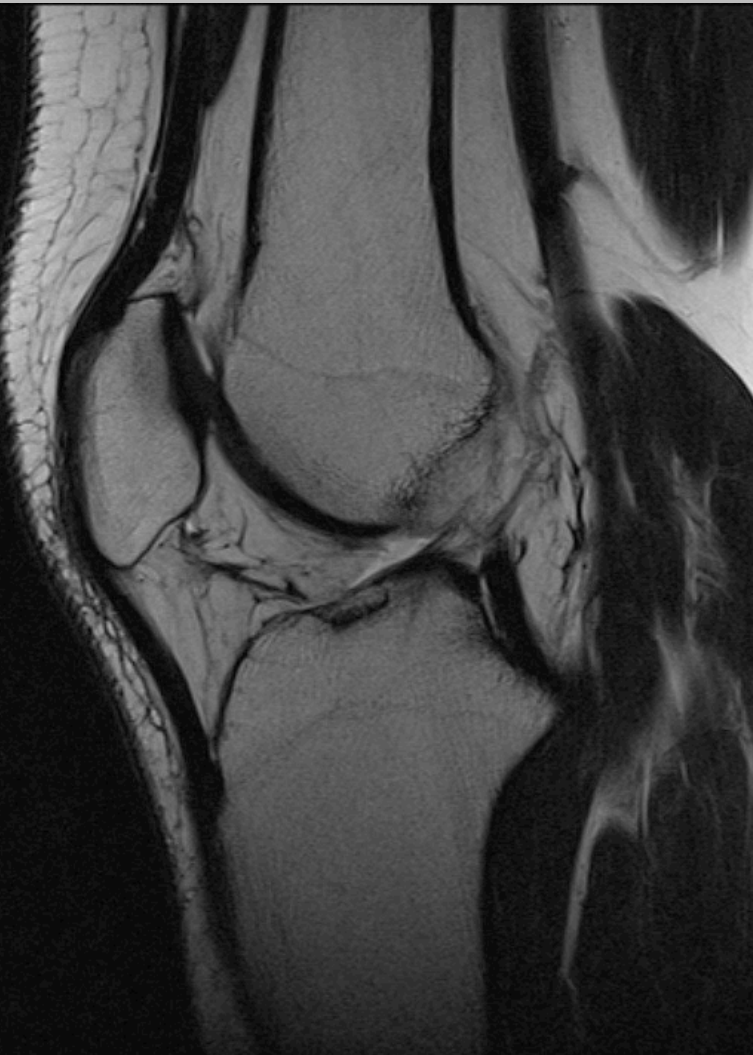ACL: AM och PL



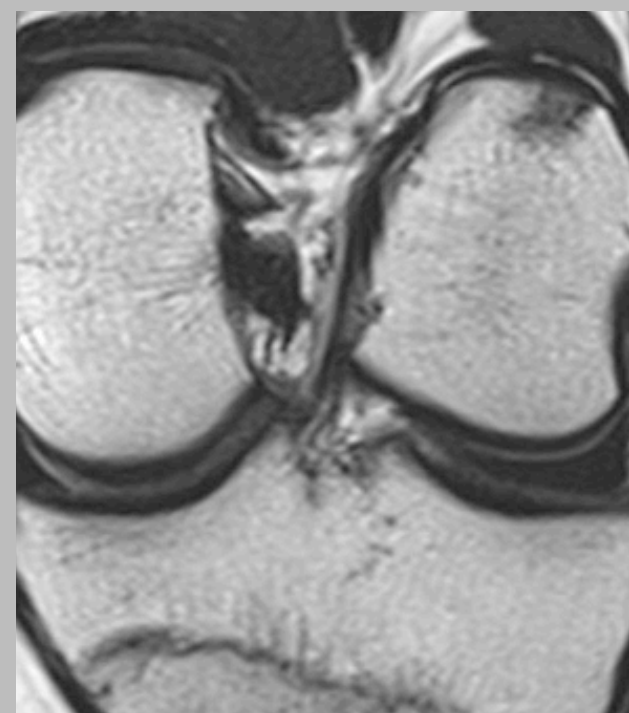
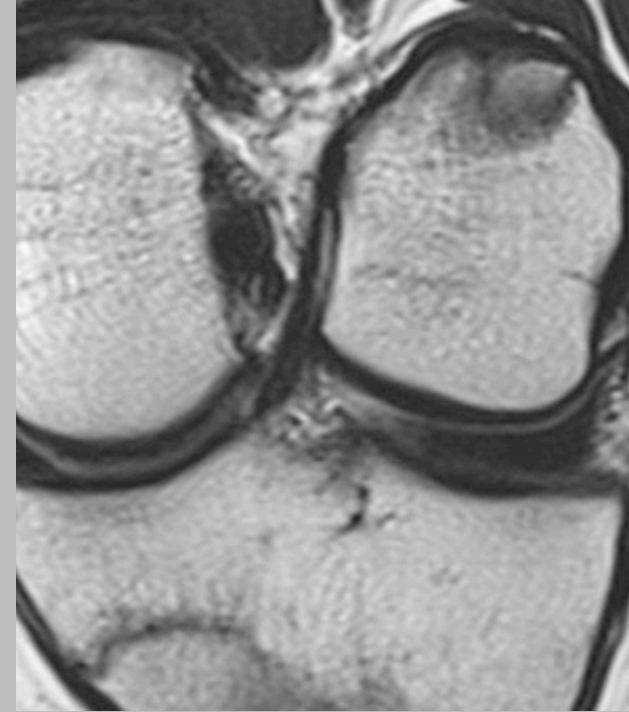
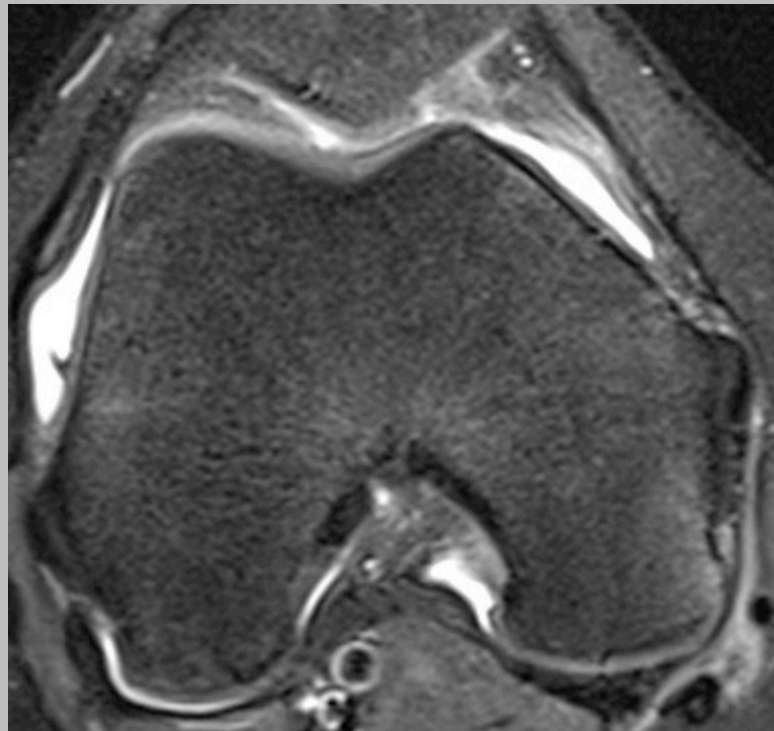
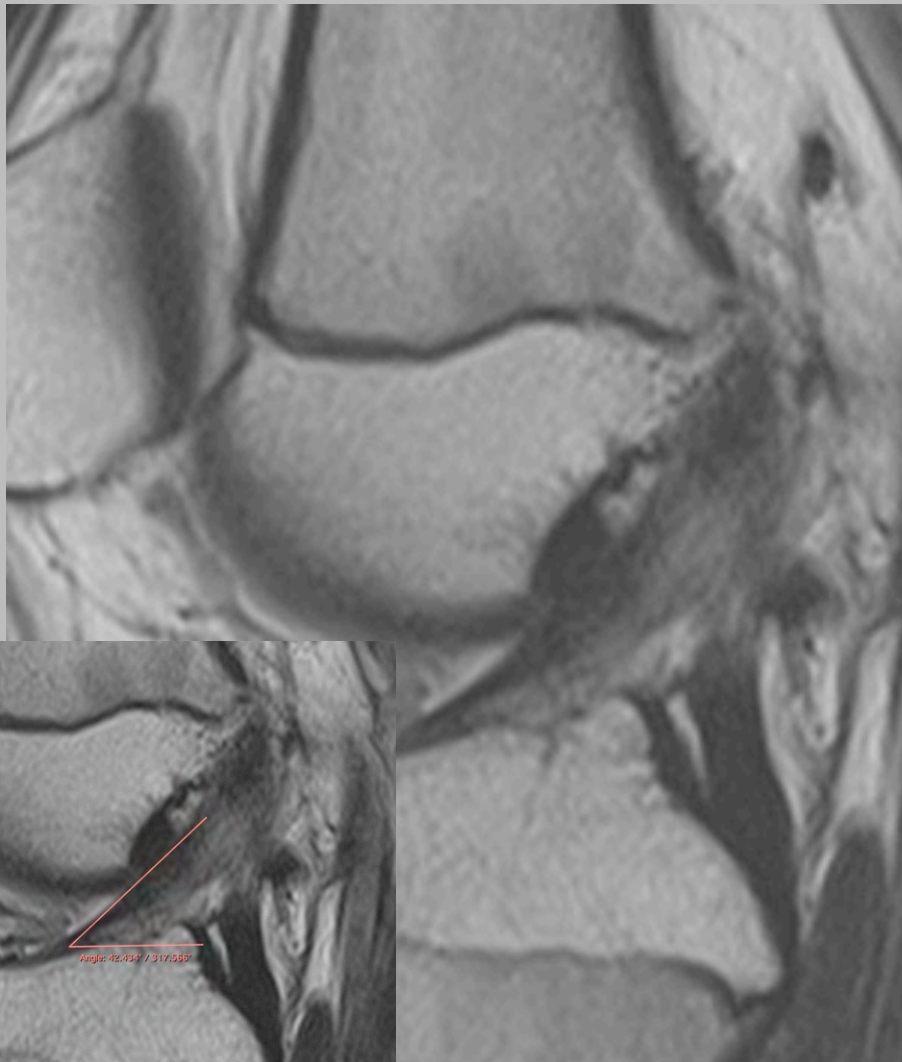
ACL ruptur



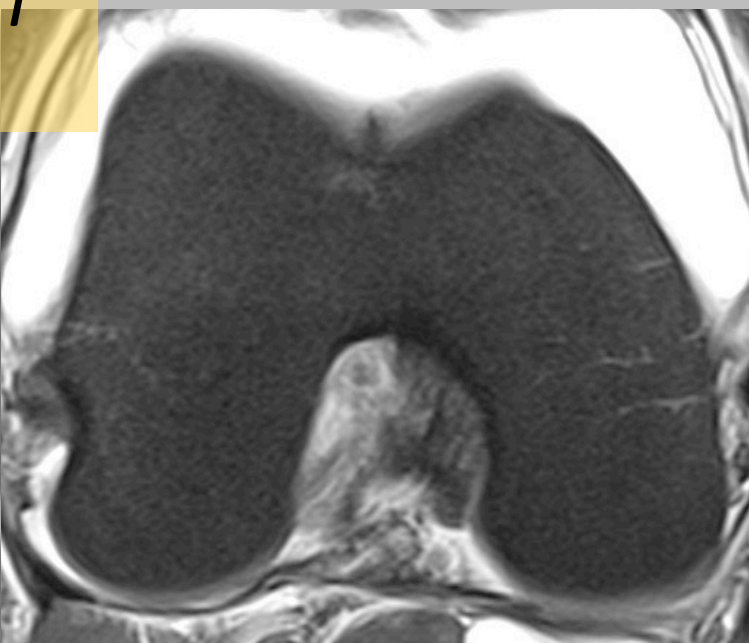
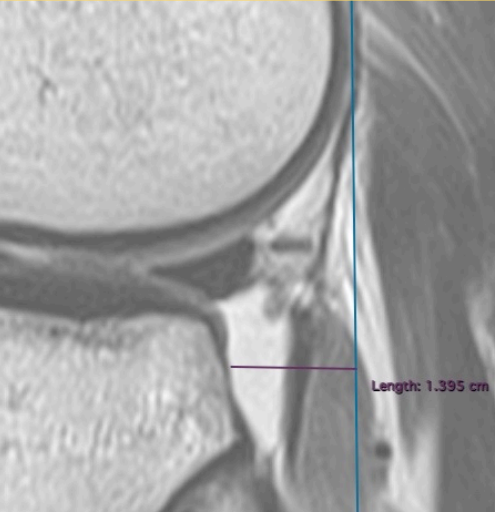
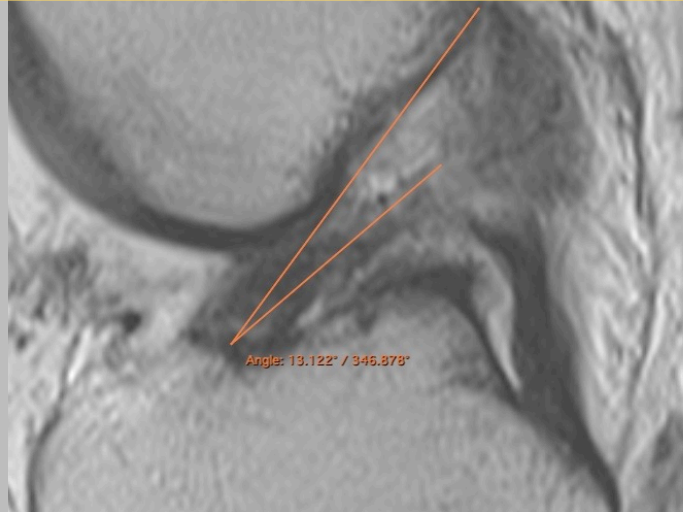
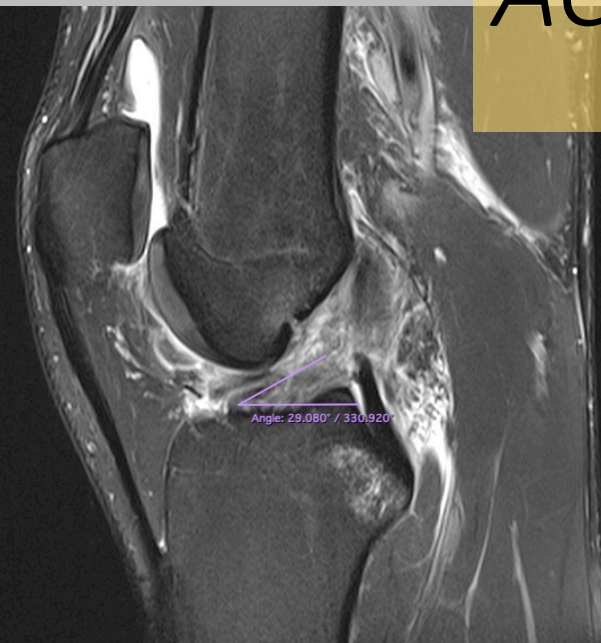
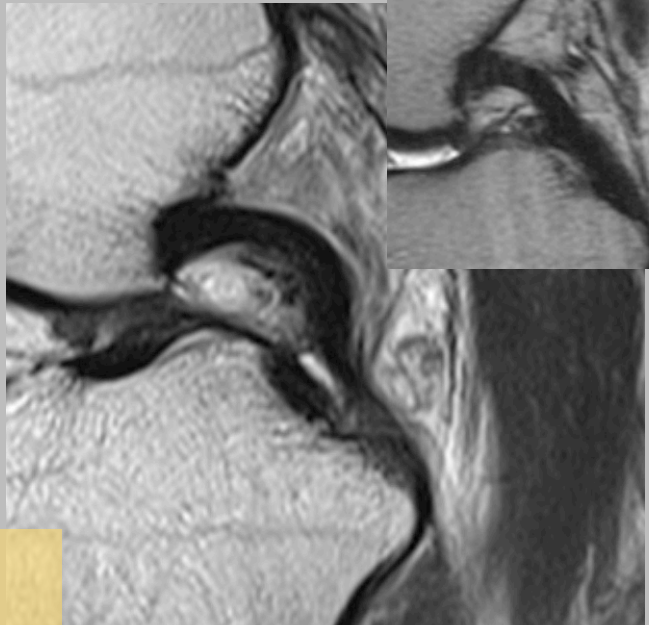
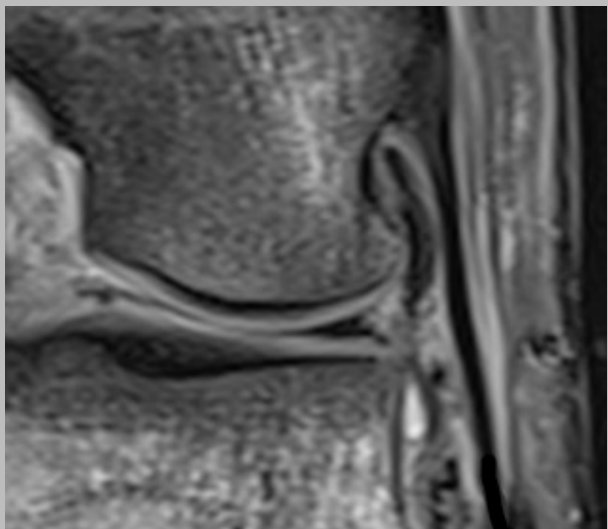
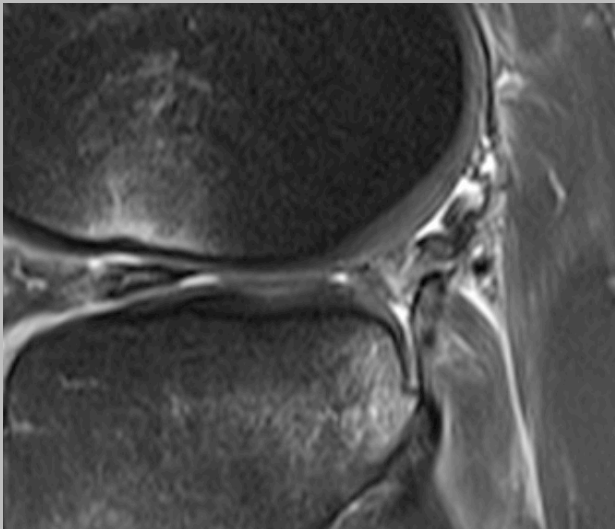
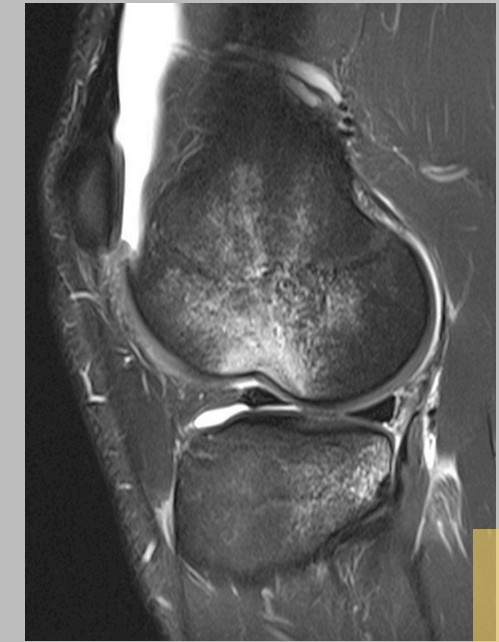# ACL ruptur



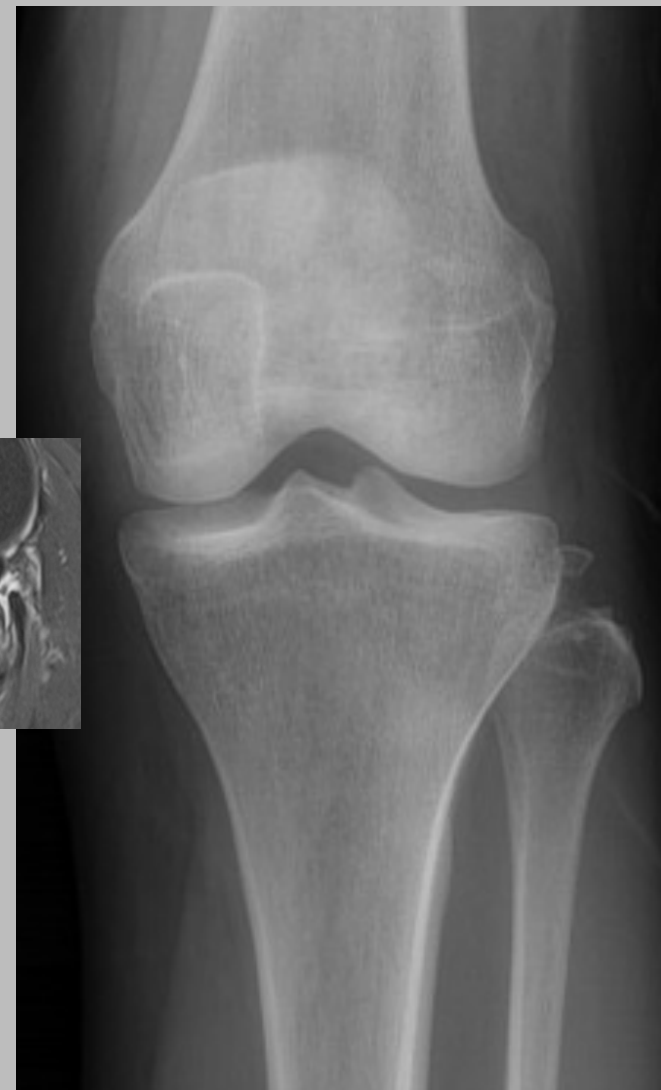
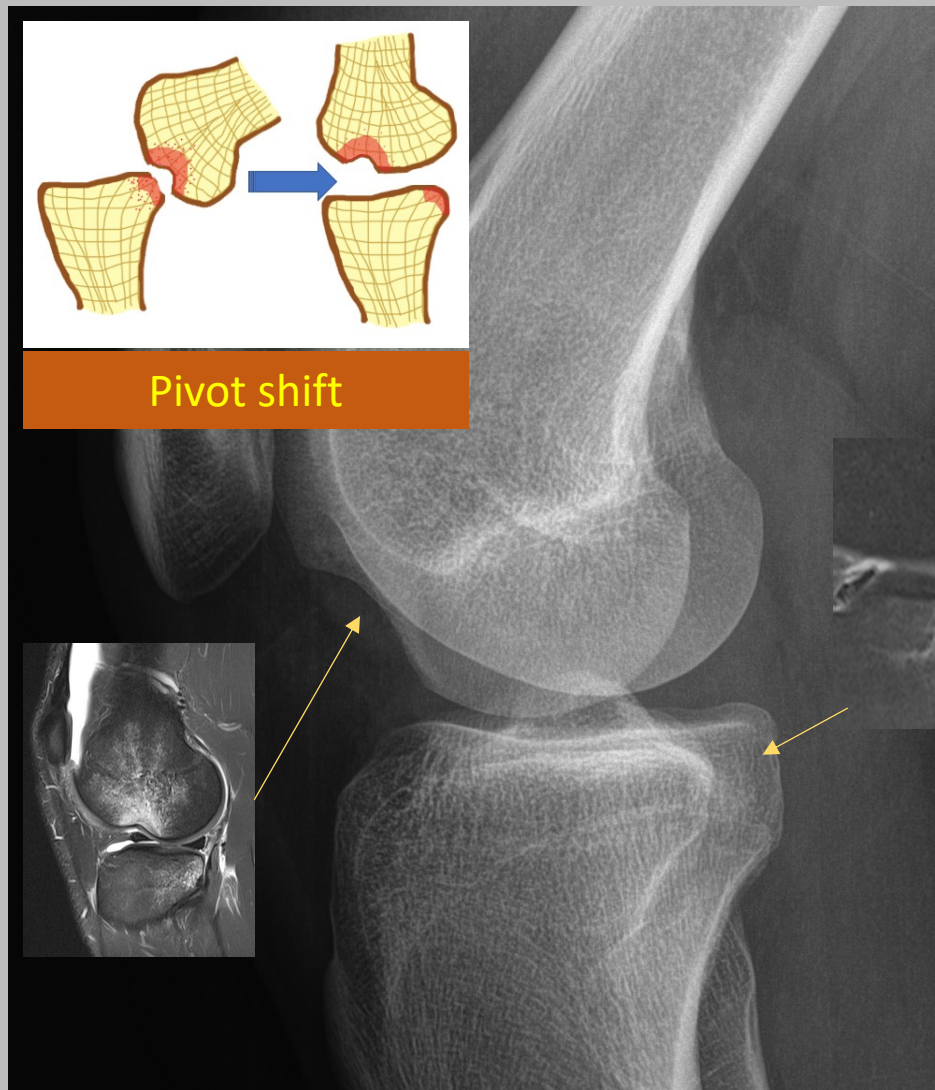
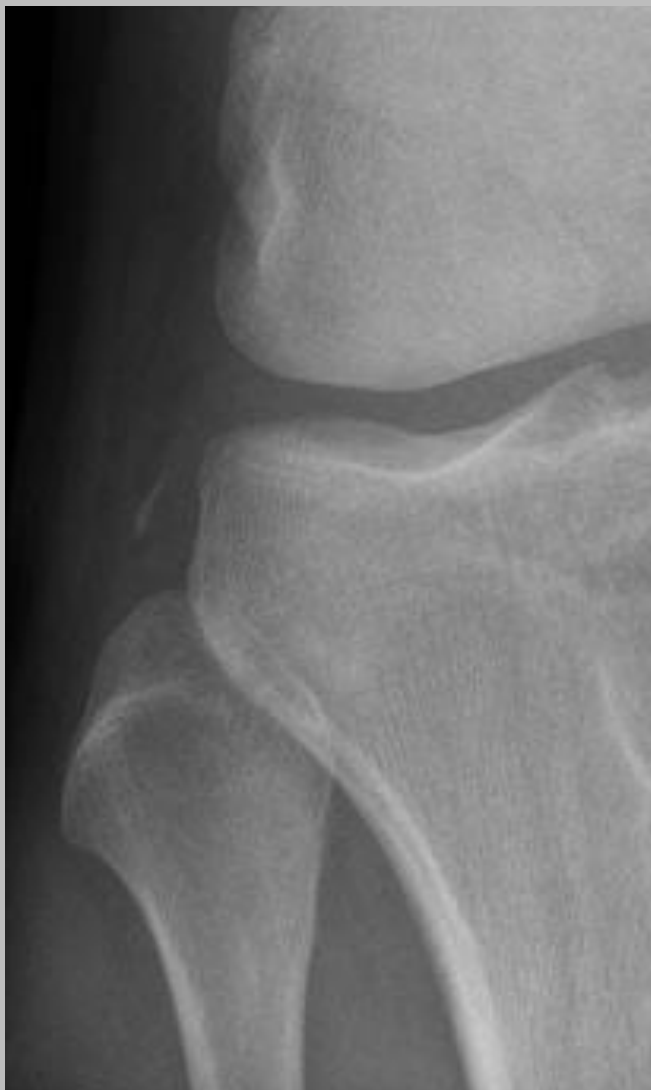# ACL partiell ruptur



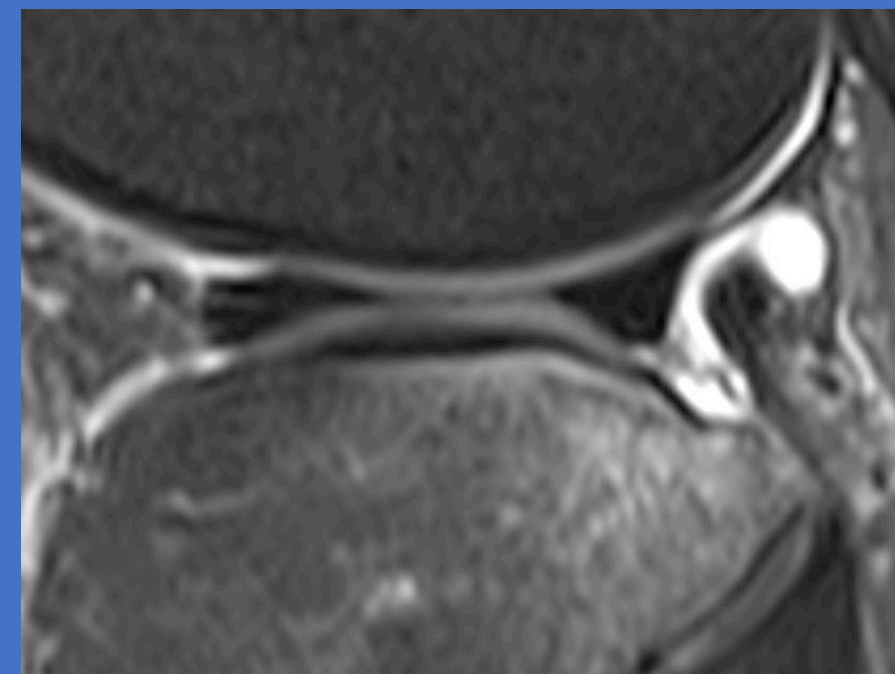
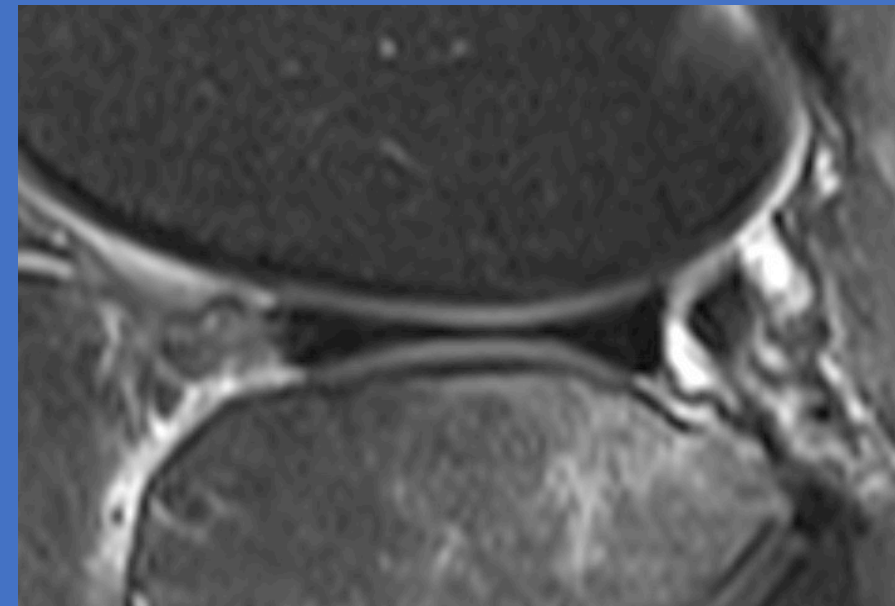
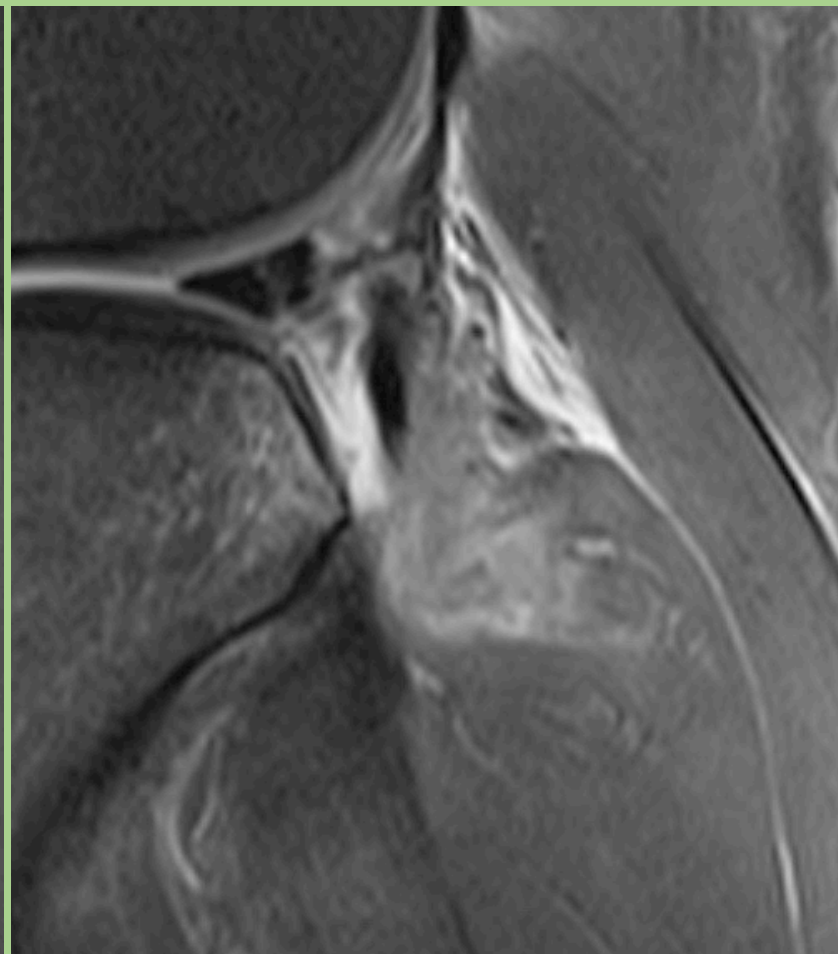
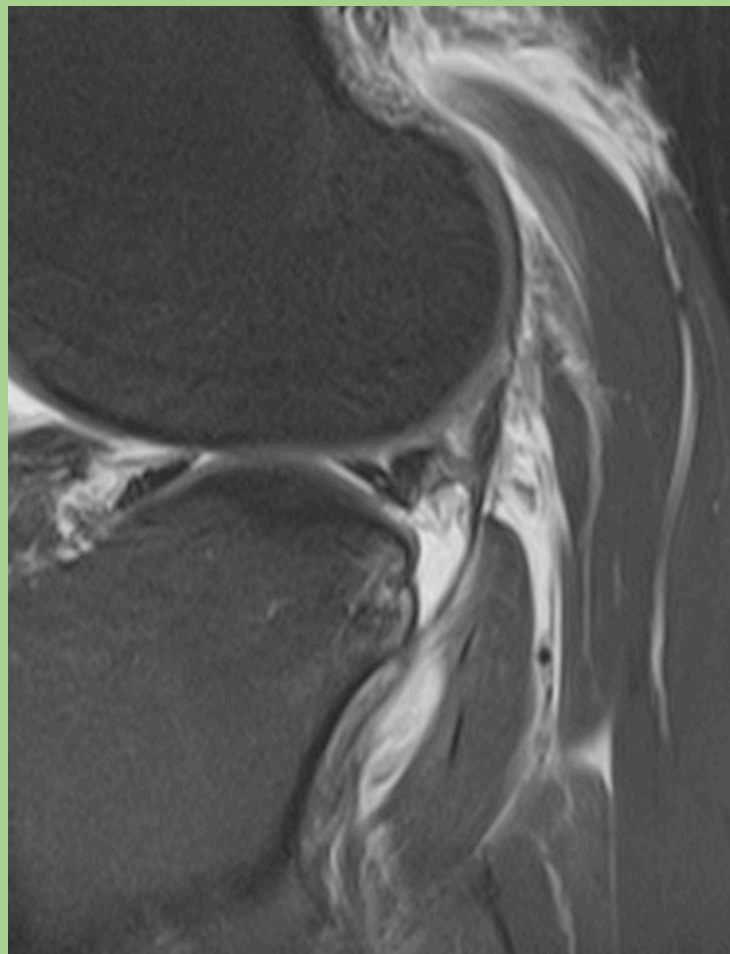
*ACL ruptur – indirekta tecken*



# Frakturer som hänger ihop med ACL ruptur



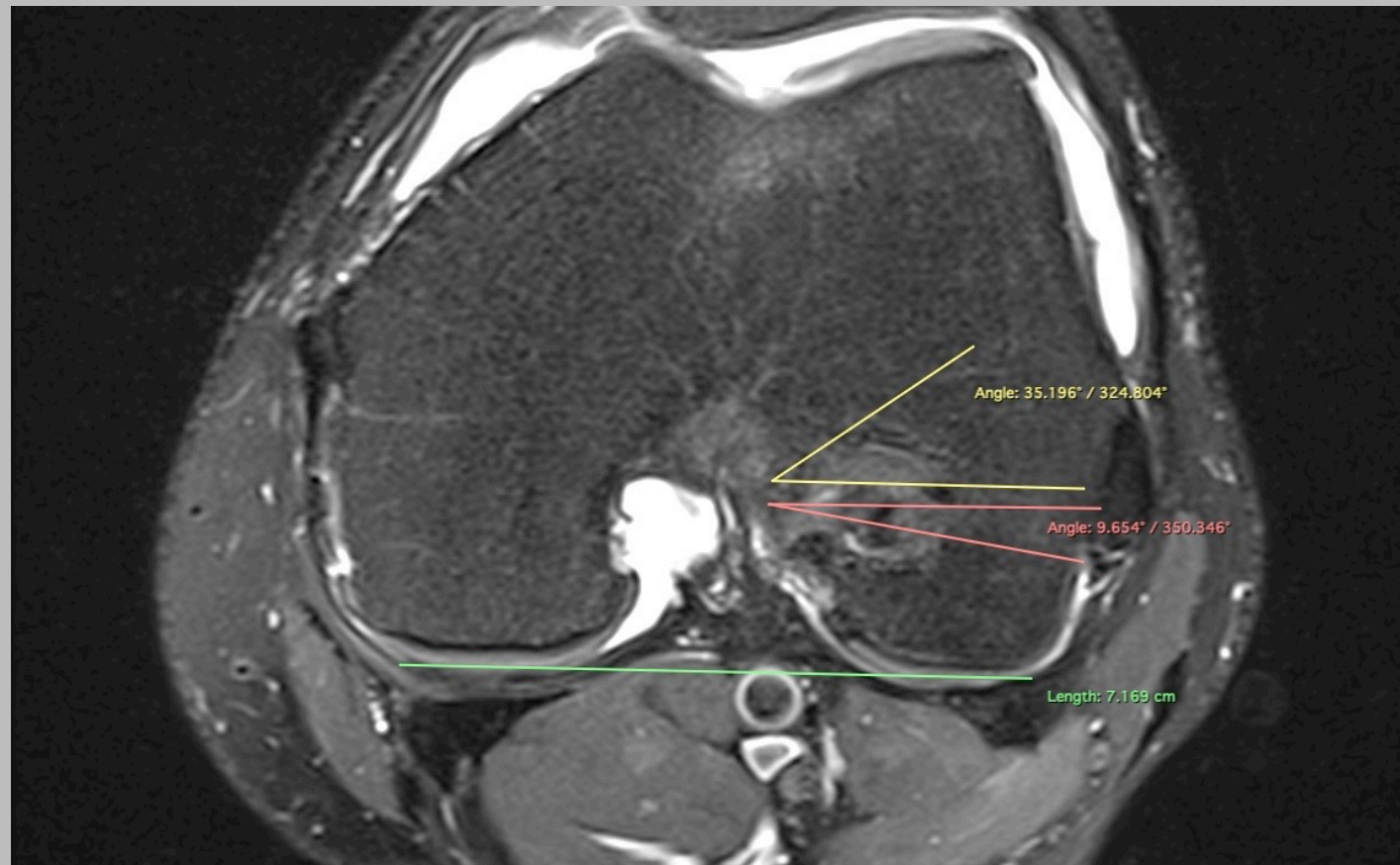
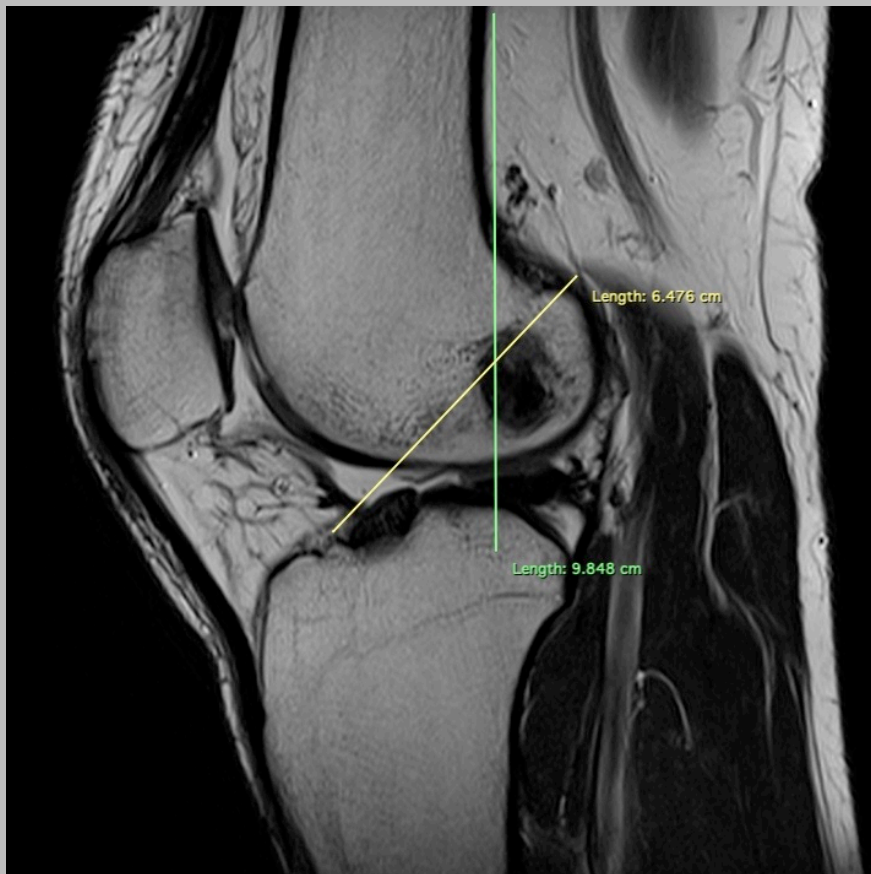
# Skador som hänger ihop med ACL ruptur



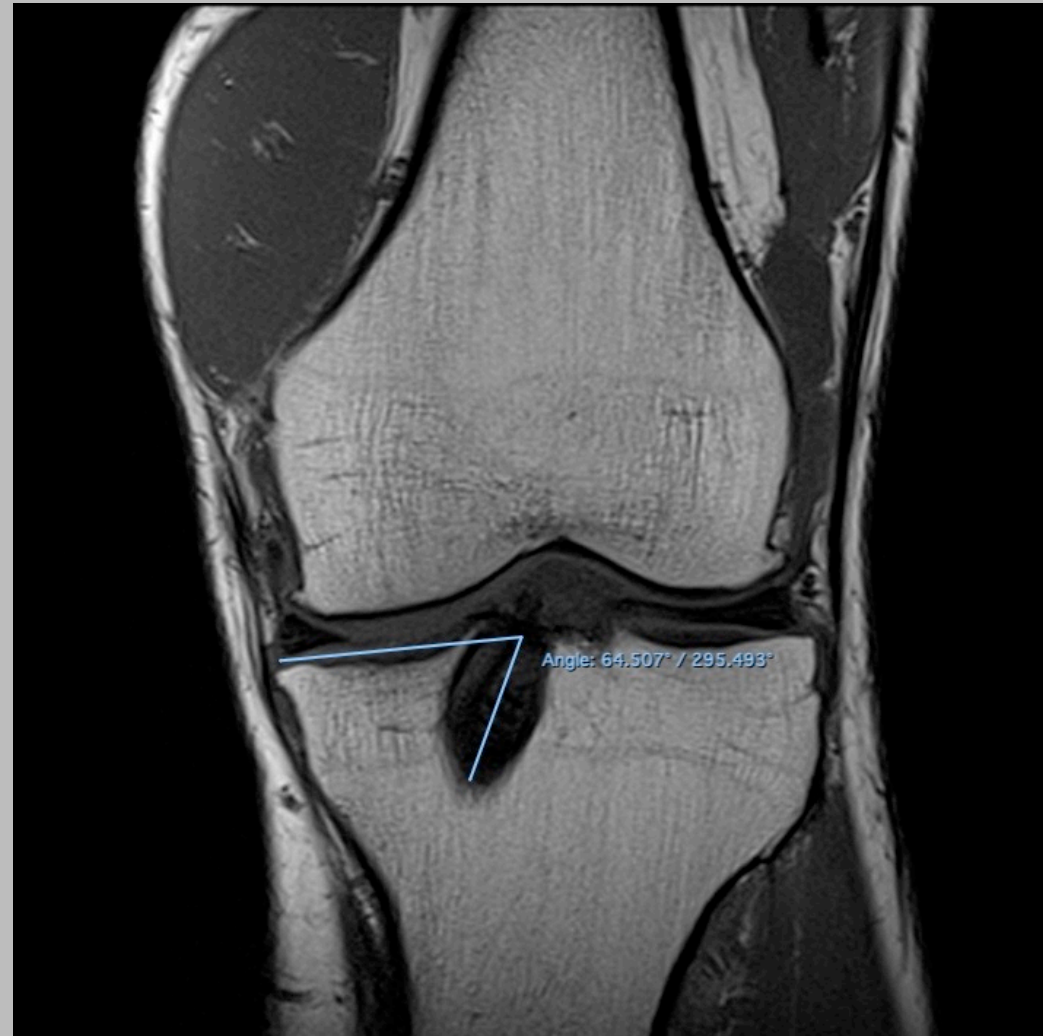
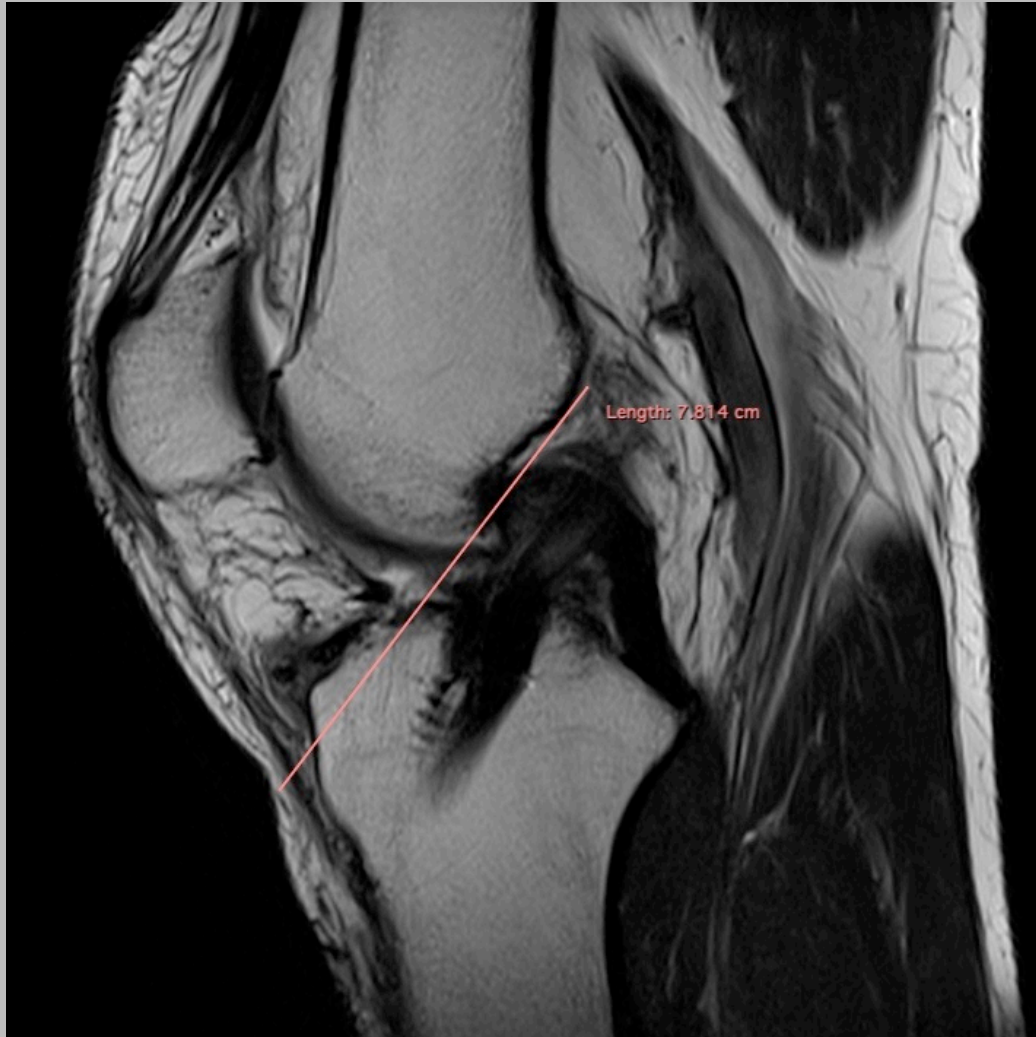



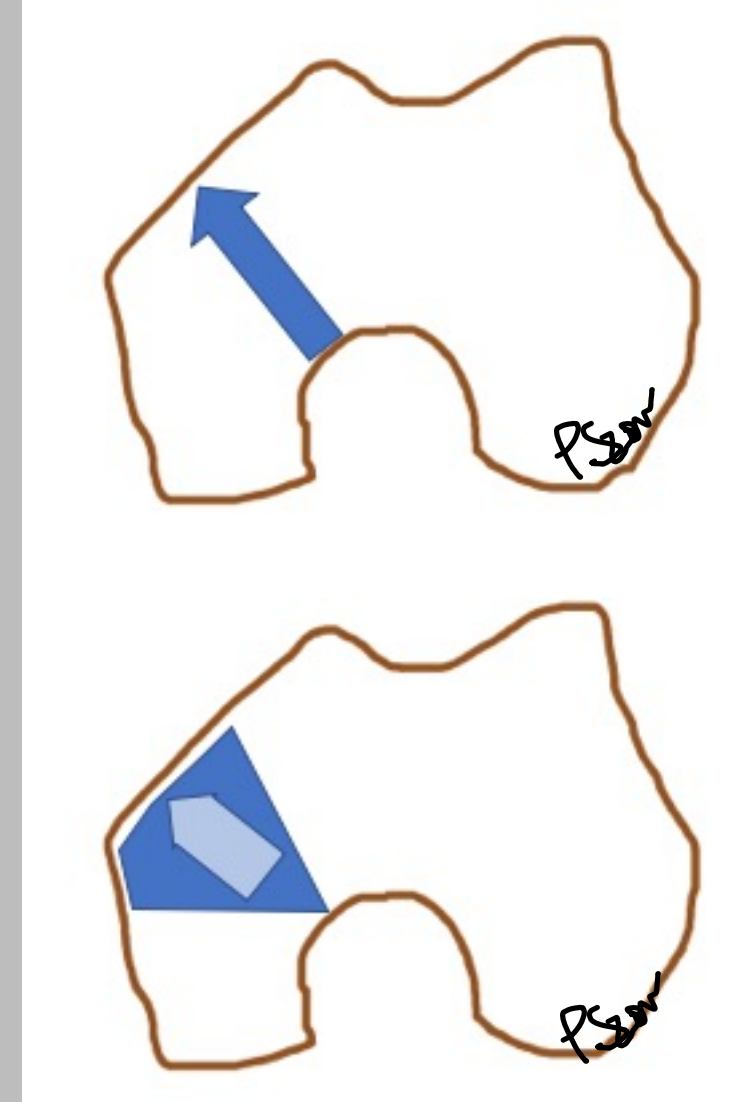
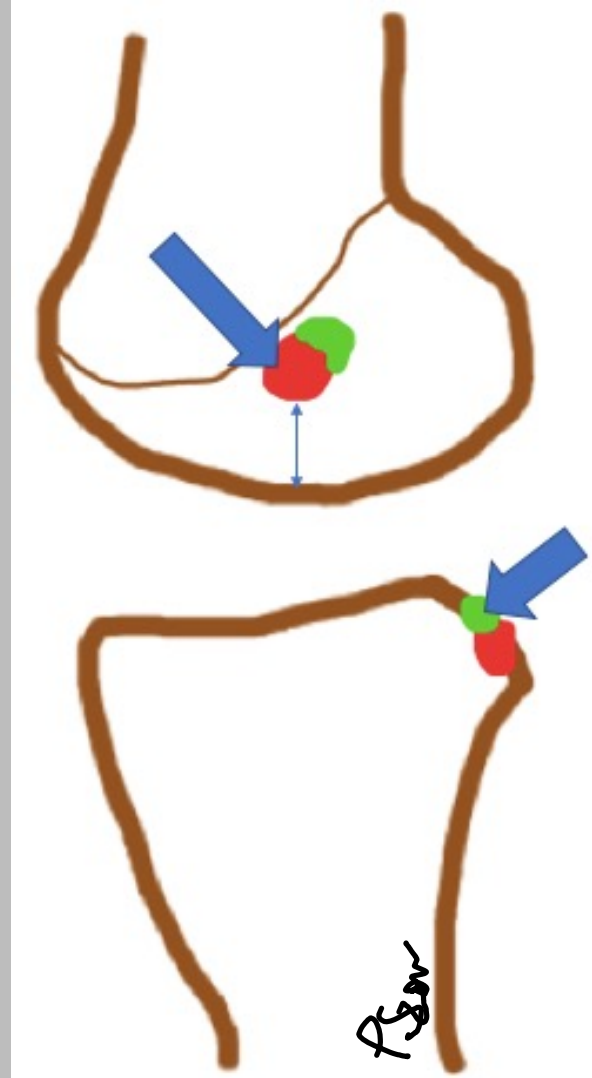
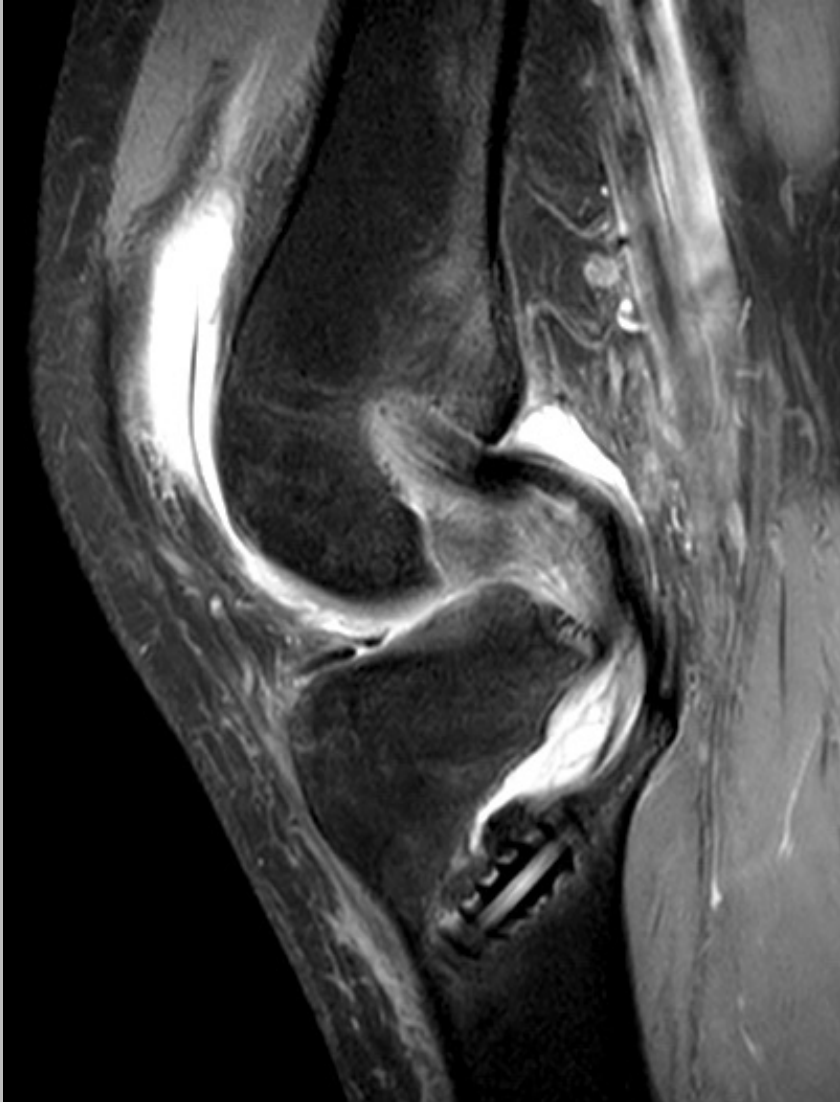# Graft ACL (femurkomponent)



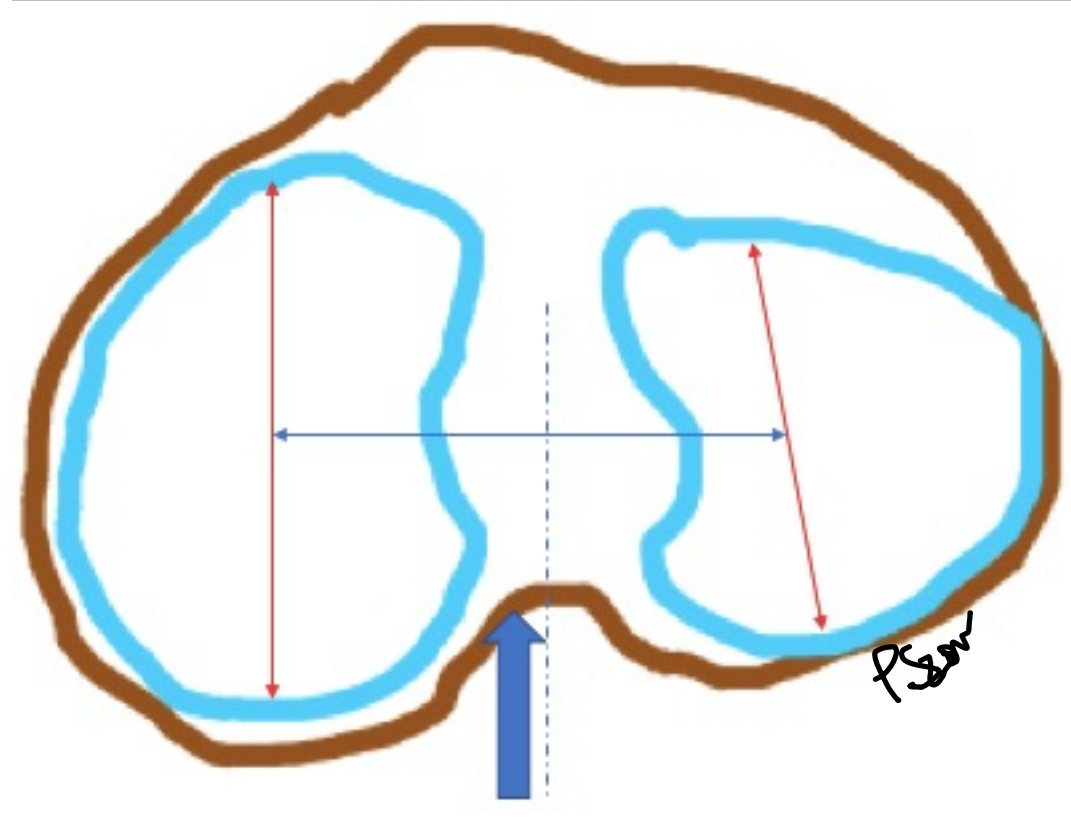
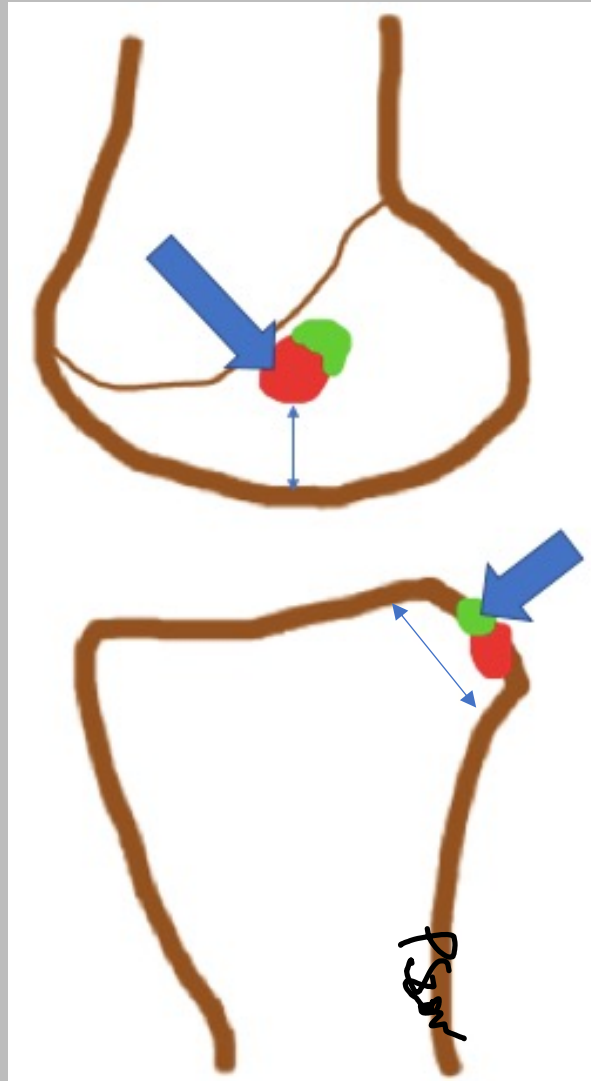
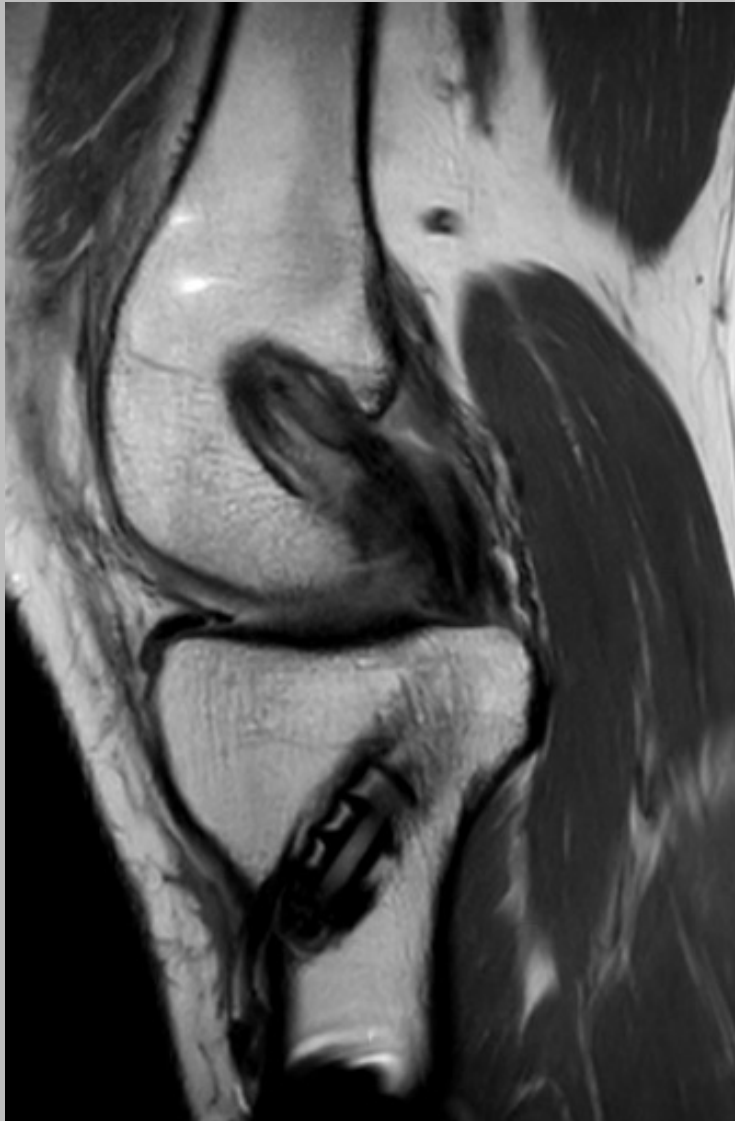# Graft ACL (tibiakomponent)



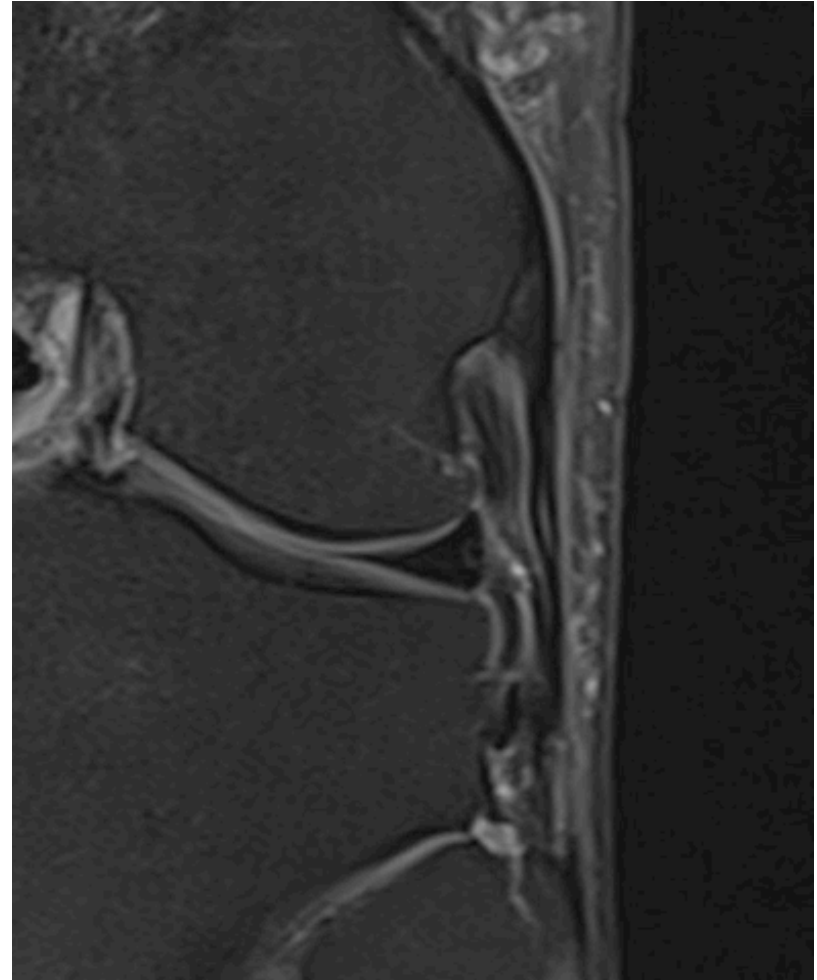
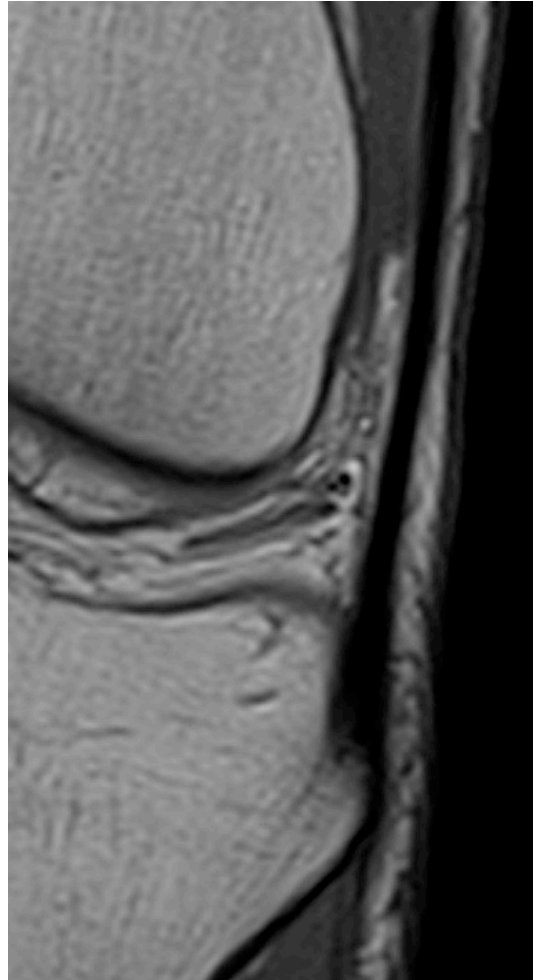
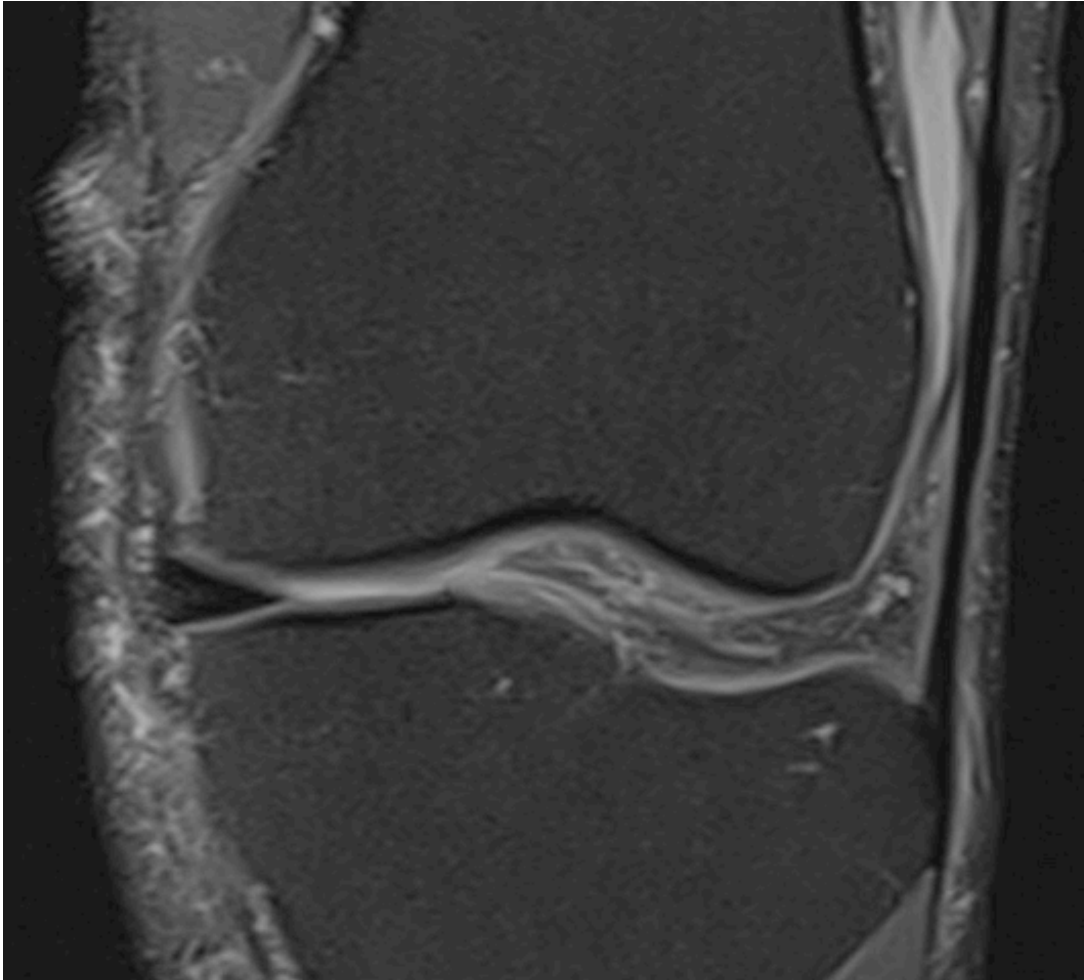
# Graft PCL (femurkomponent)



# Graft PCL (tibiakomponent)

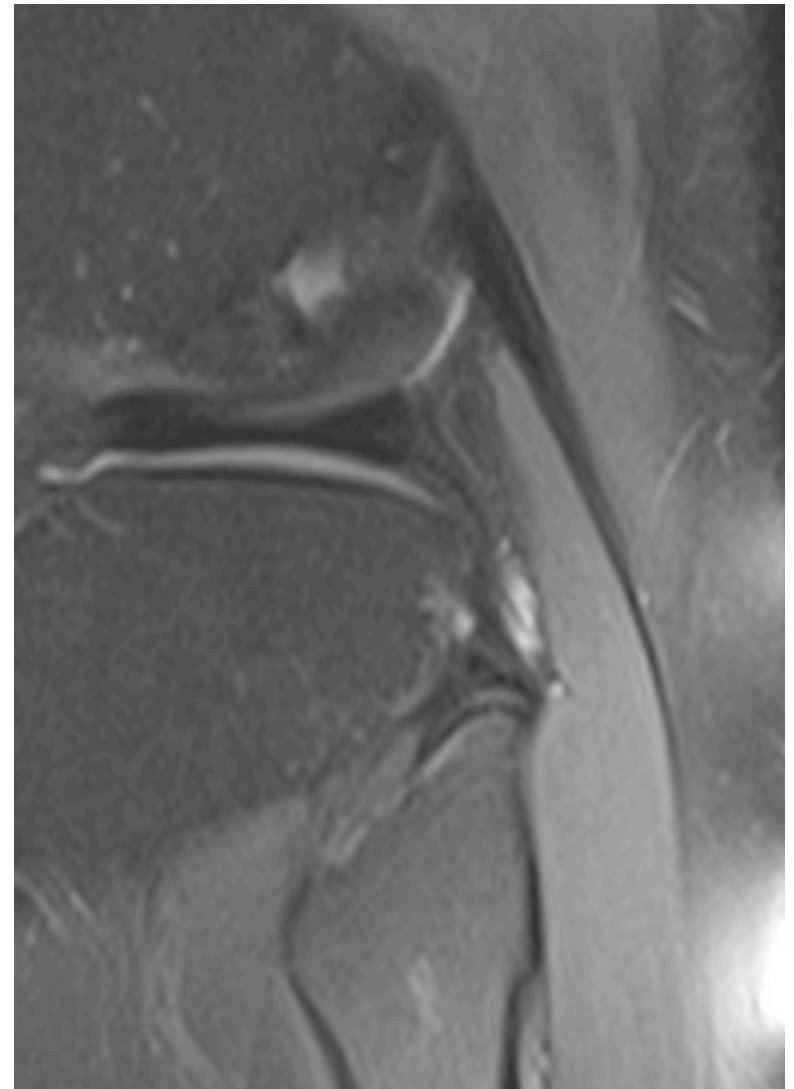
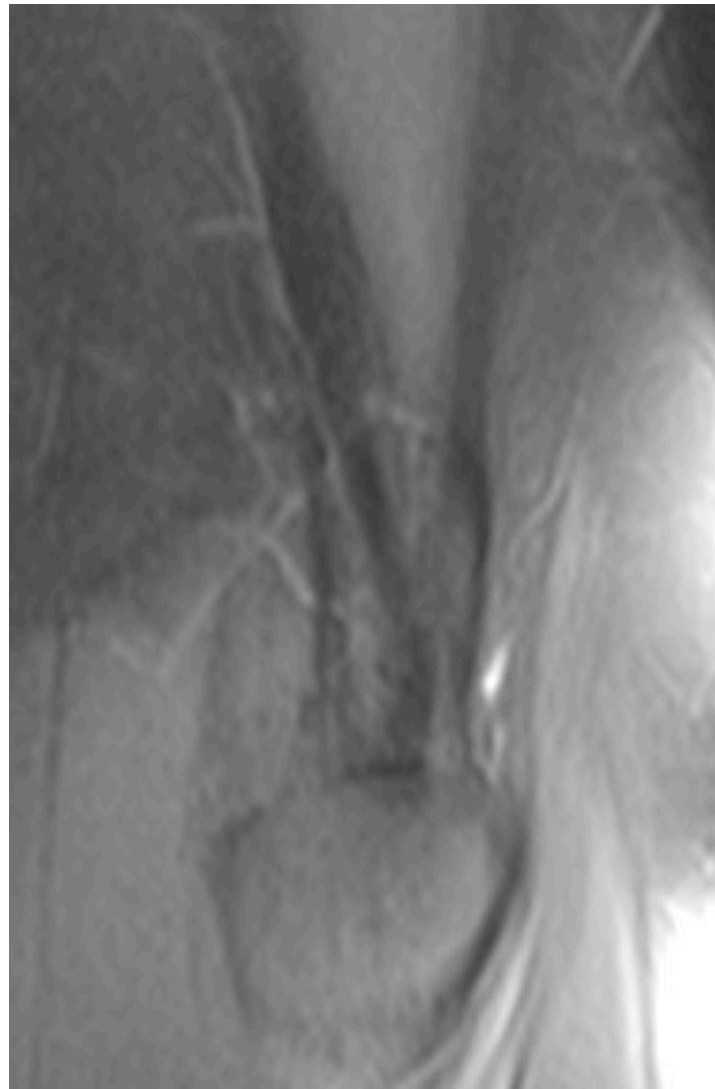
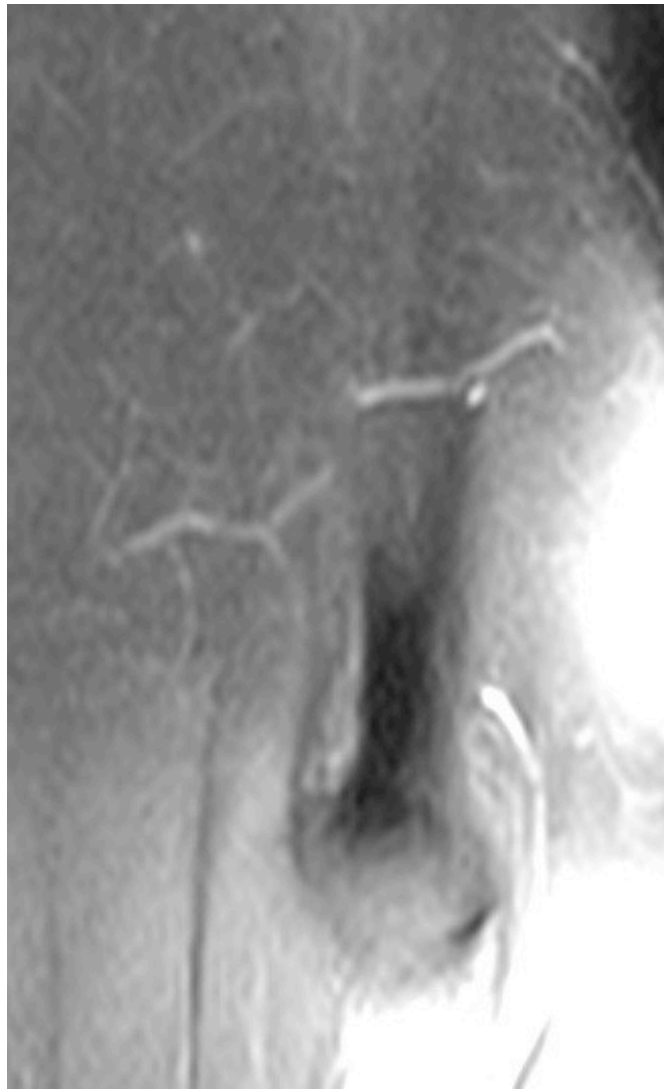


# Posterolaterala sturkturer: tractus iliotibialis och popliteus senan



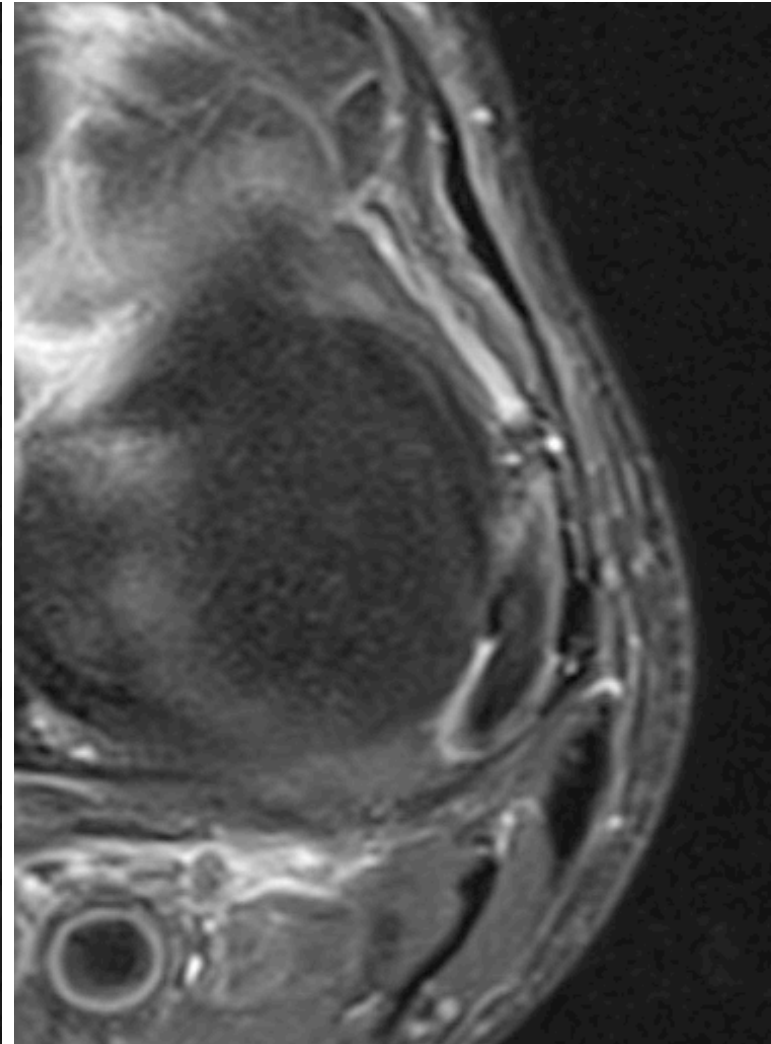
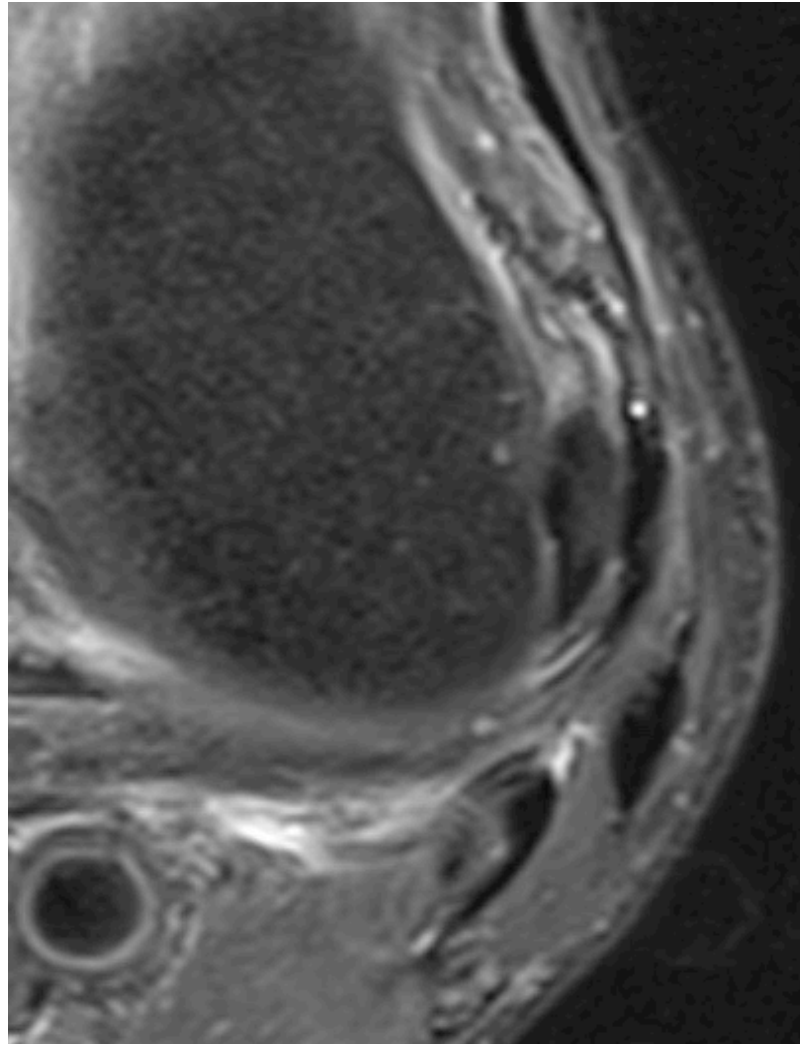
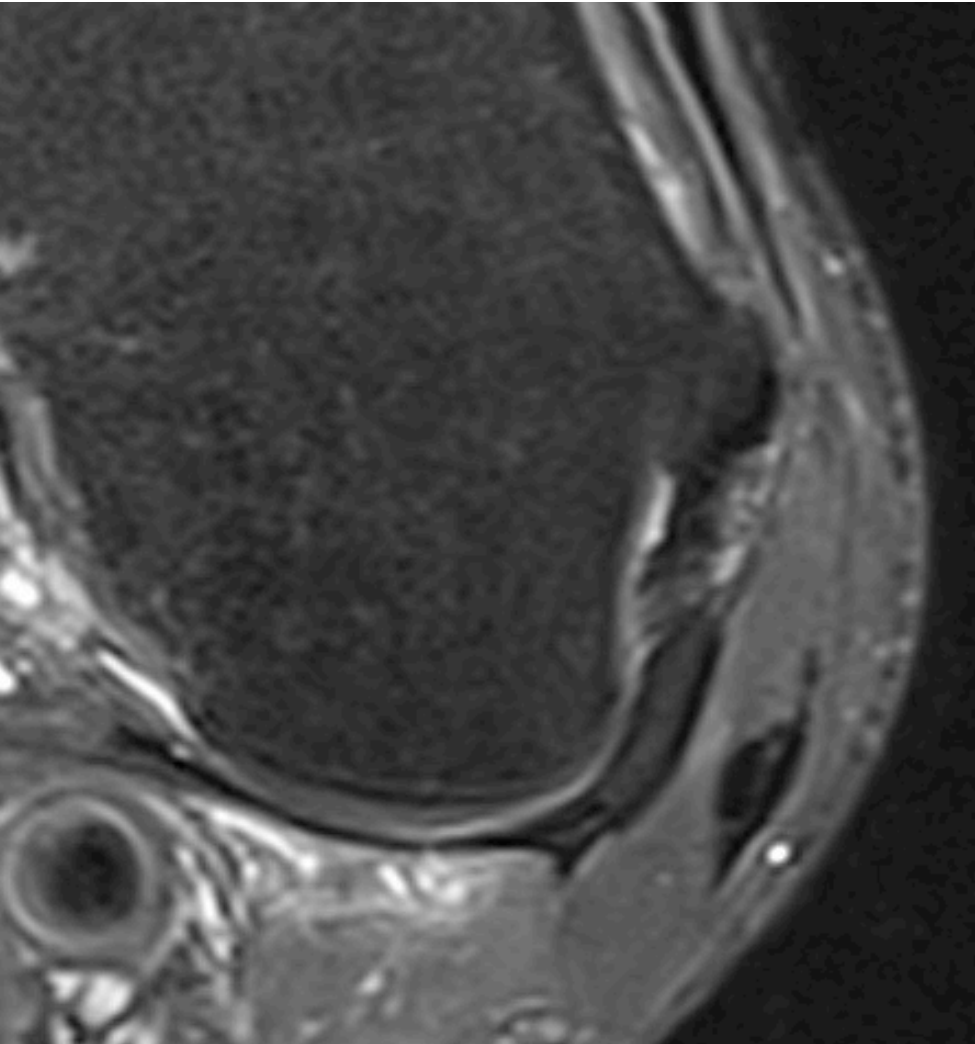
Posterolaterala sturkturer:

Biceps femoris, LCL, posterolaterala lig.

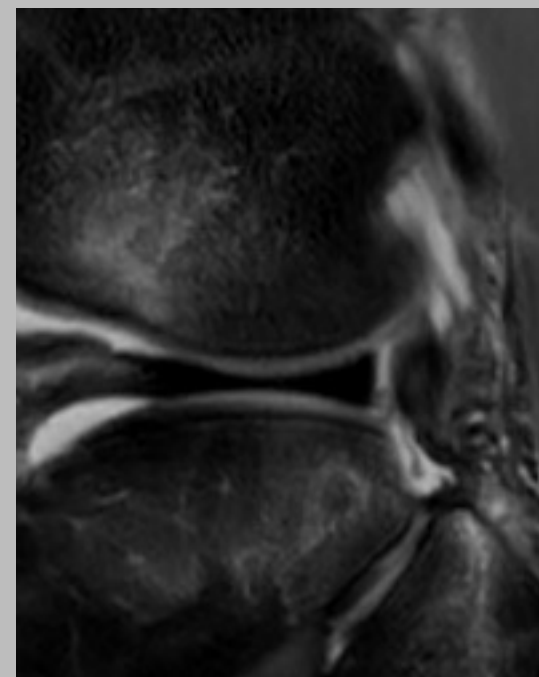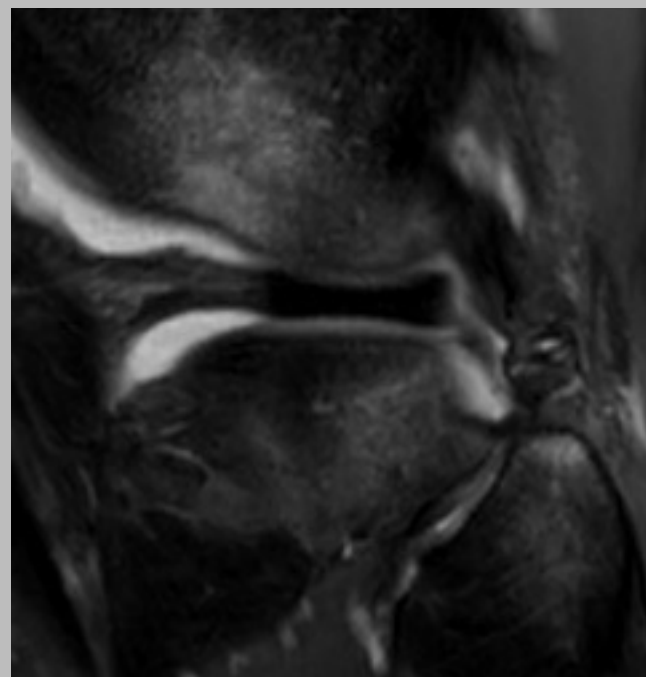
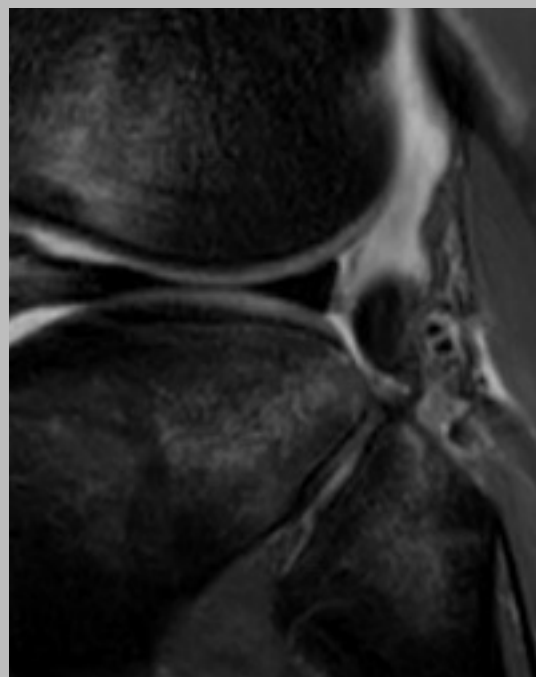
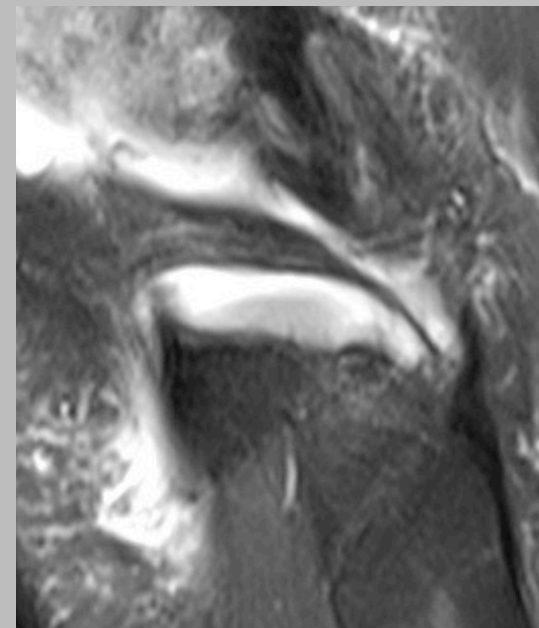
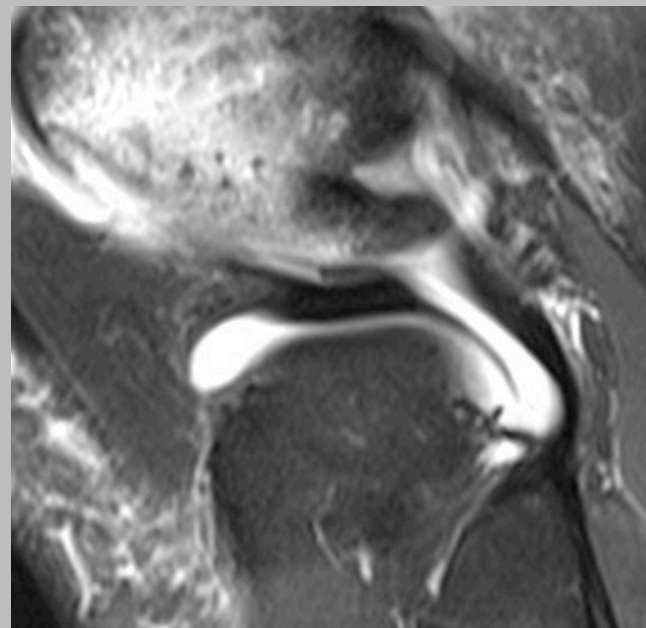
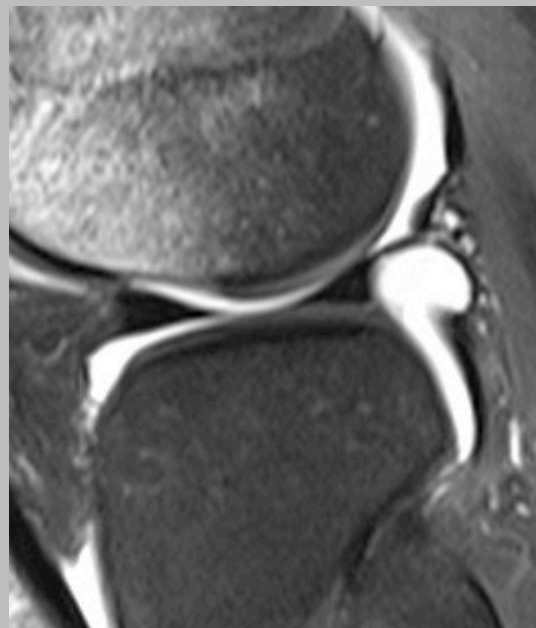
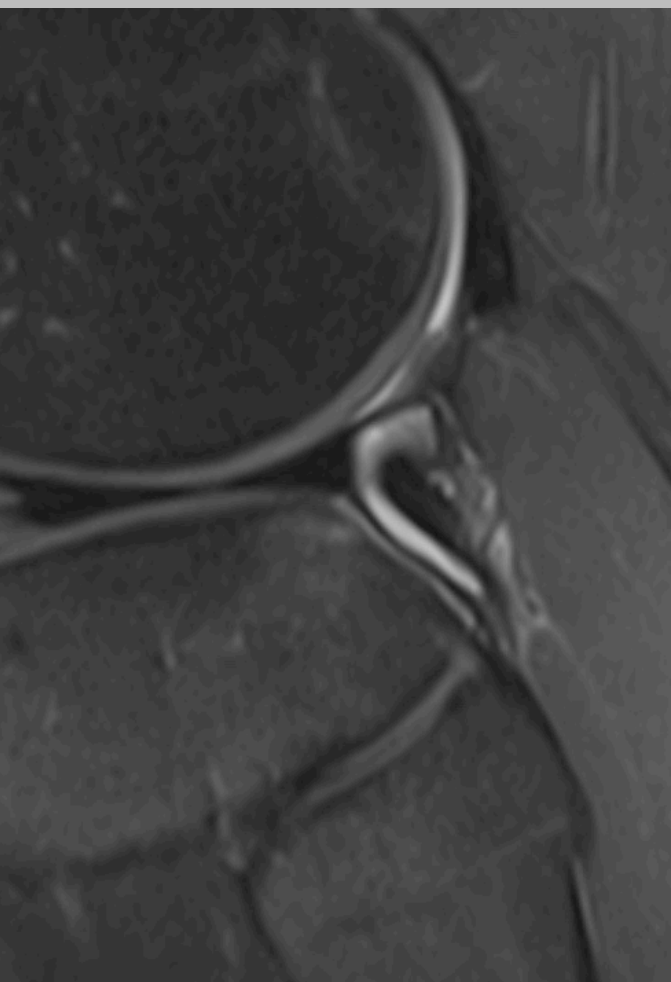


# Posterolaterla strukturer:

tractus Iliotibialis, LCL, popliteus, gastrocnemius



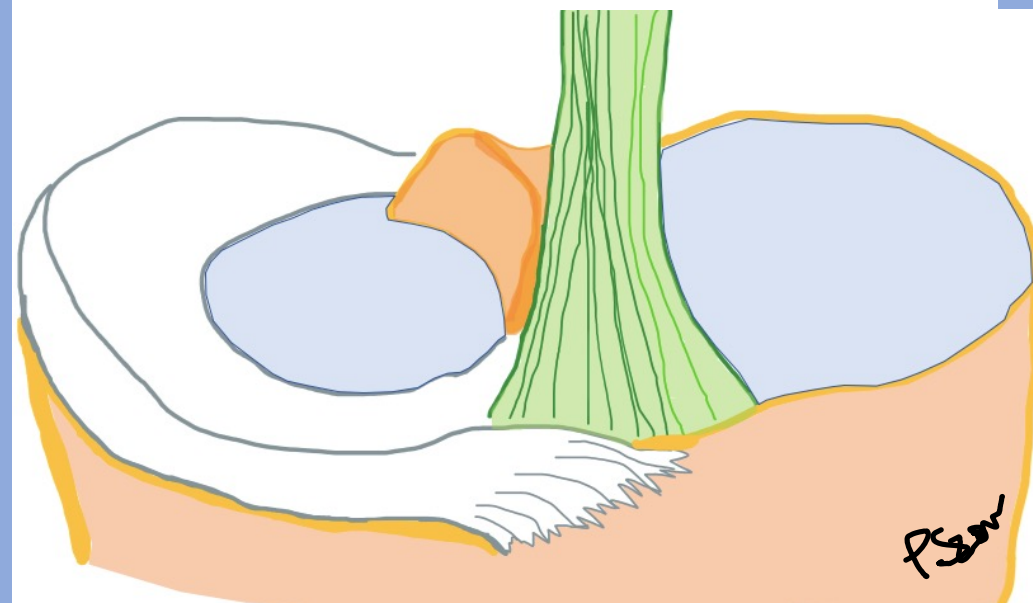
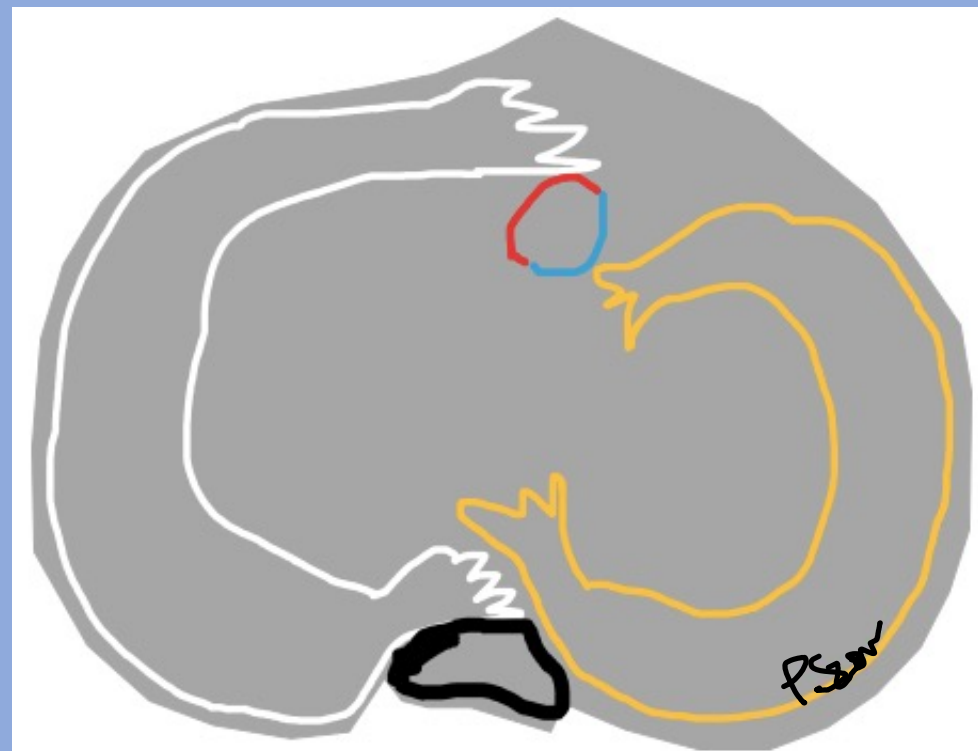
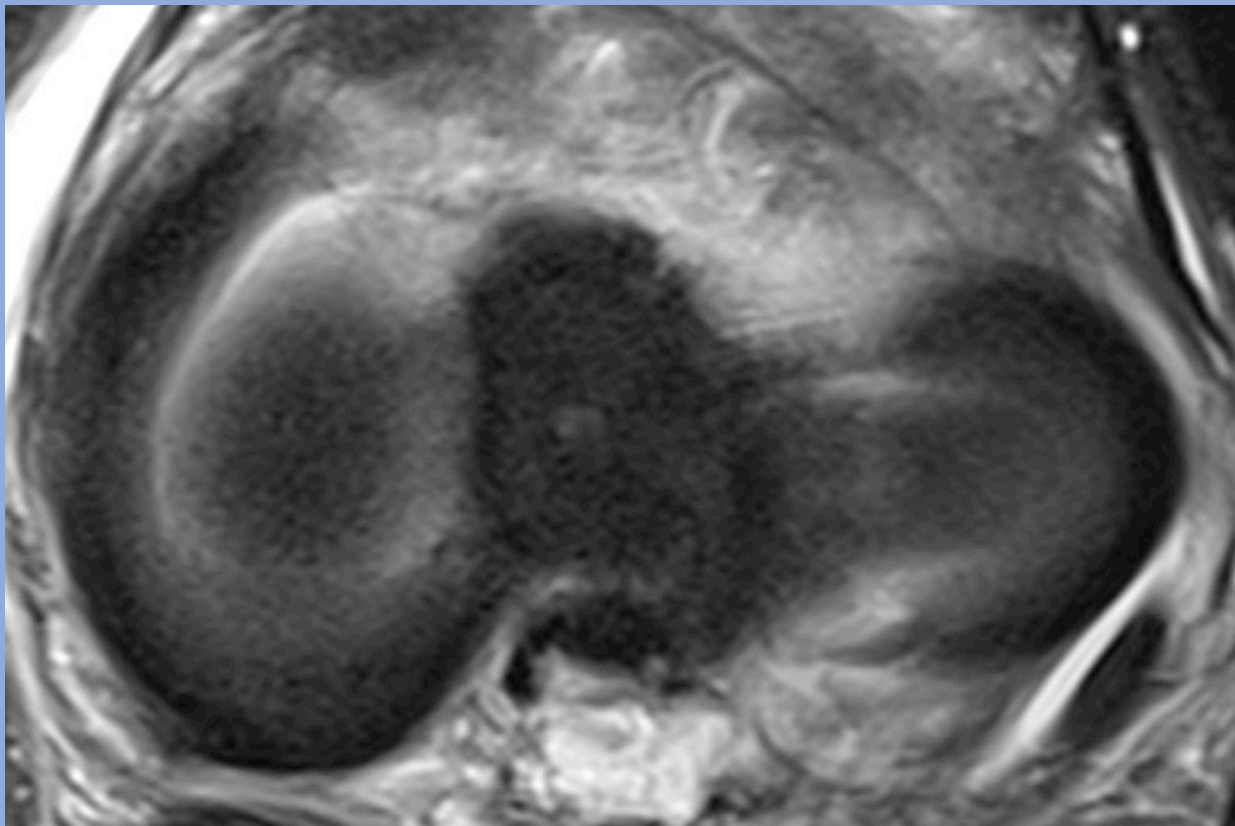
# Posterolaterala hörnet



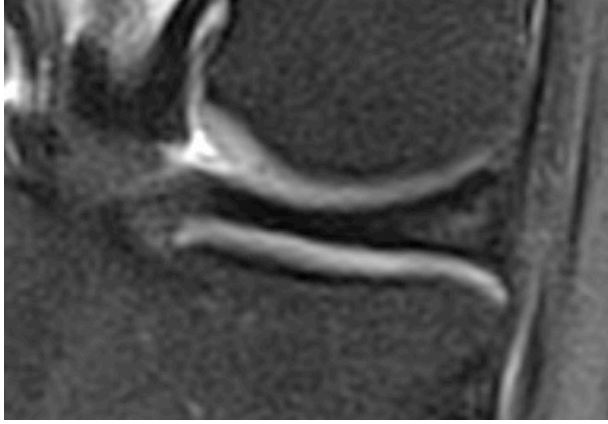
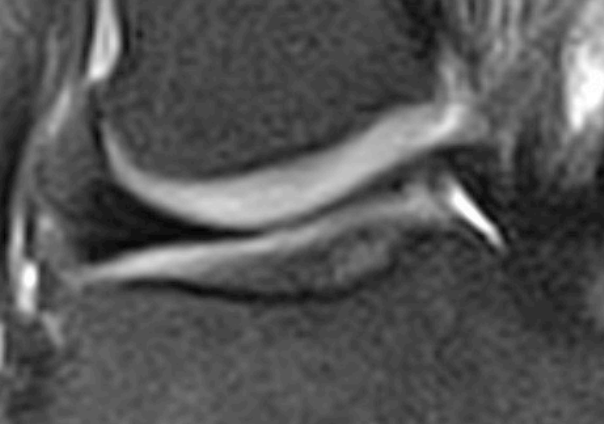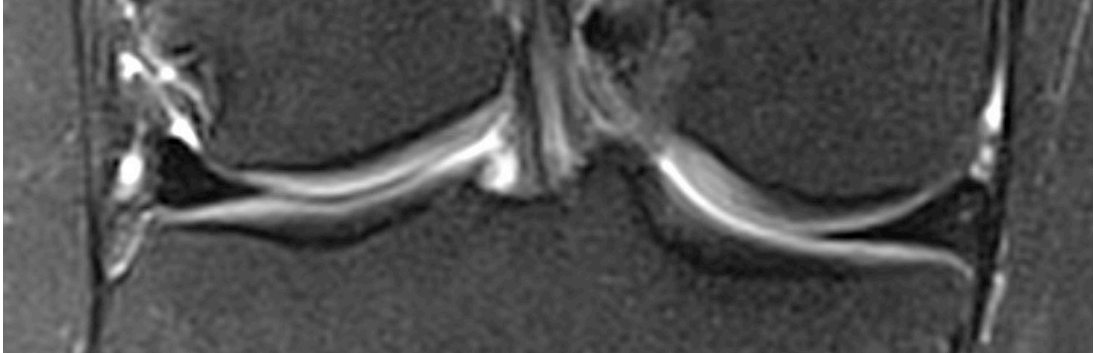
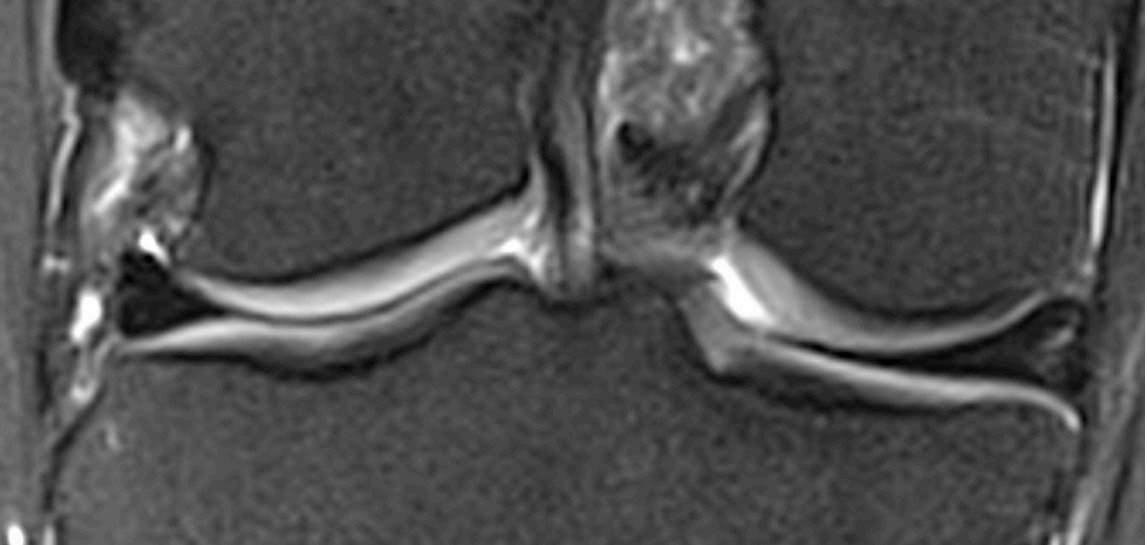
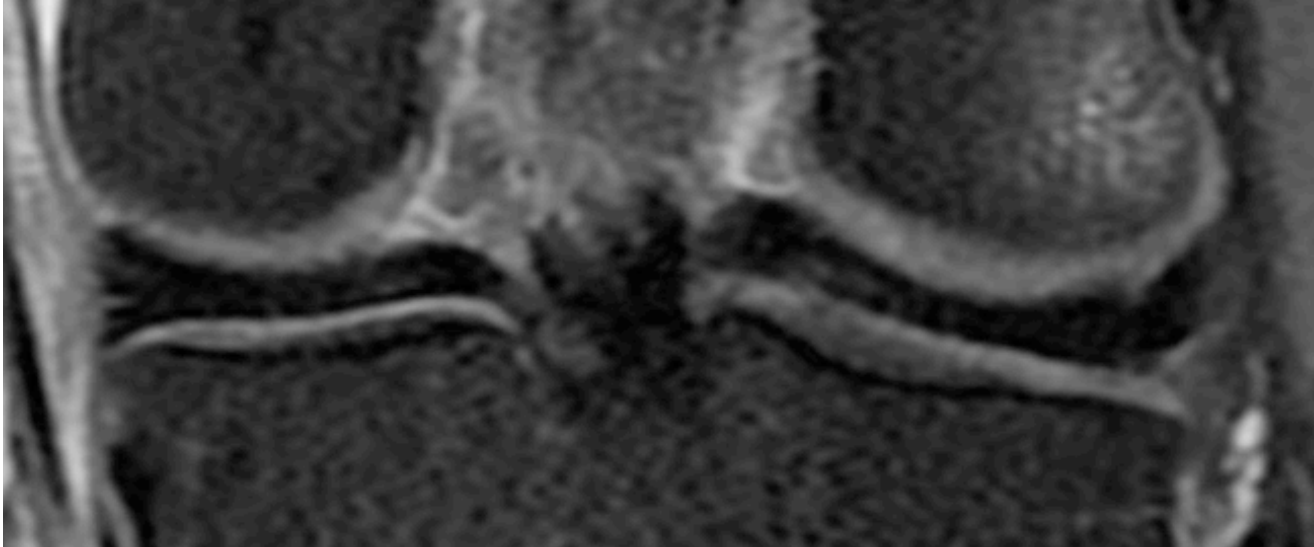
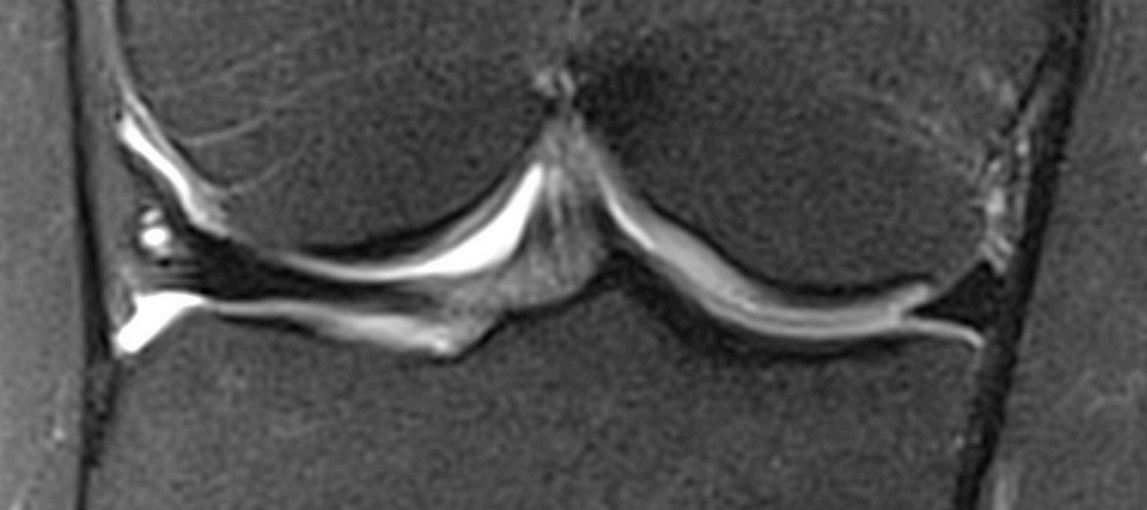


Menisker

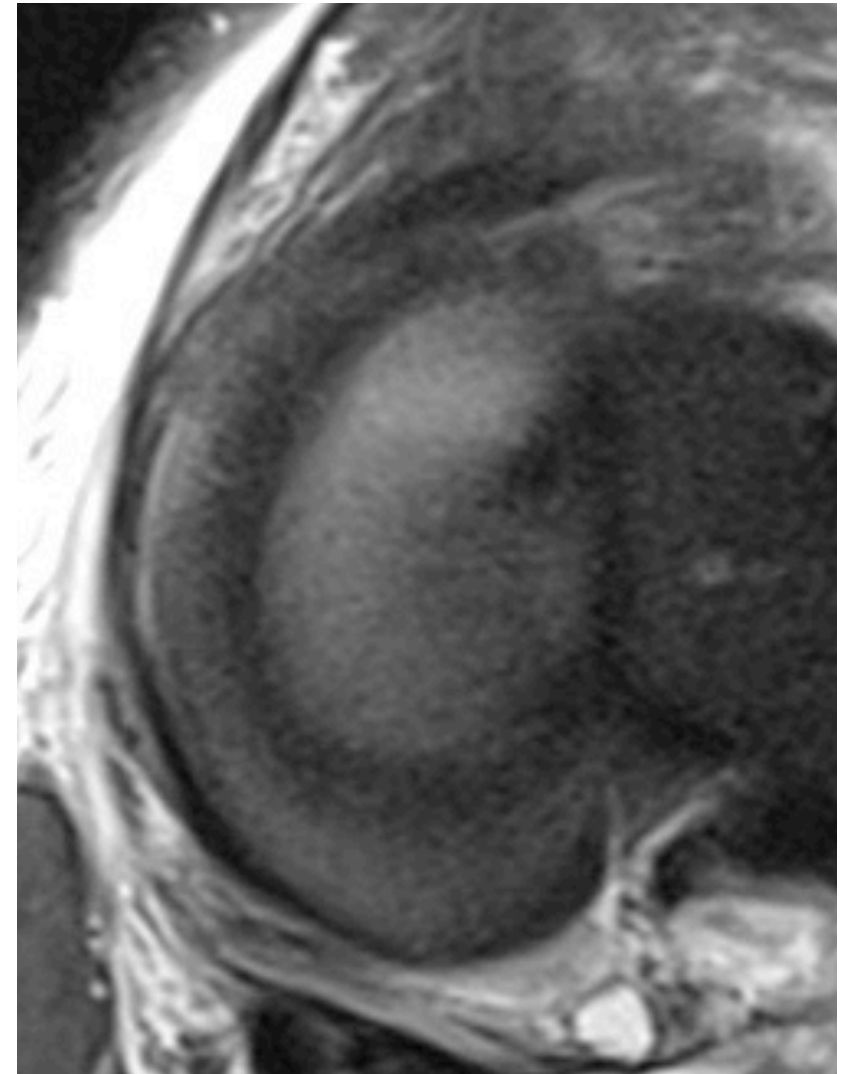
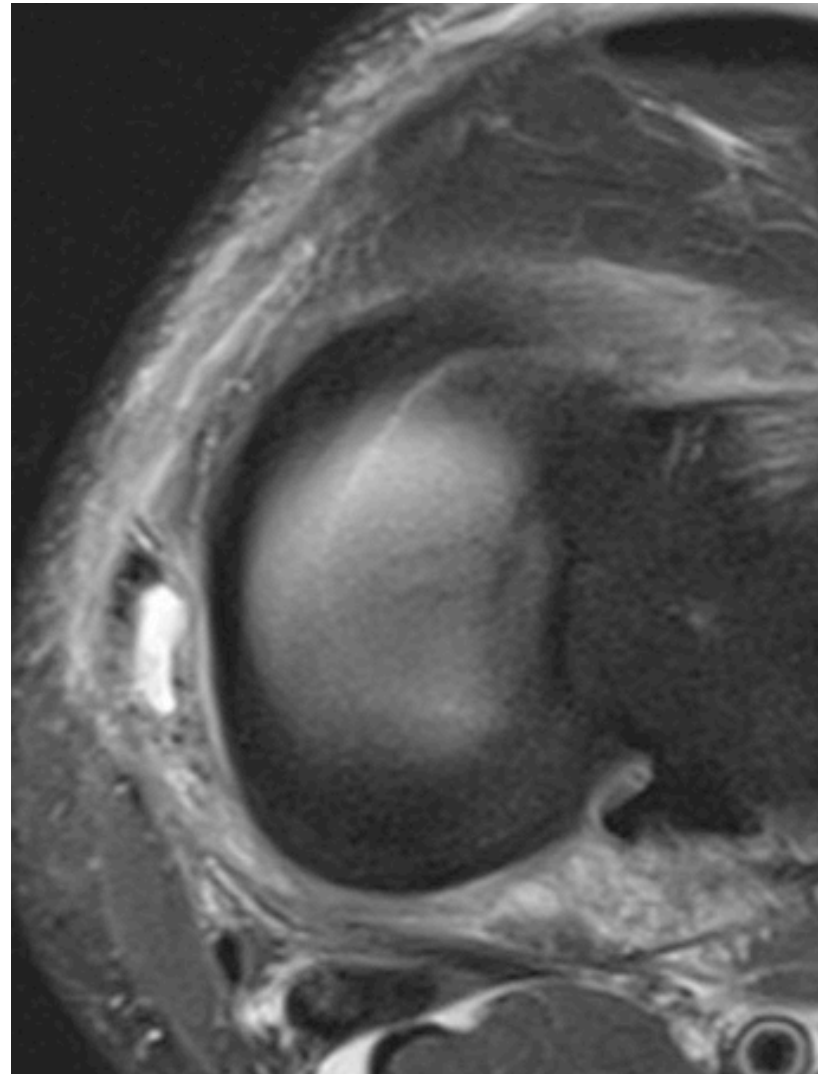
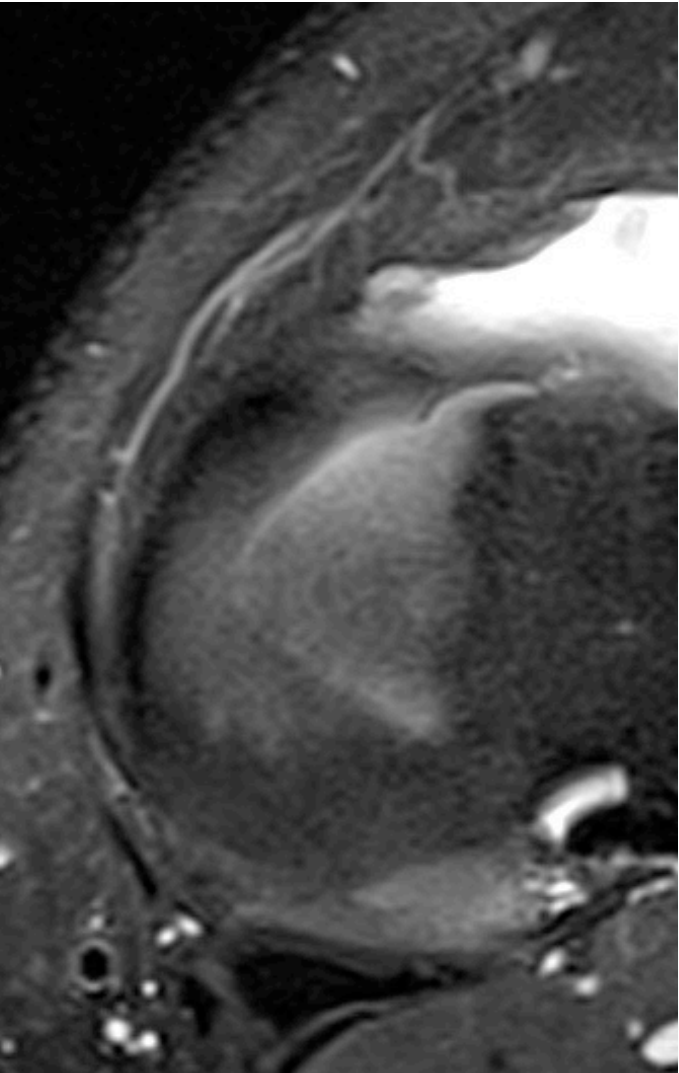
# Menisker - normala



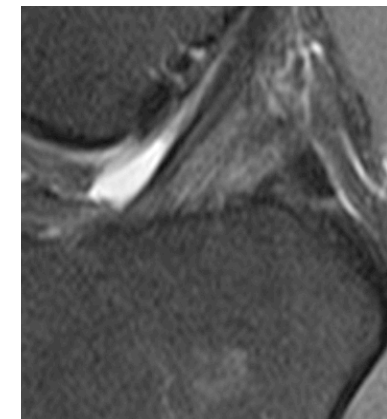
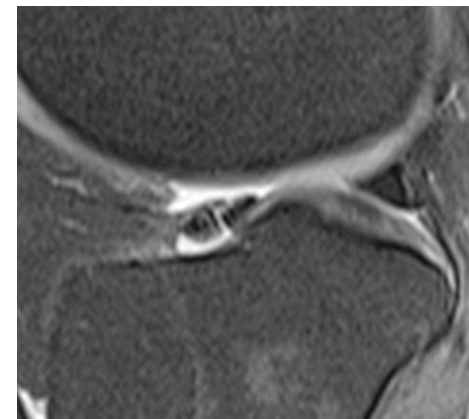
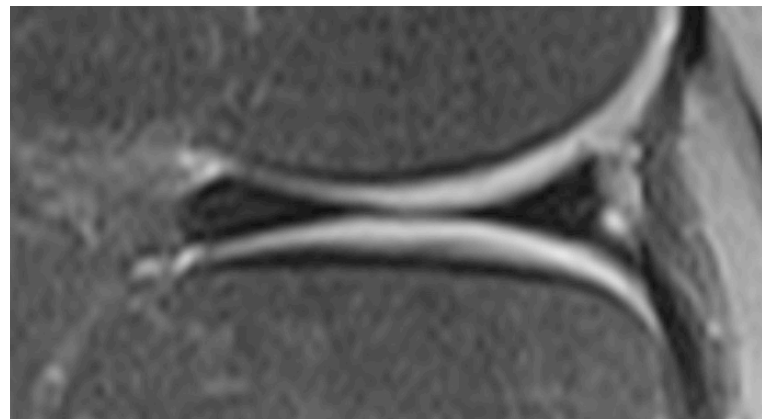
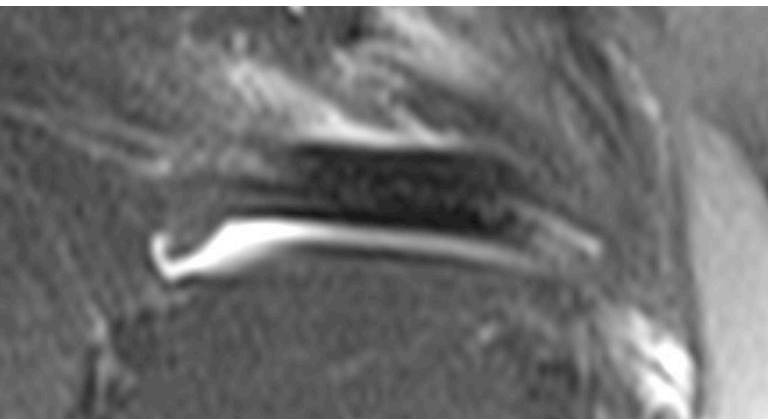
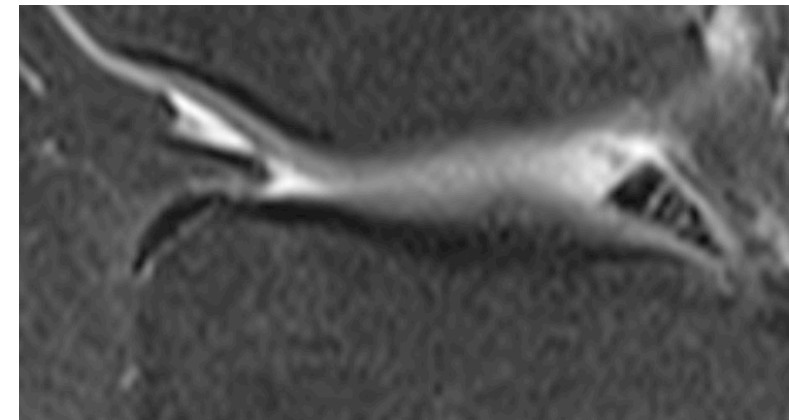
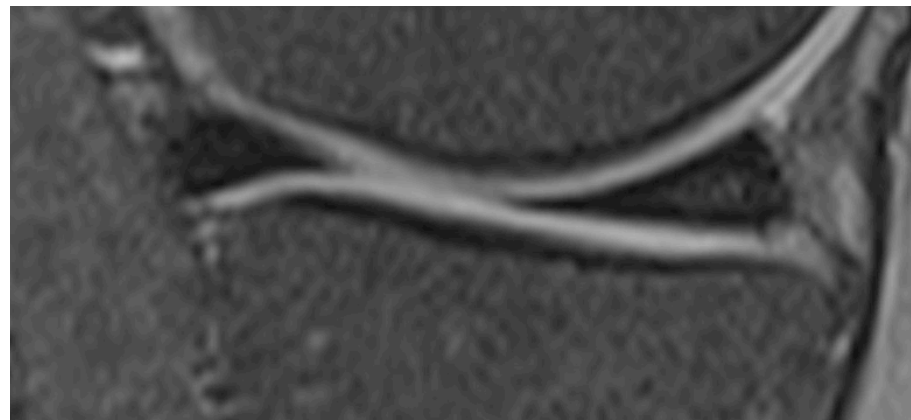
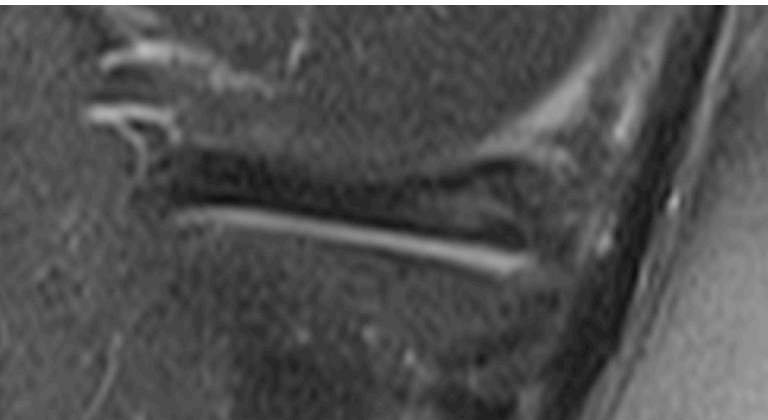
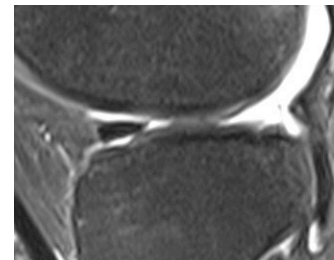
# Menisker



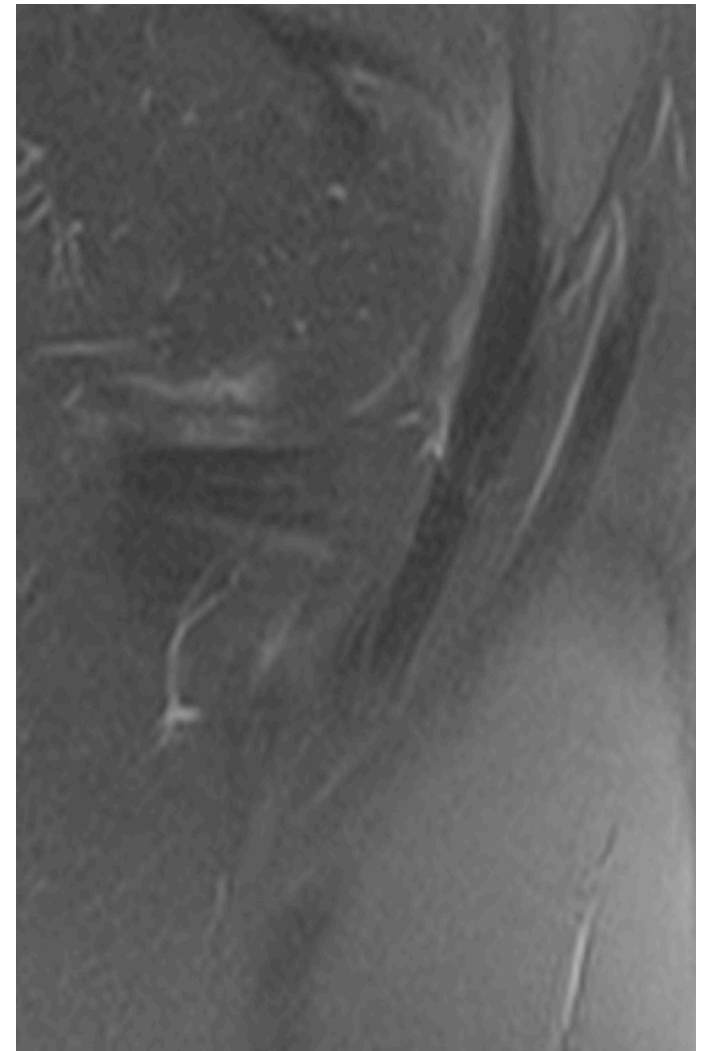
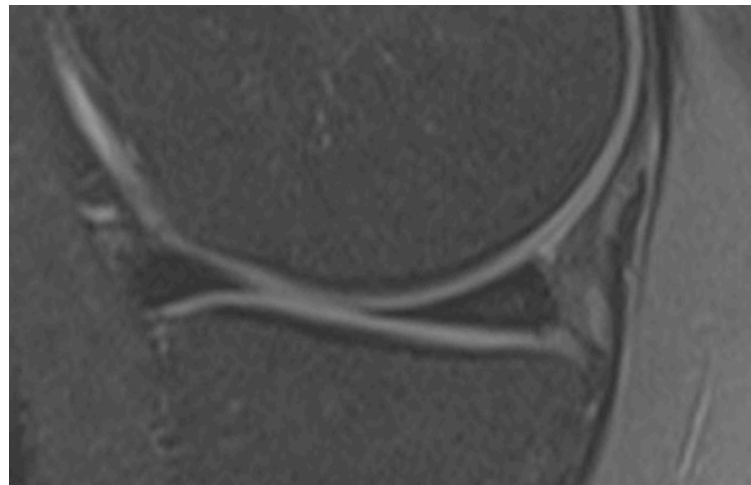
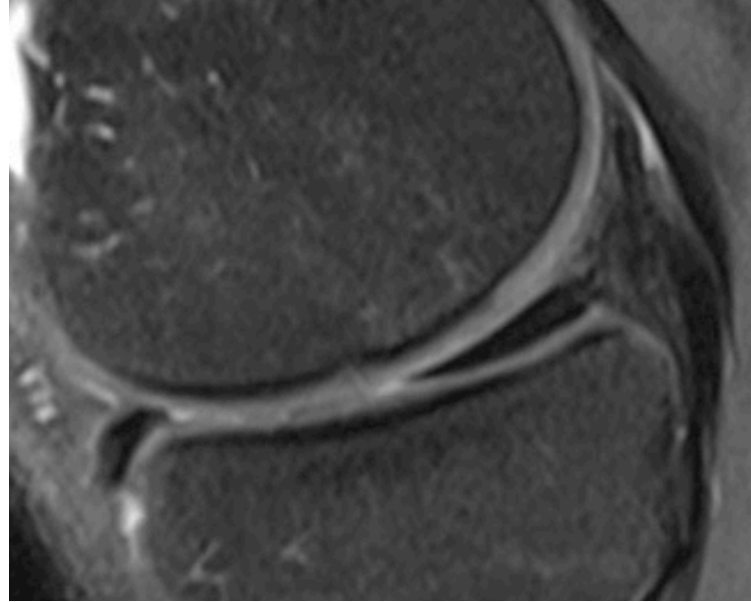
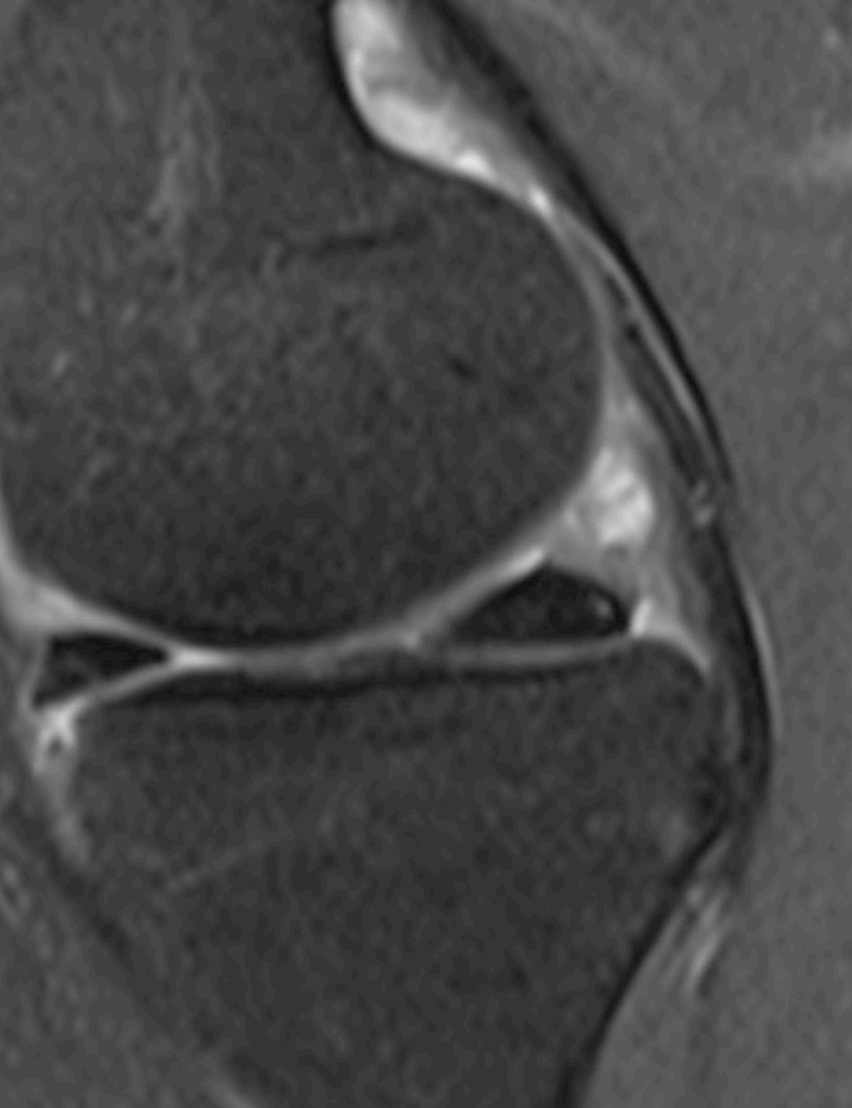
# Mediala menisken



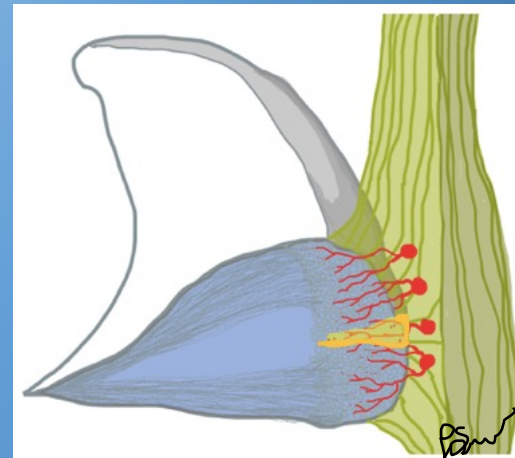
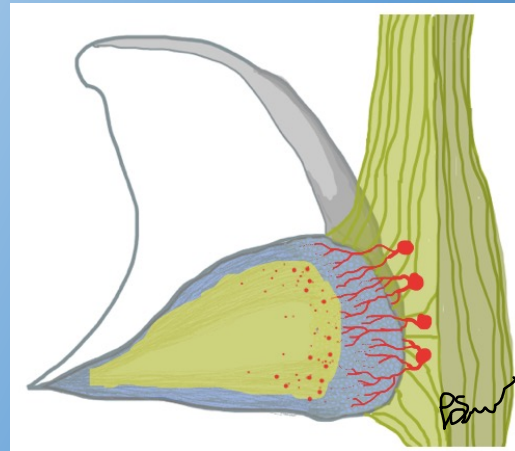
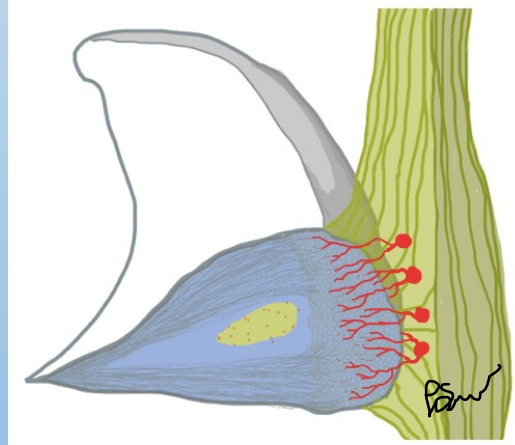
# Menisker



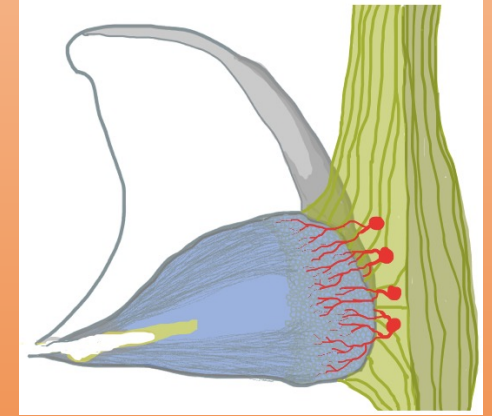
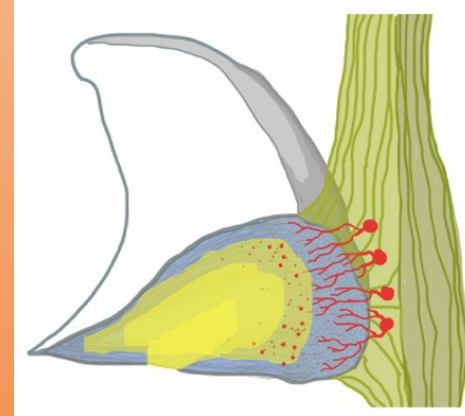
# Meniskokapsulär separation och posteromediala hörnet



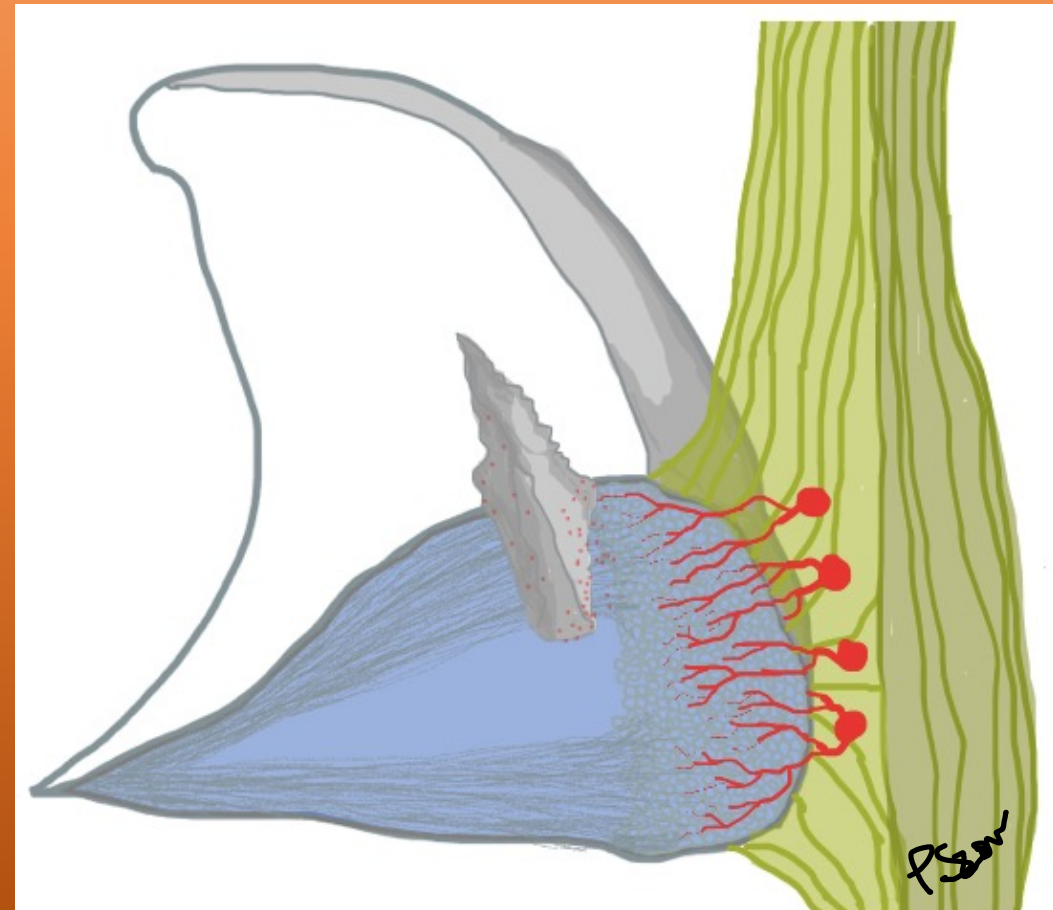
Diffdiagnos:  
Hög signal i  
menisk



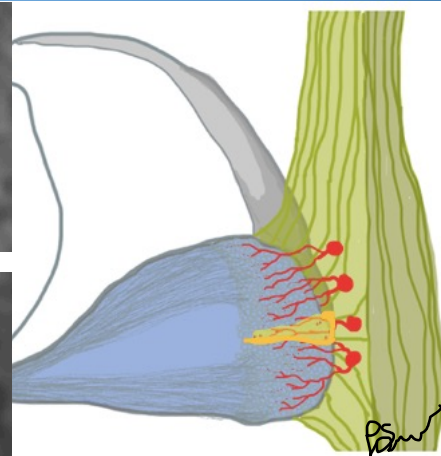
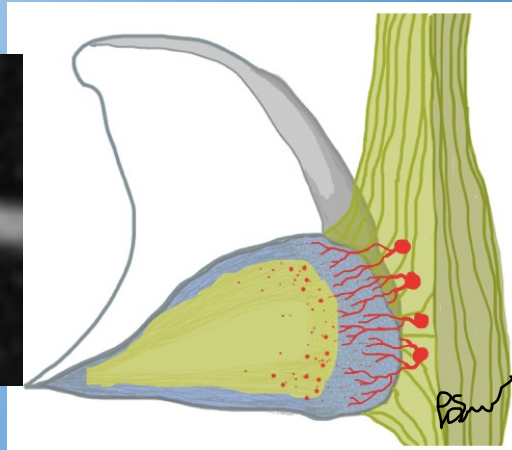
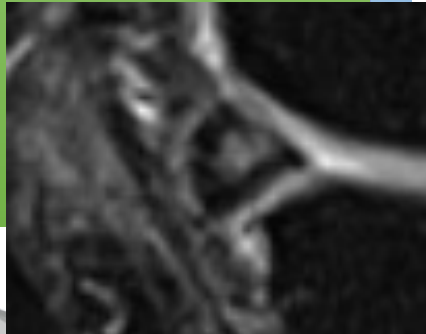
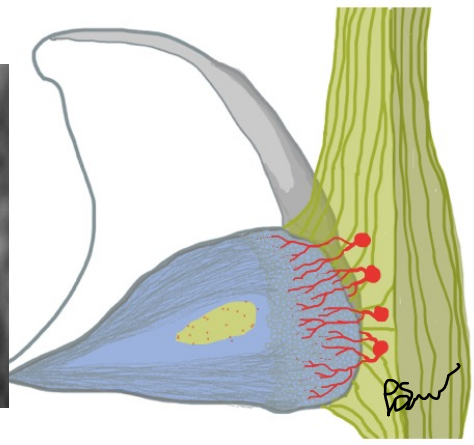
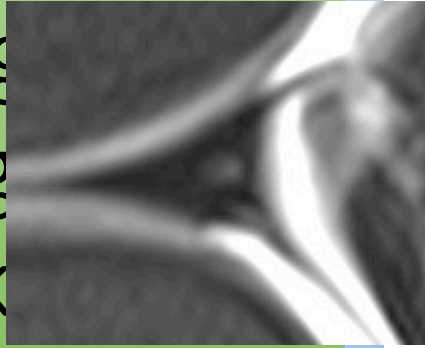
Normal  
kontur



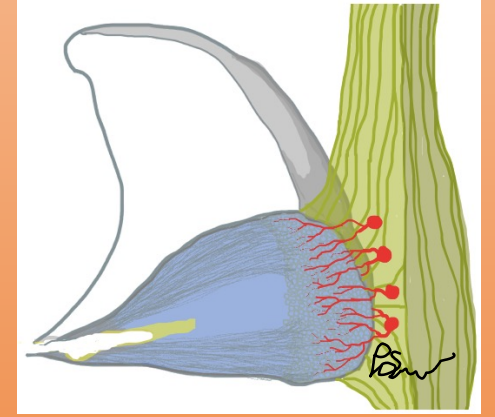
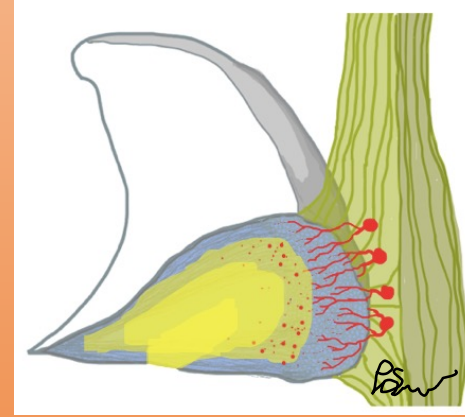
*Påverkad kontur*



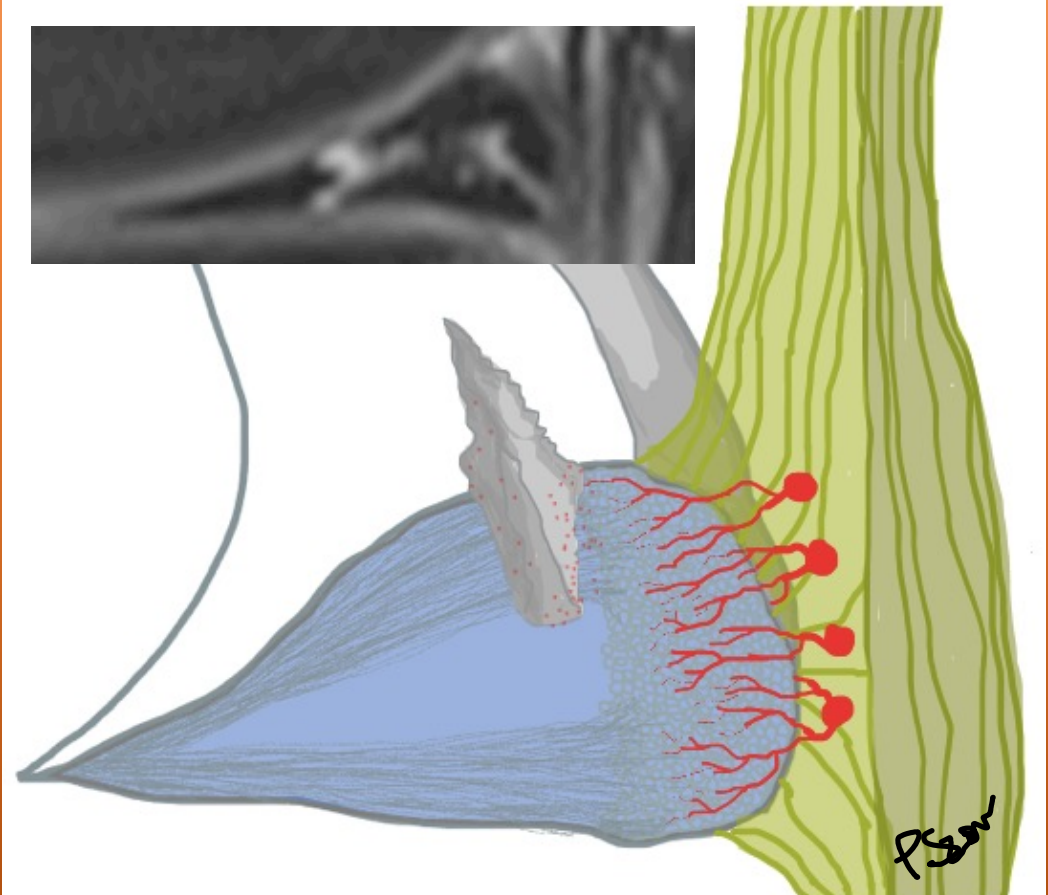
Diffdiag  
Hög sig  
menisk



Normal kontur

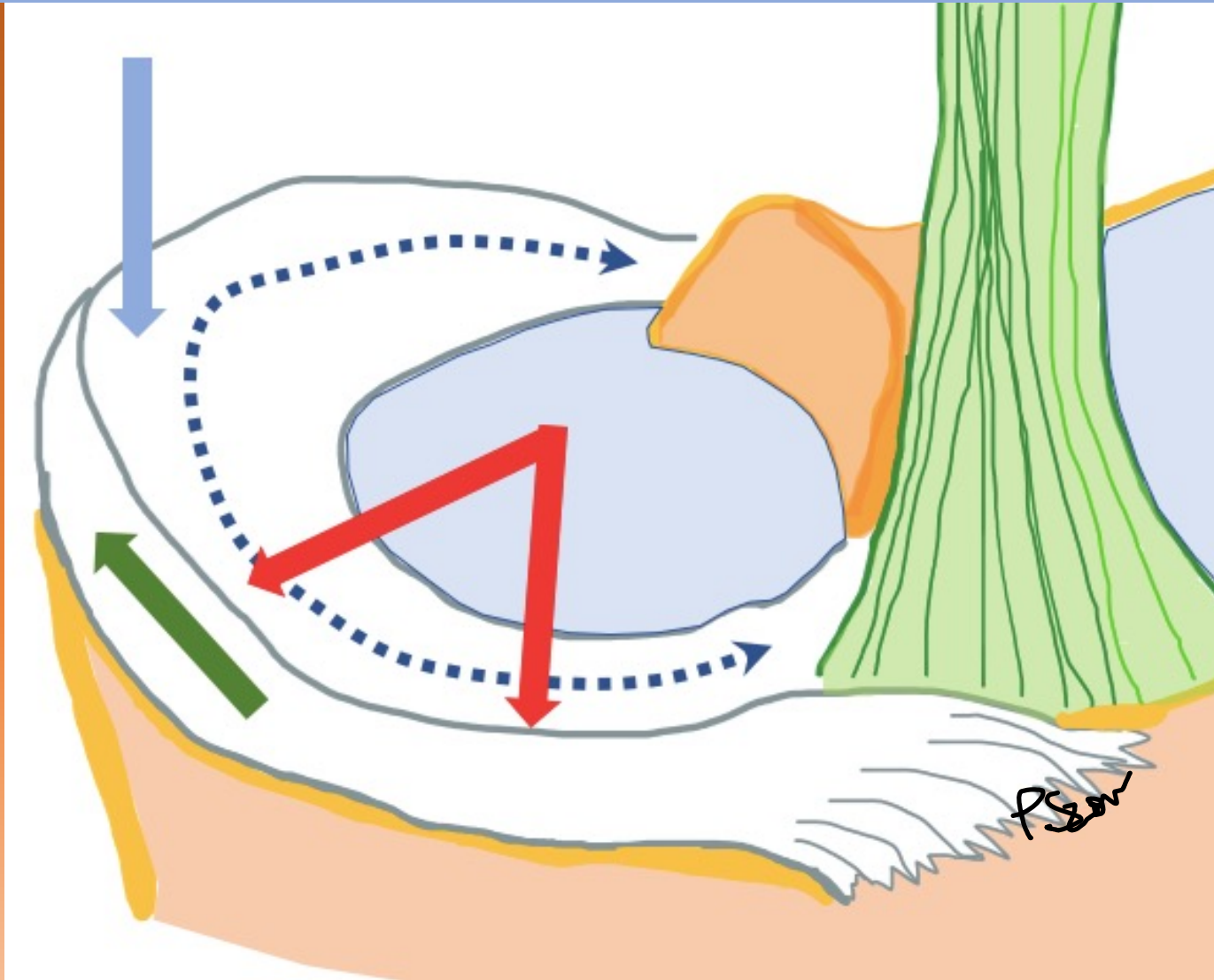


Påverkad kontur





# Meniskrupturer

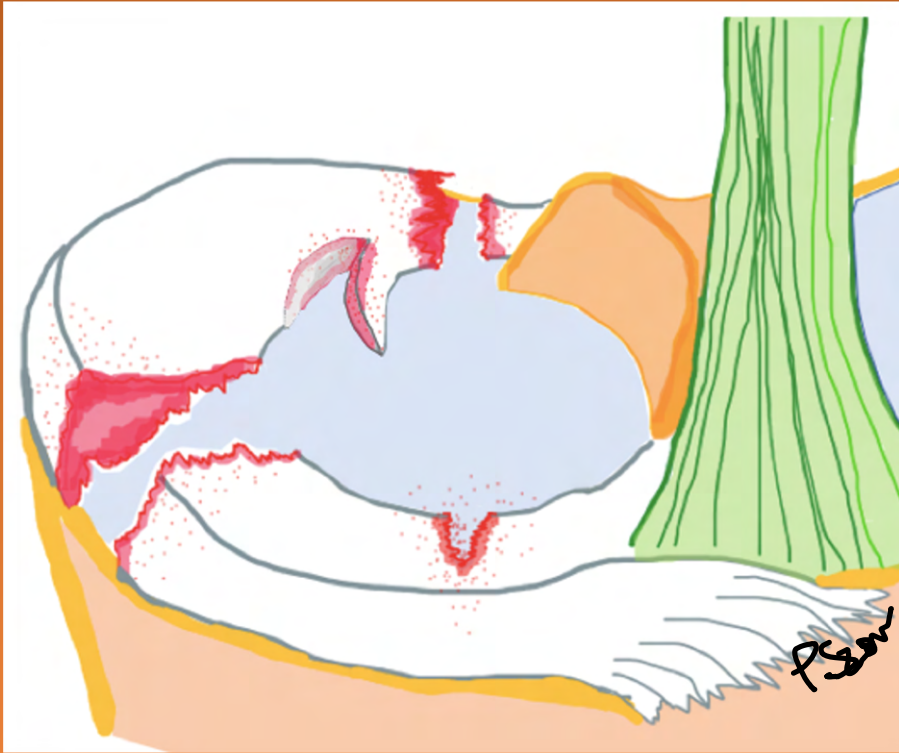

Radiella rupturer

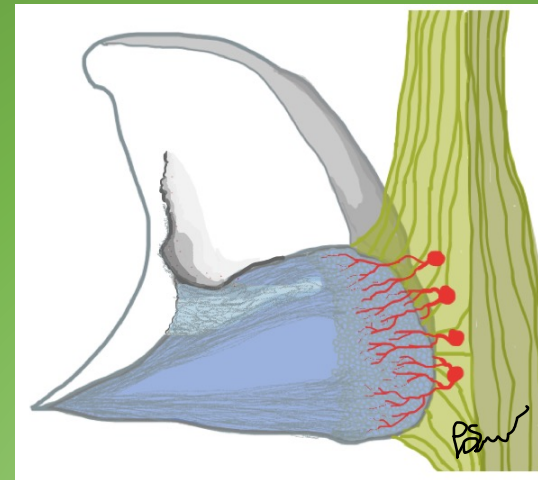
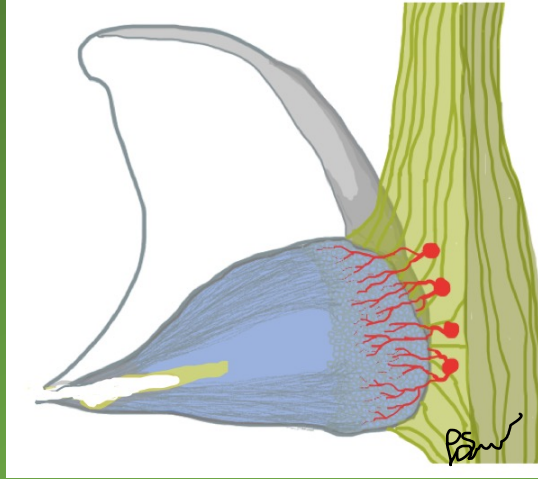
Horisontala rupturer

Vertikala rupturer

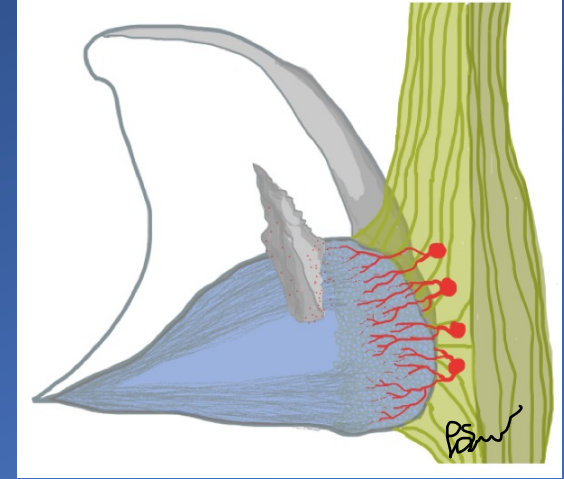
# Meniskrupturer



Radiella rupturer

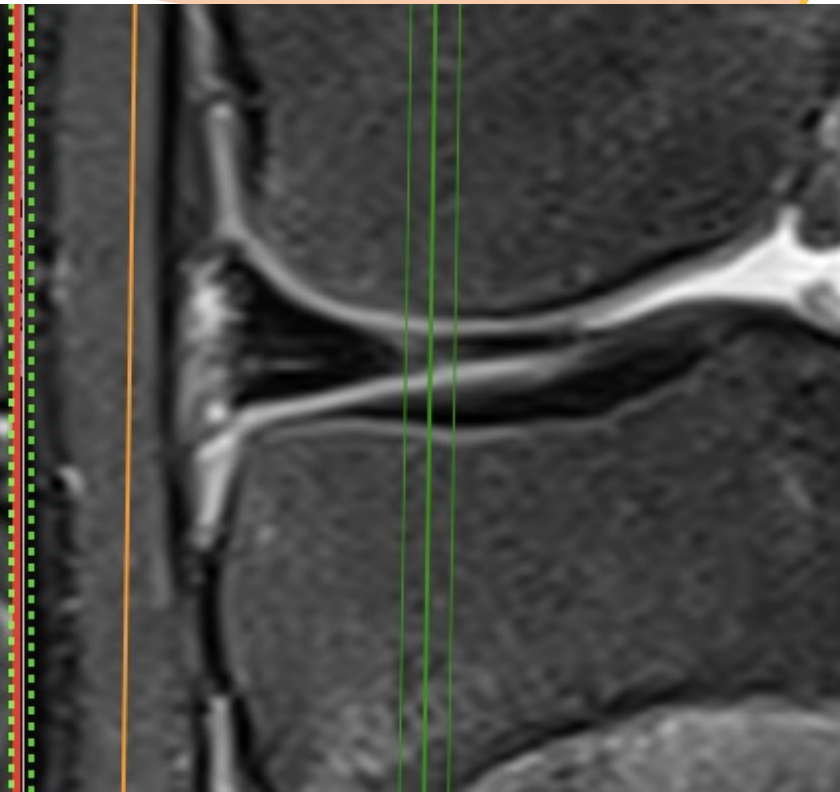
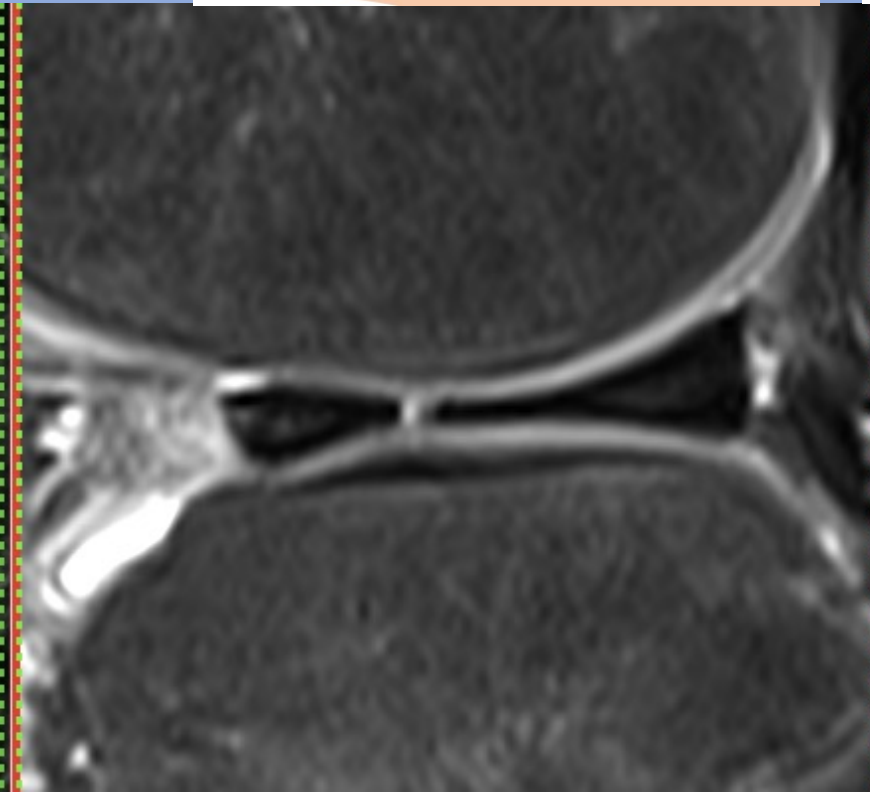
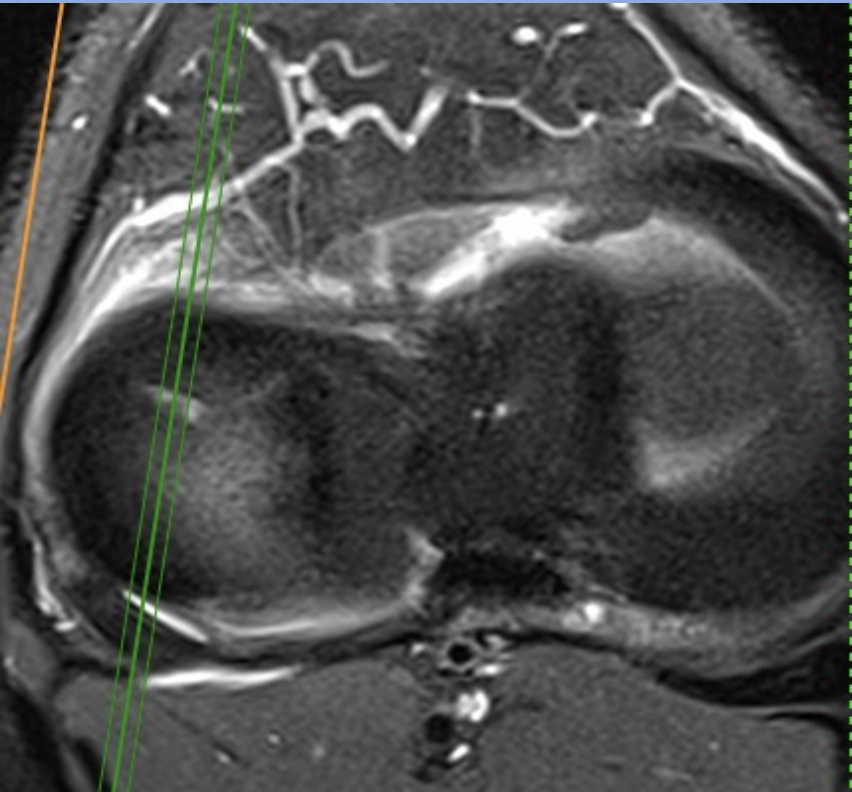
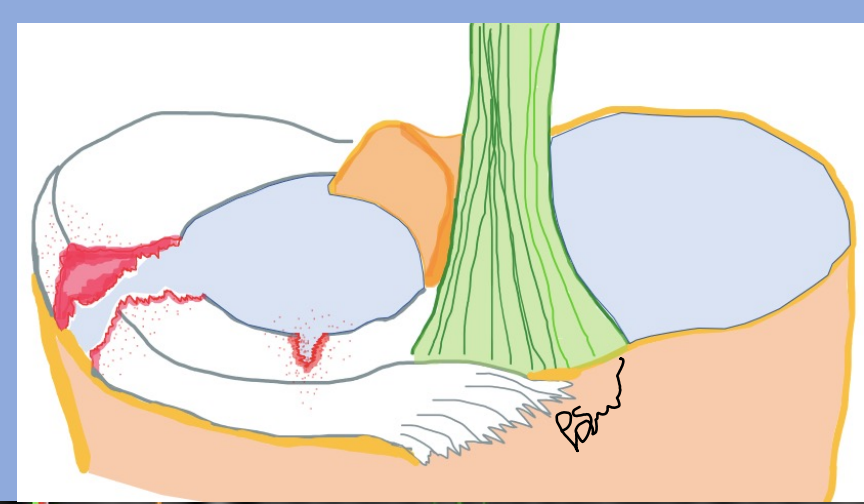
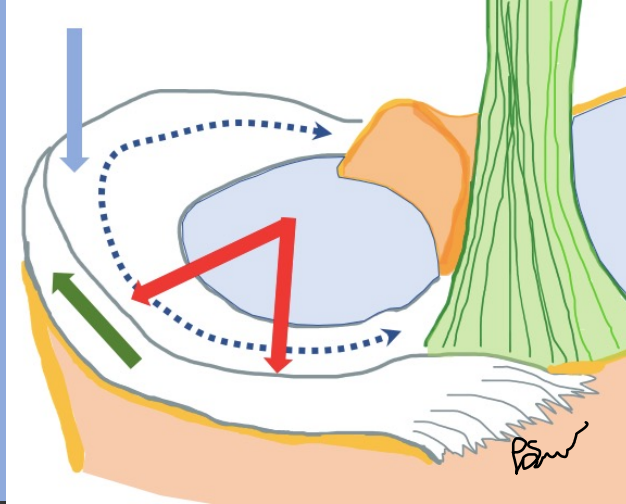


Horisontala rupturer

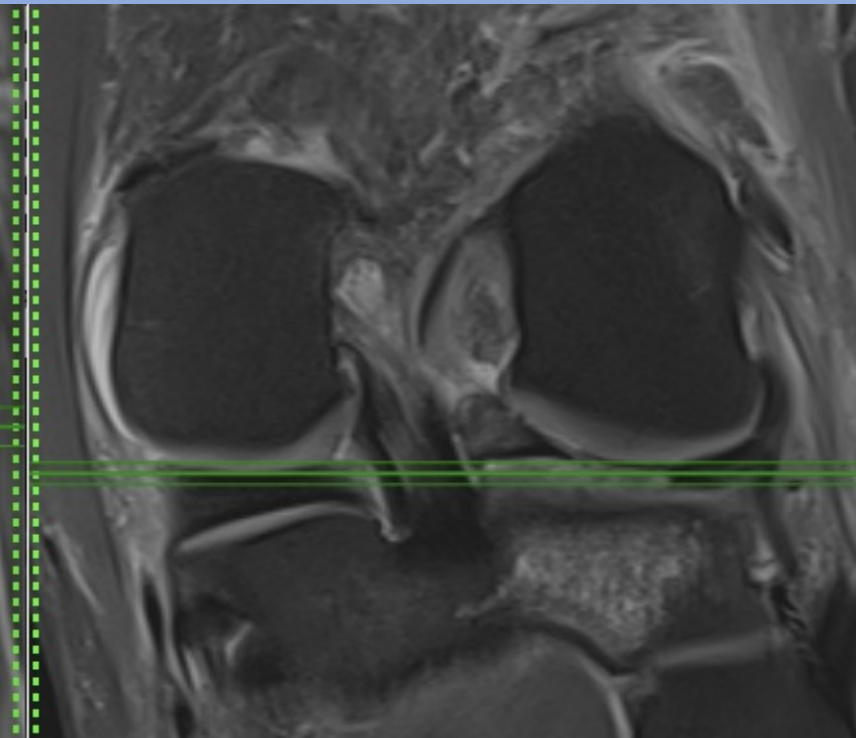
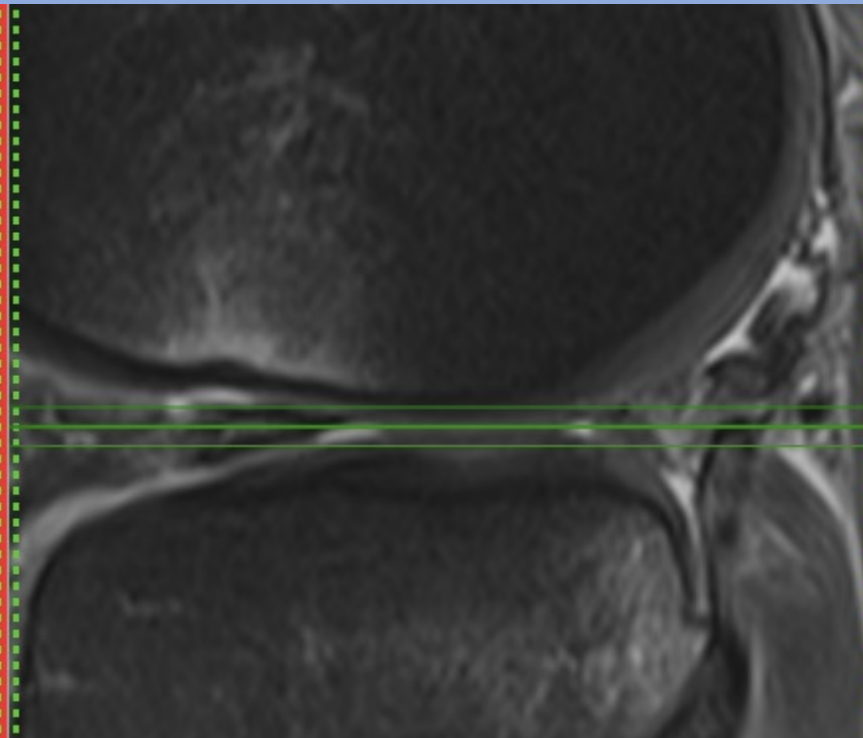
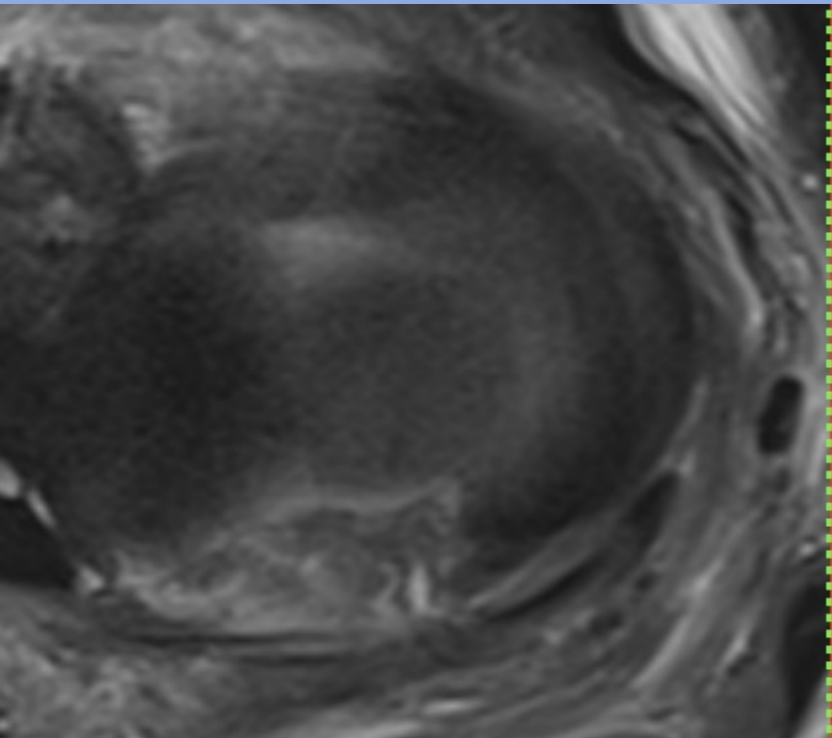
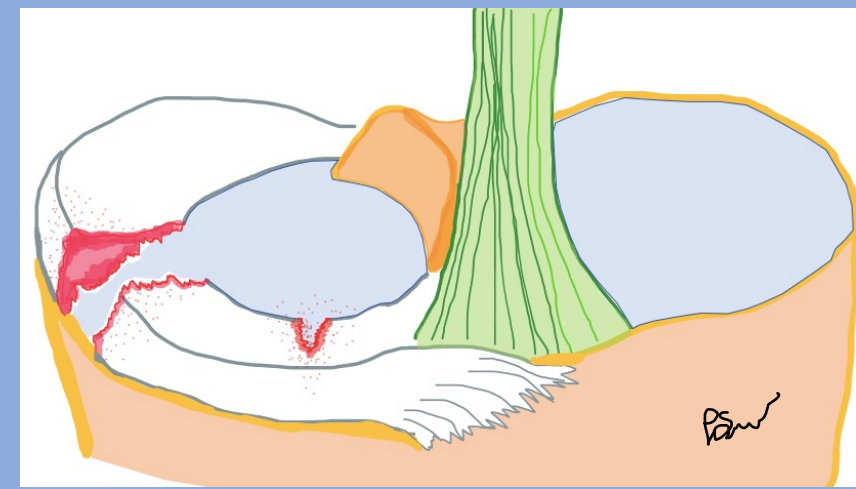


Vertikala rupturer

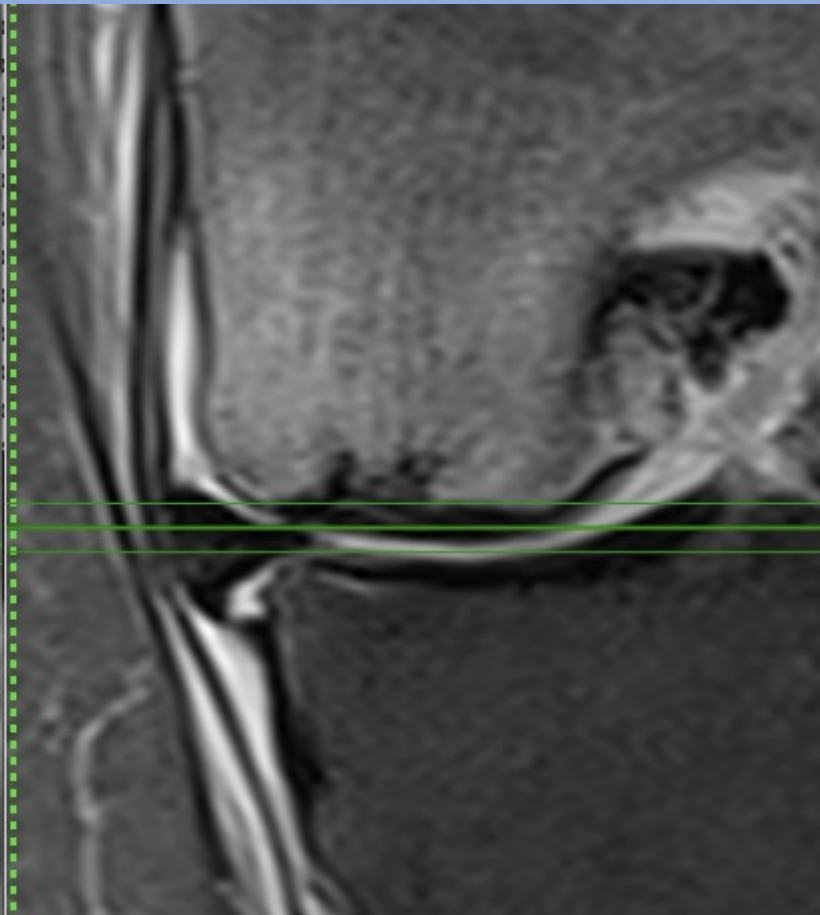
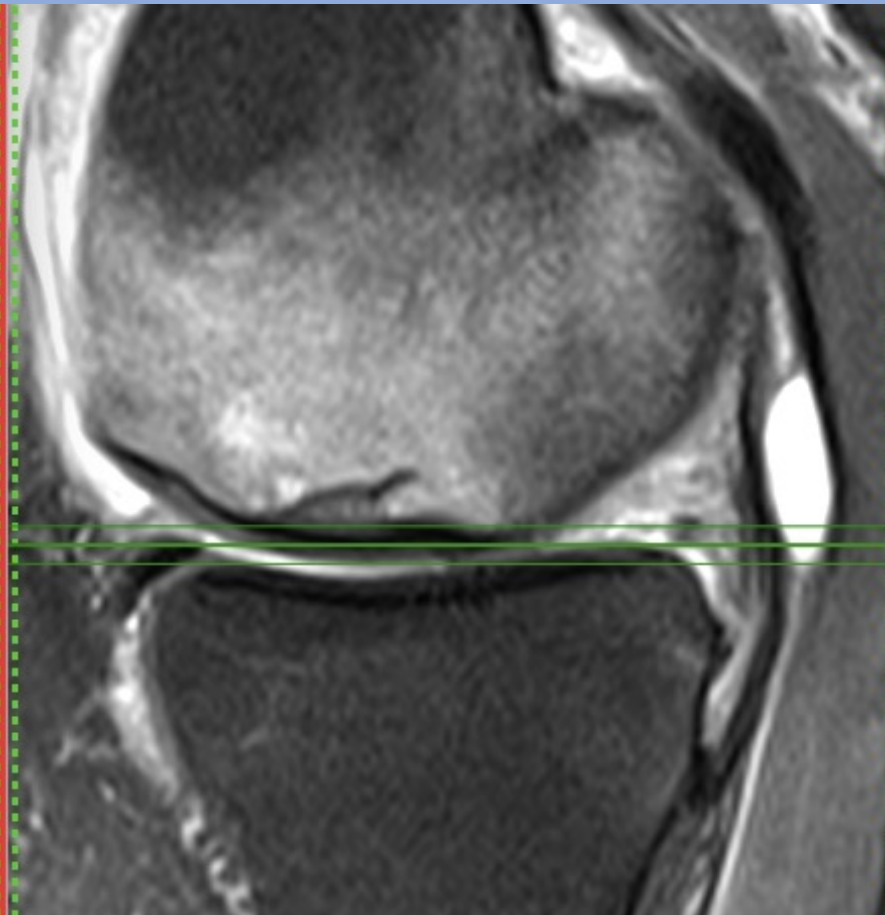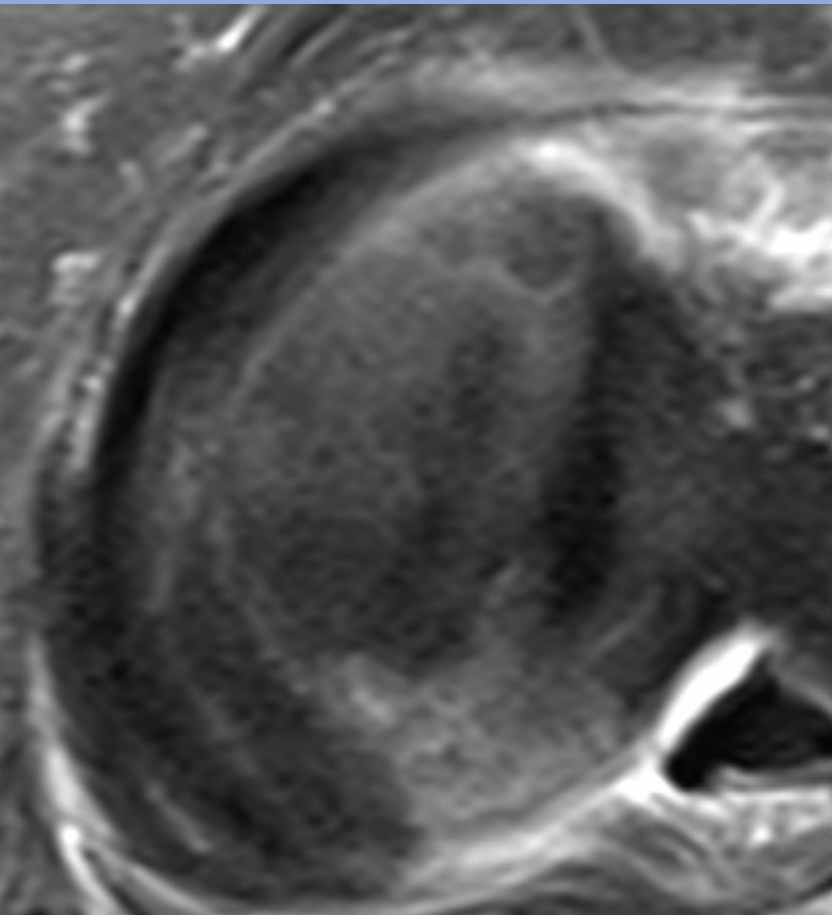
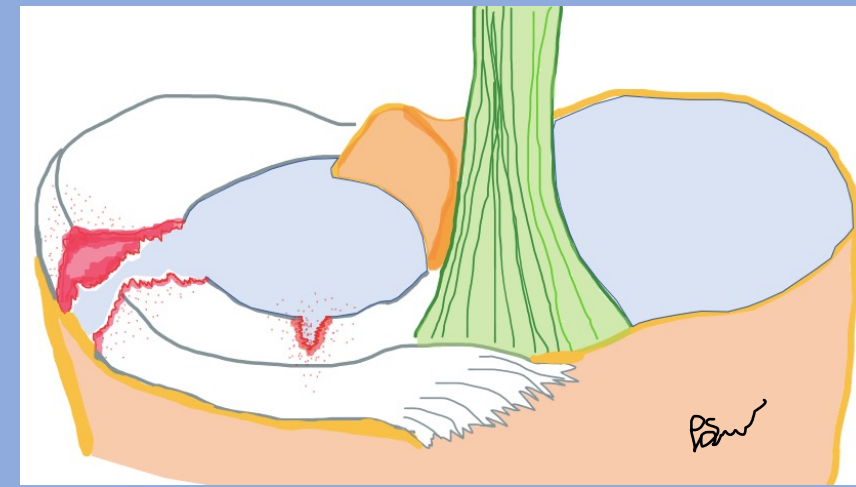
# Radiell ruptur



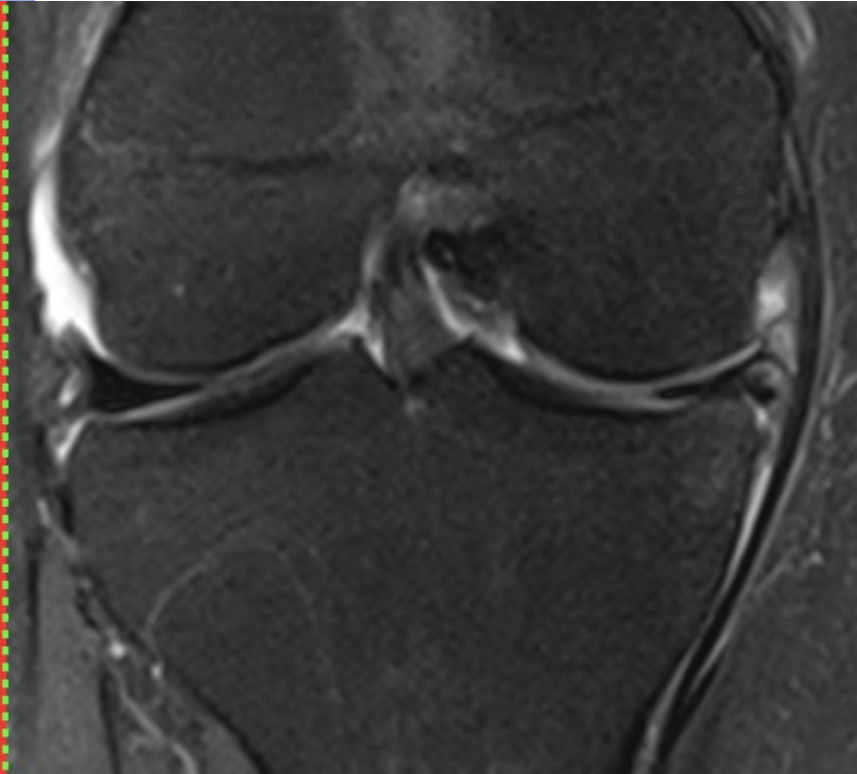
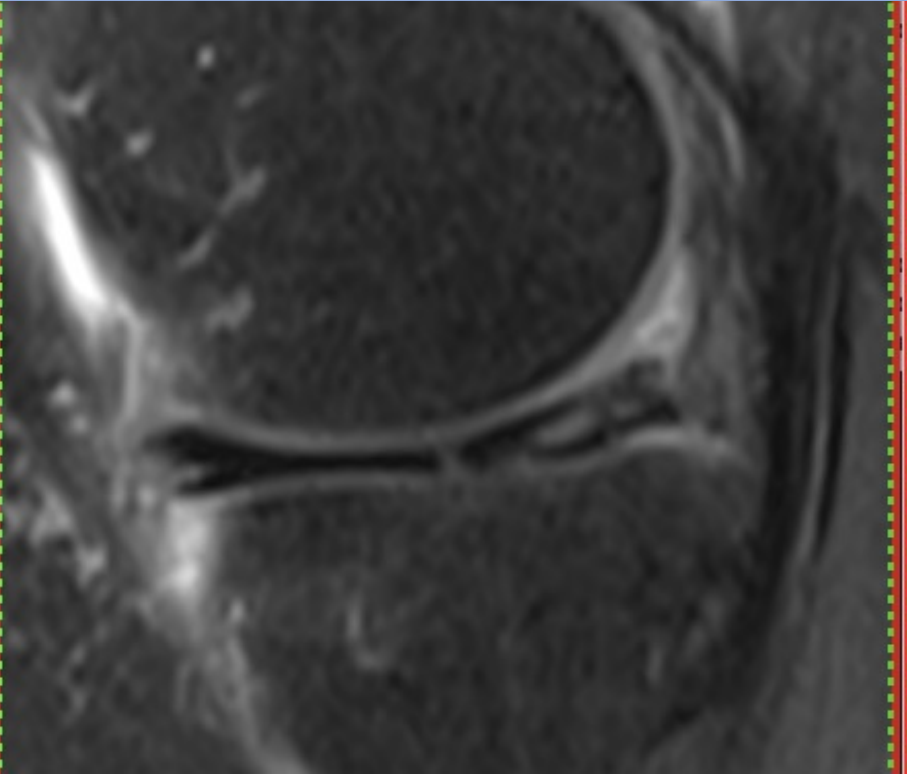
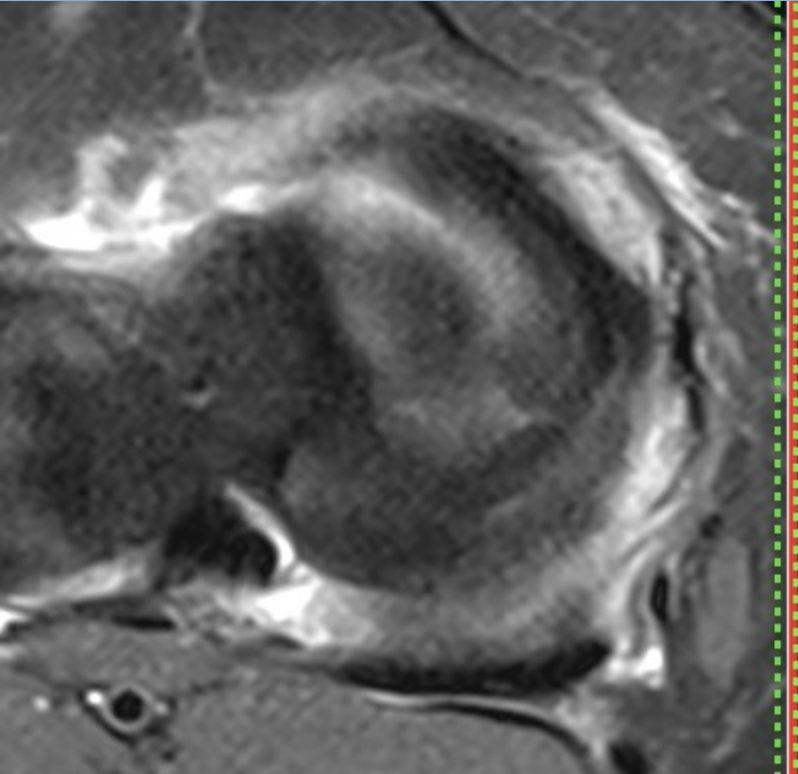
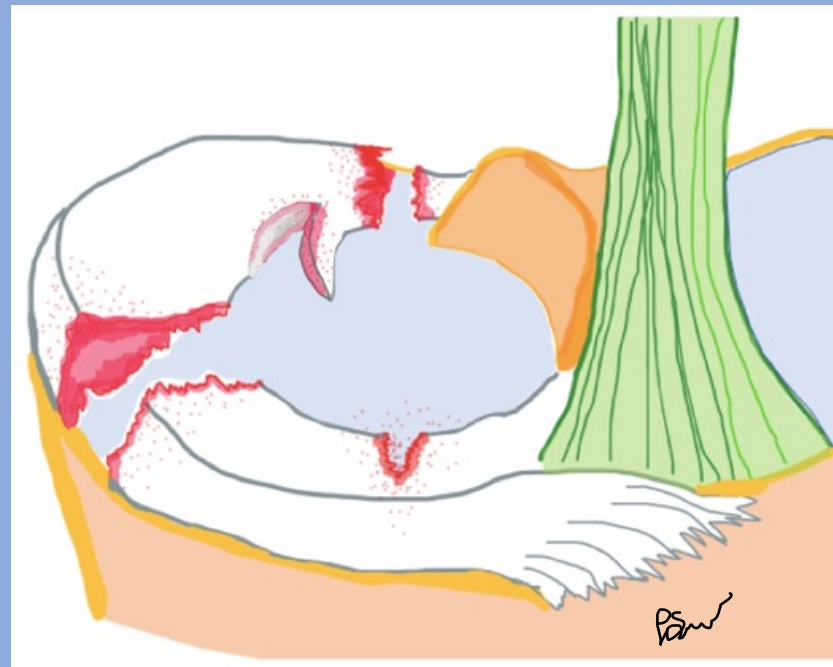
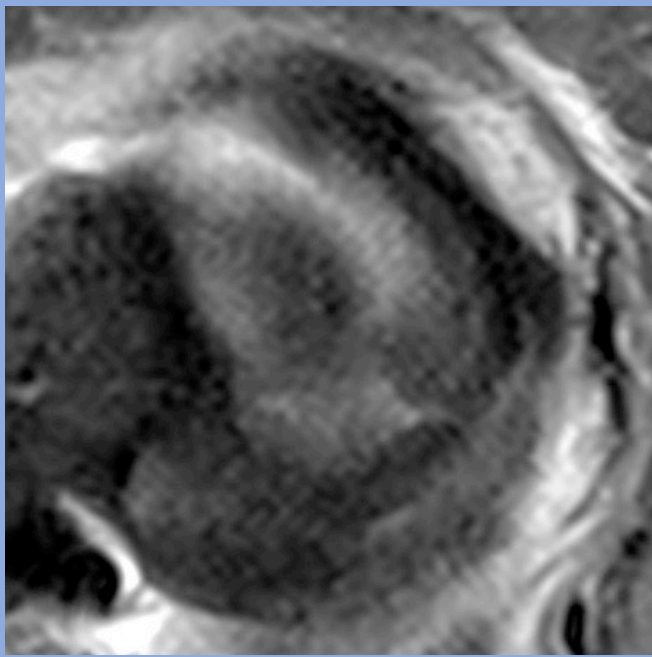
# Radiell ruptur genomgående



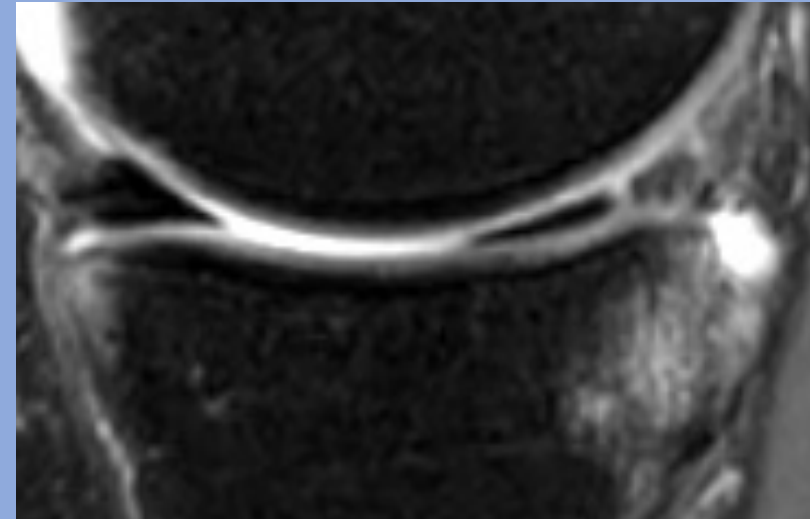
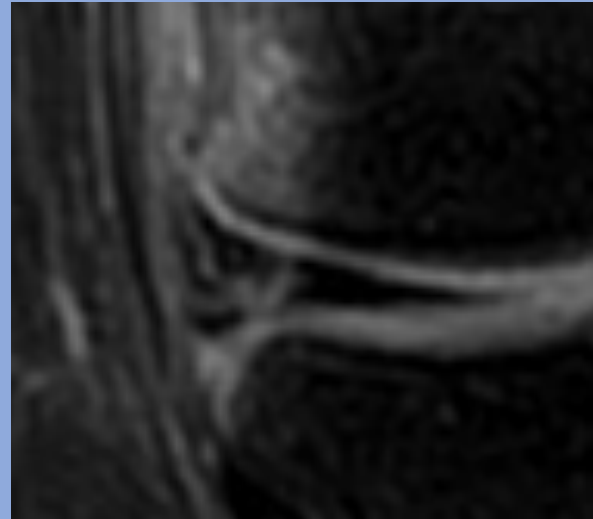
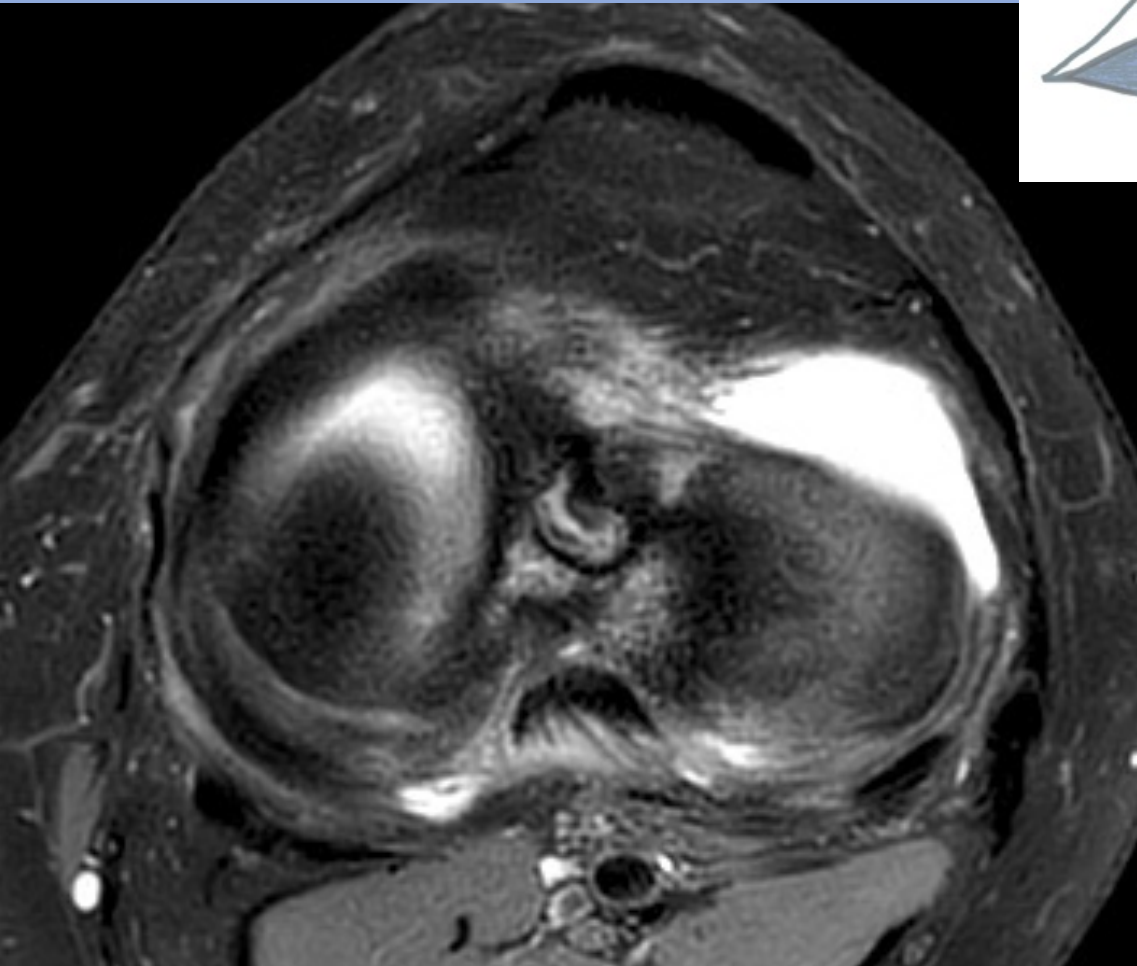
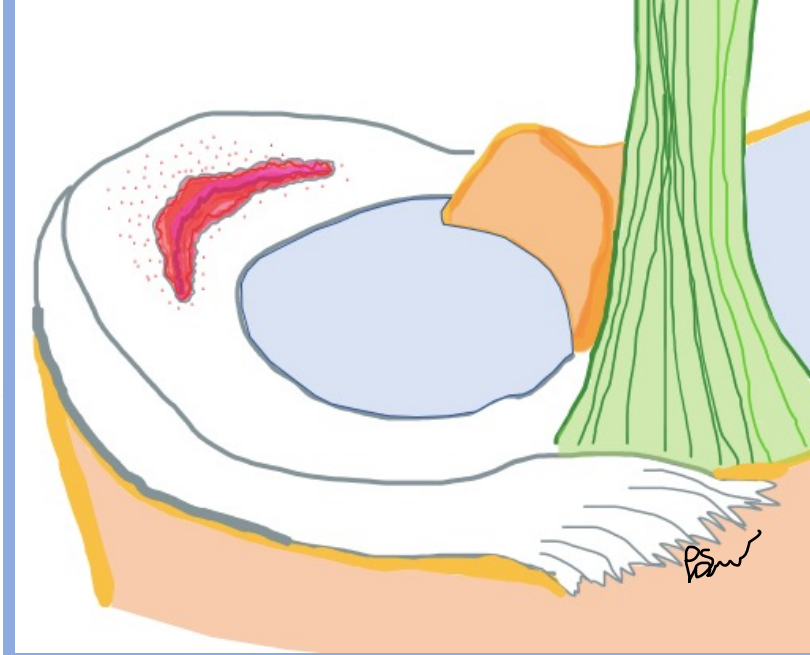
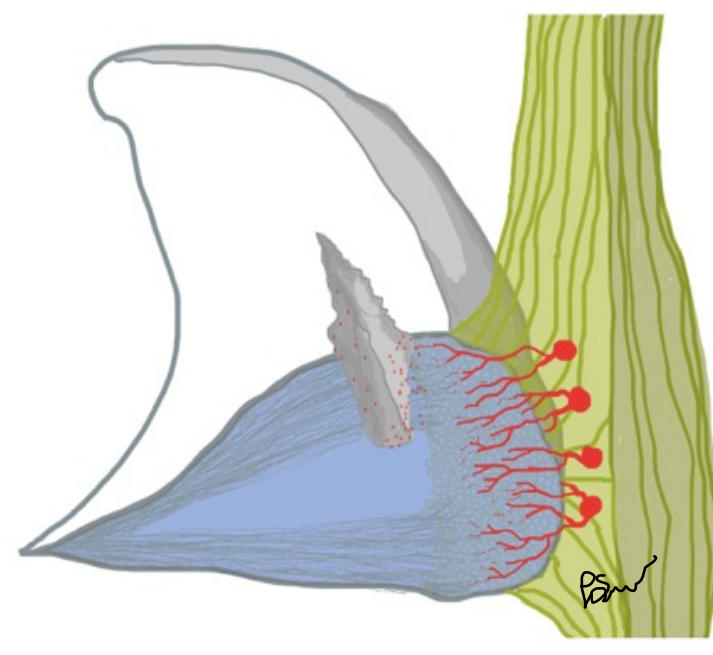
# Radiell ruptur genomgående



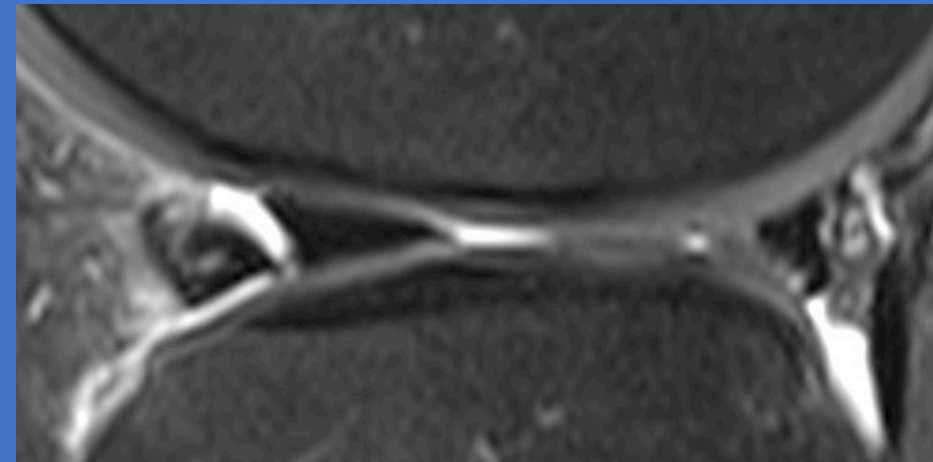
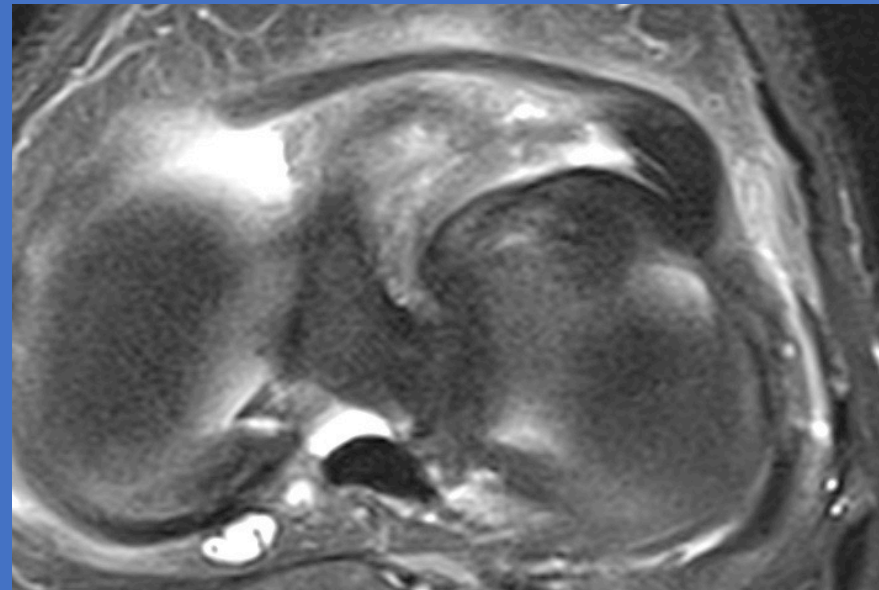
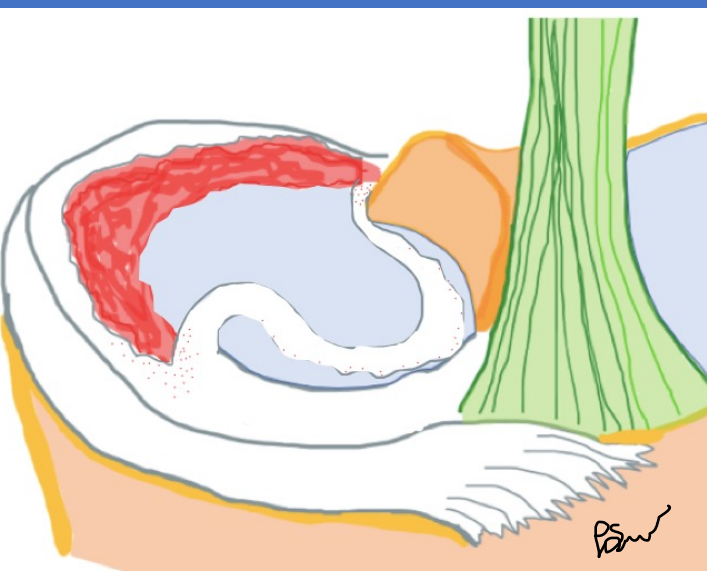
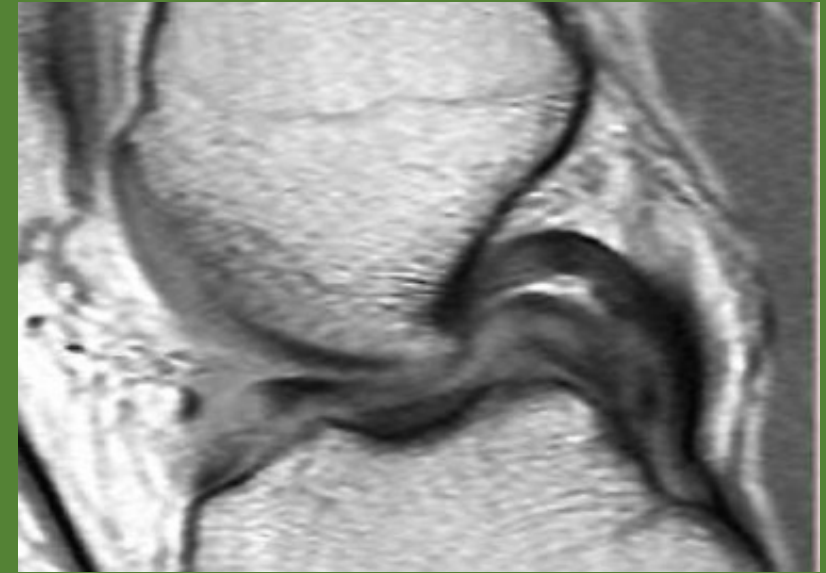
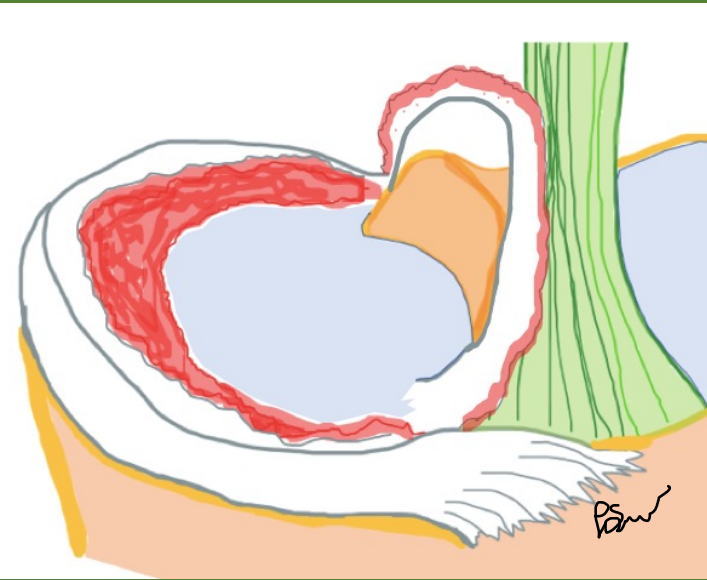
# Parrot beak



# Vertikal longitudinell ruptur

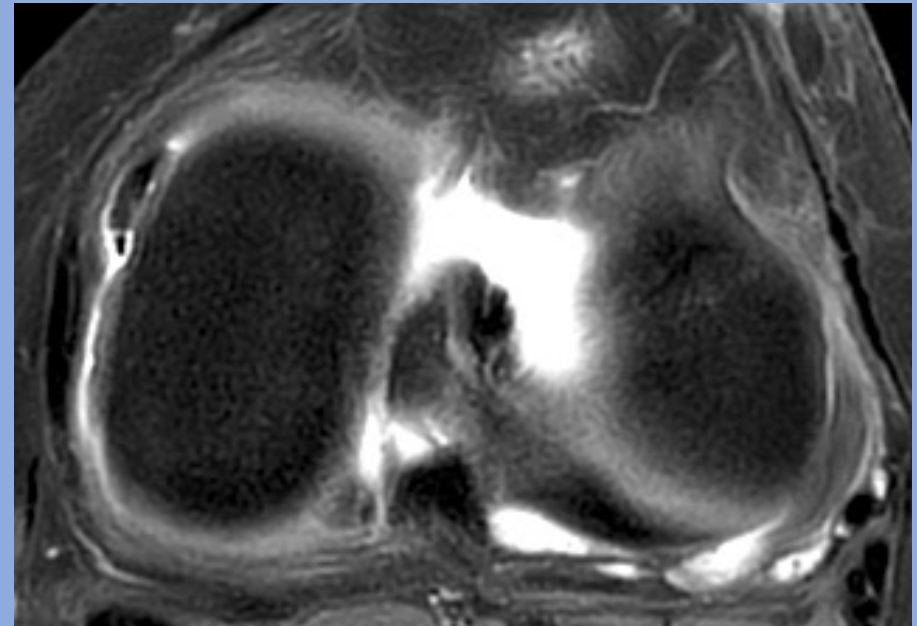
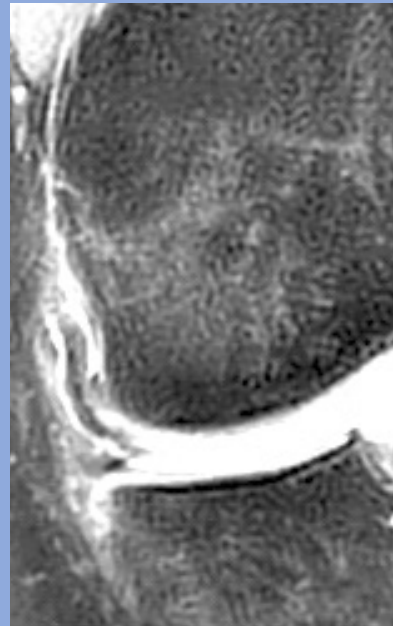
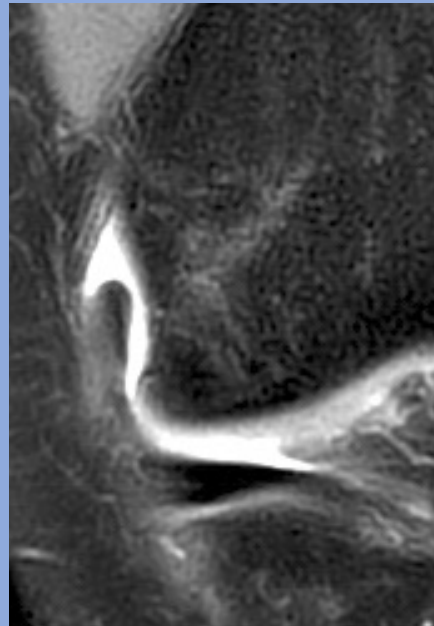
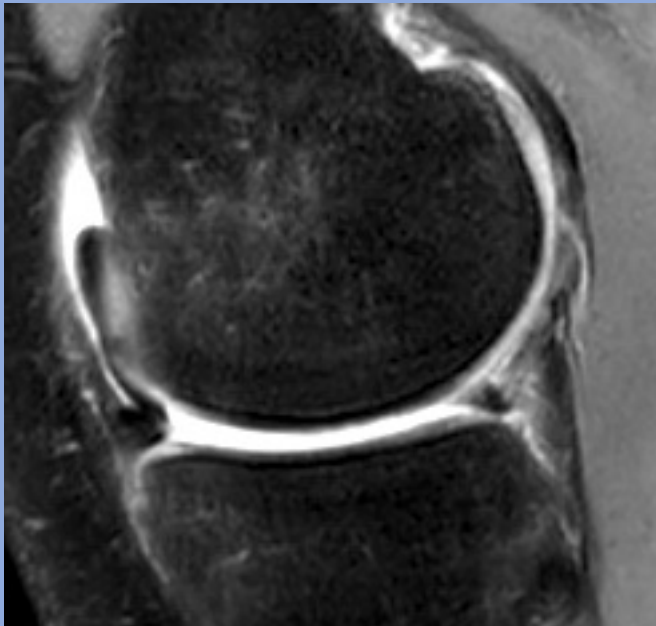
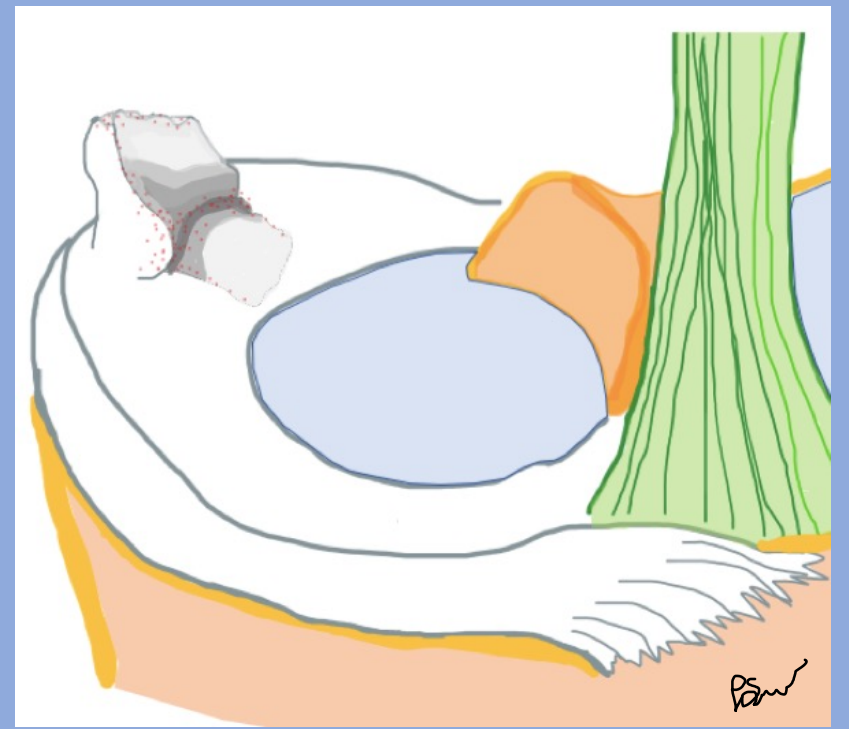
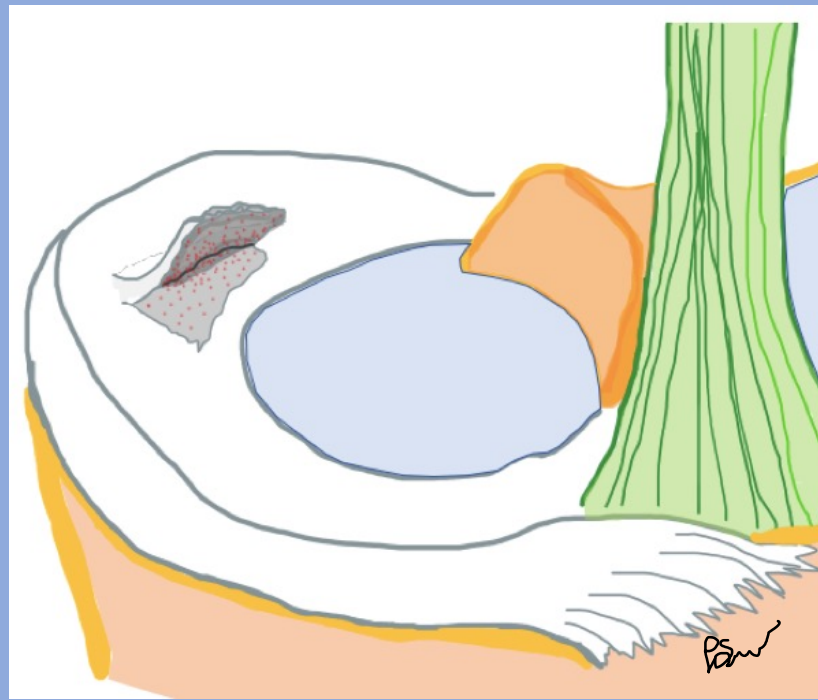
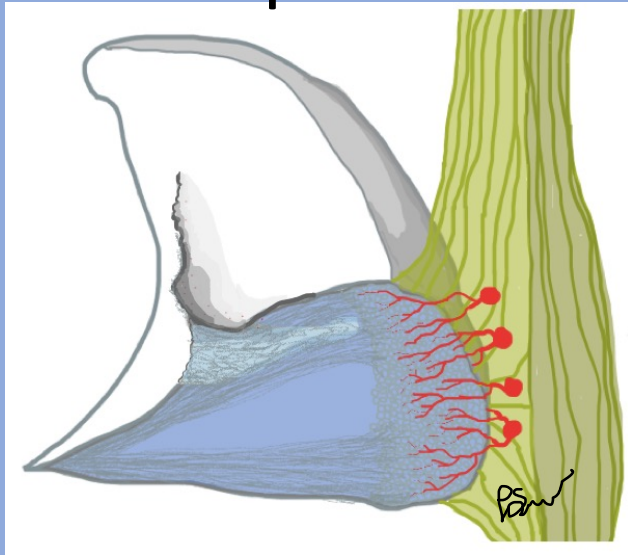


# *Bucket handle och flipped meniskus*

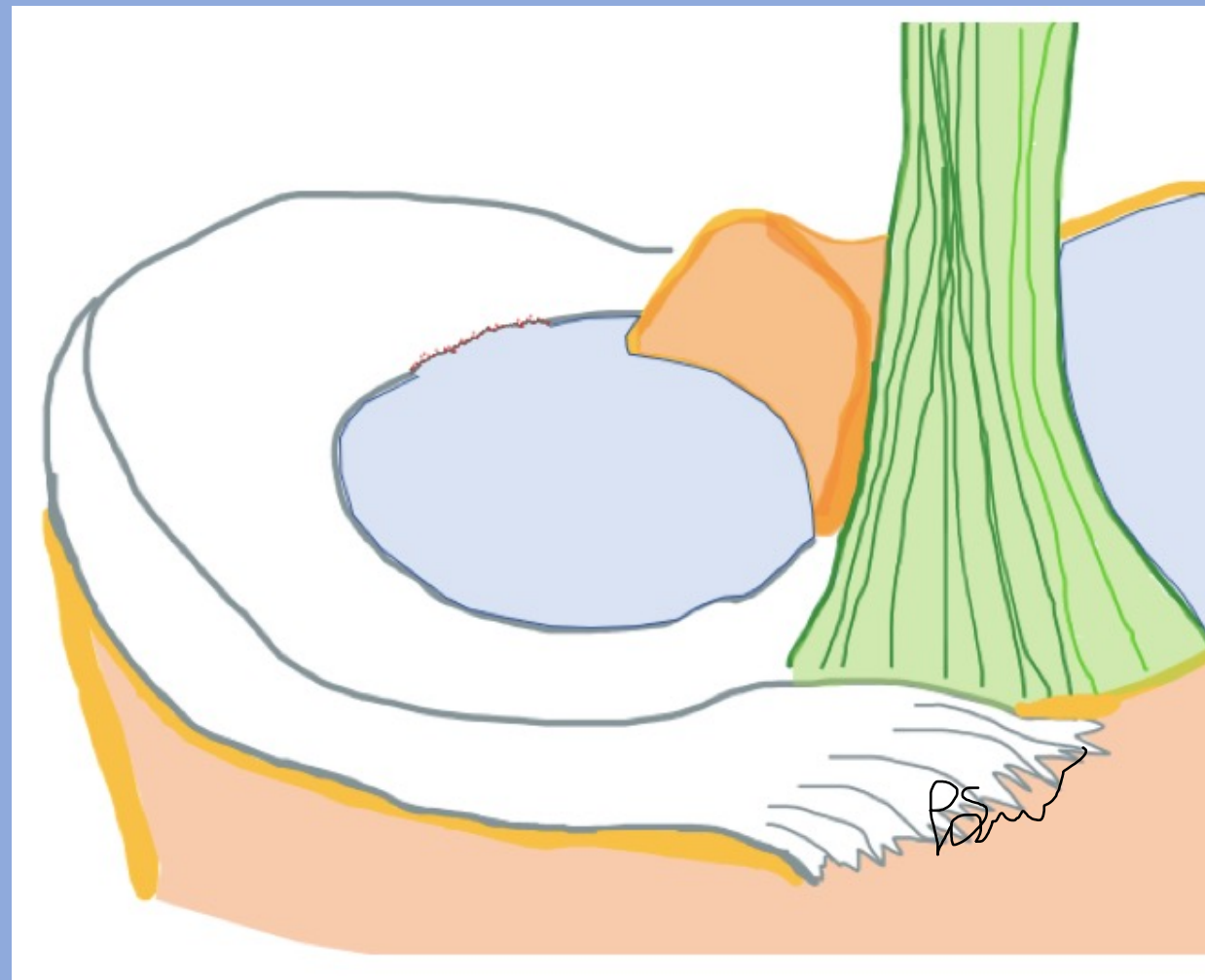
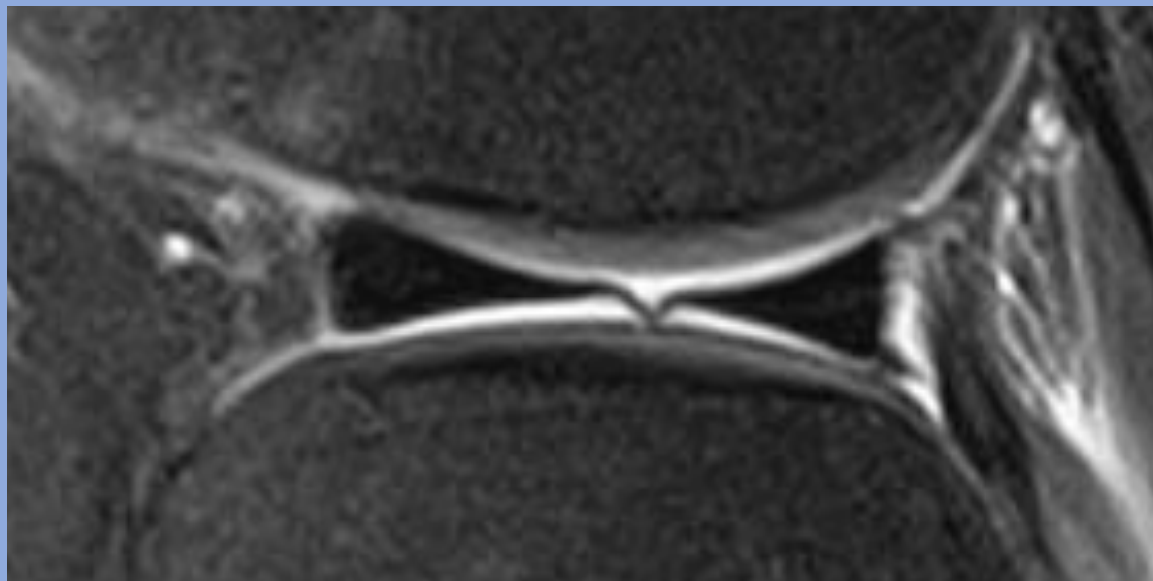




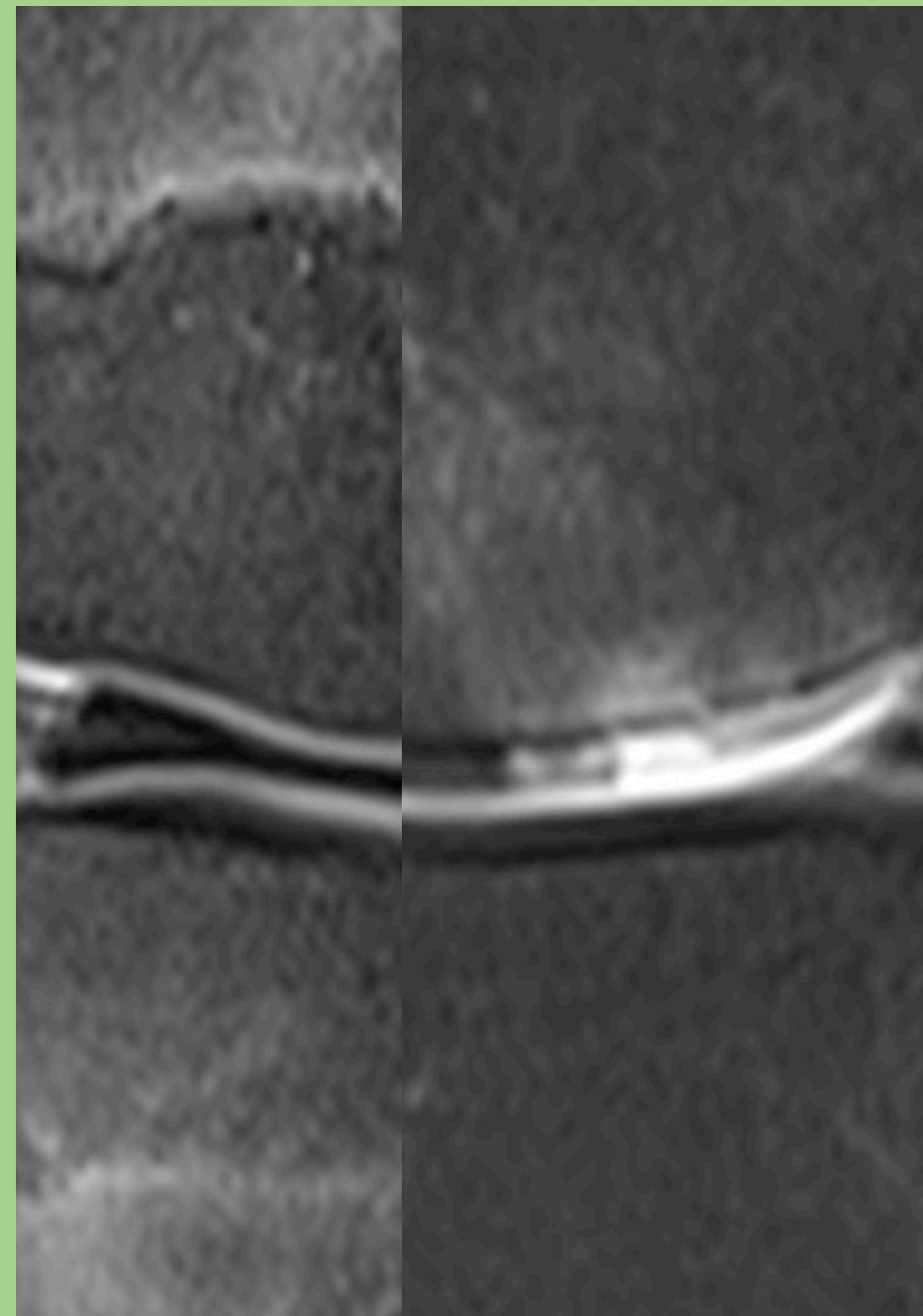
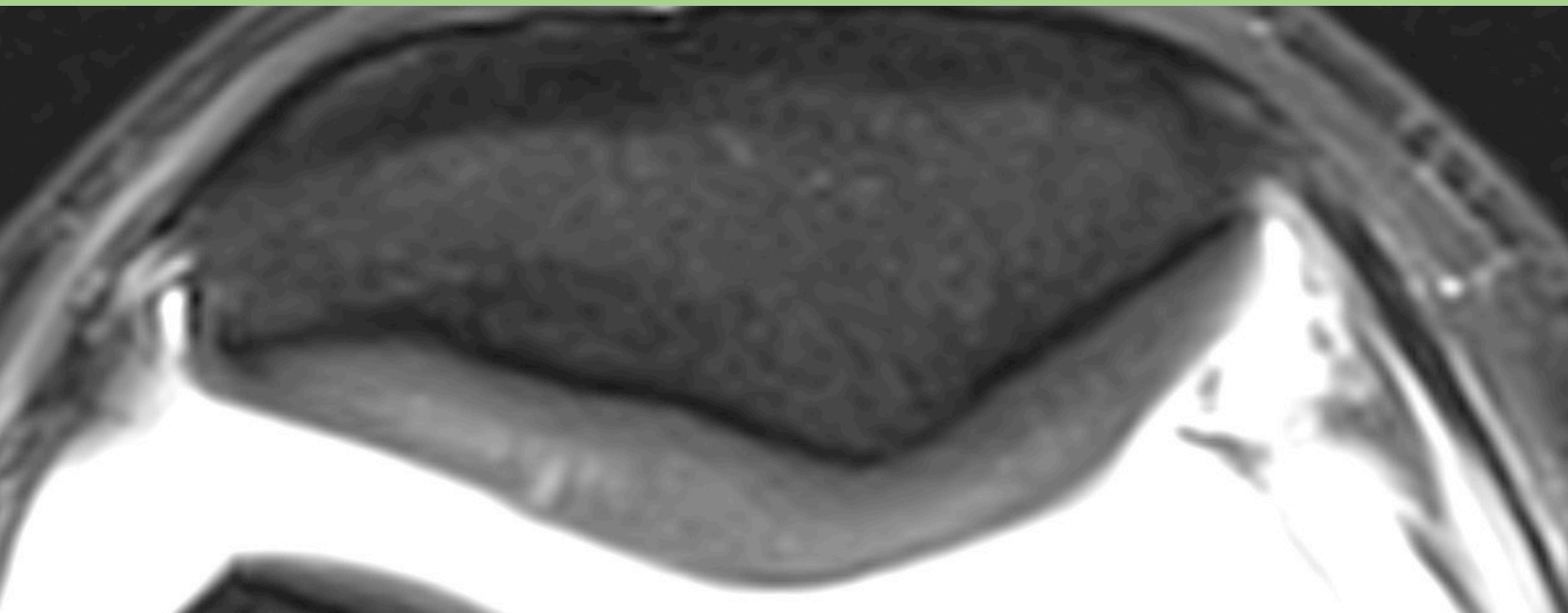
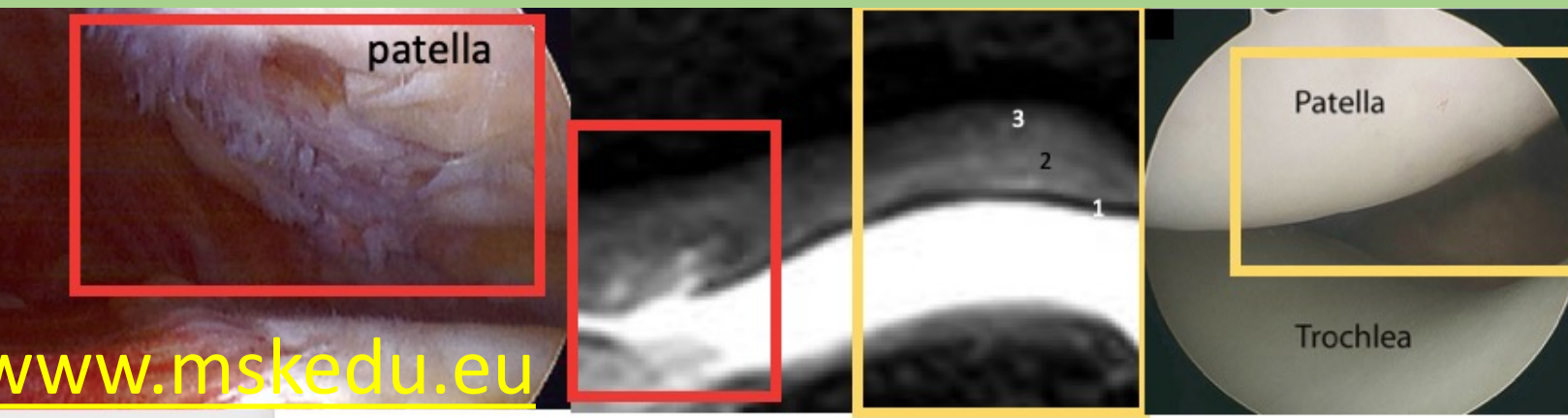
# Flap

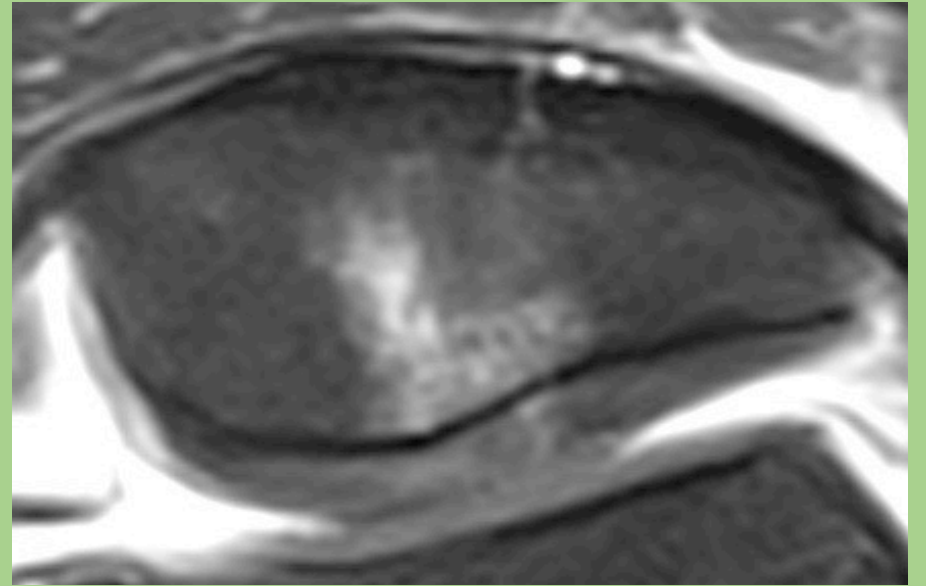
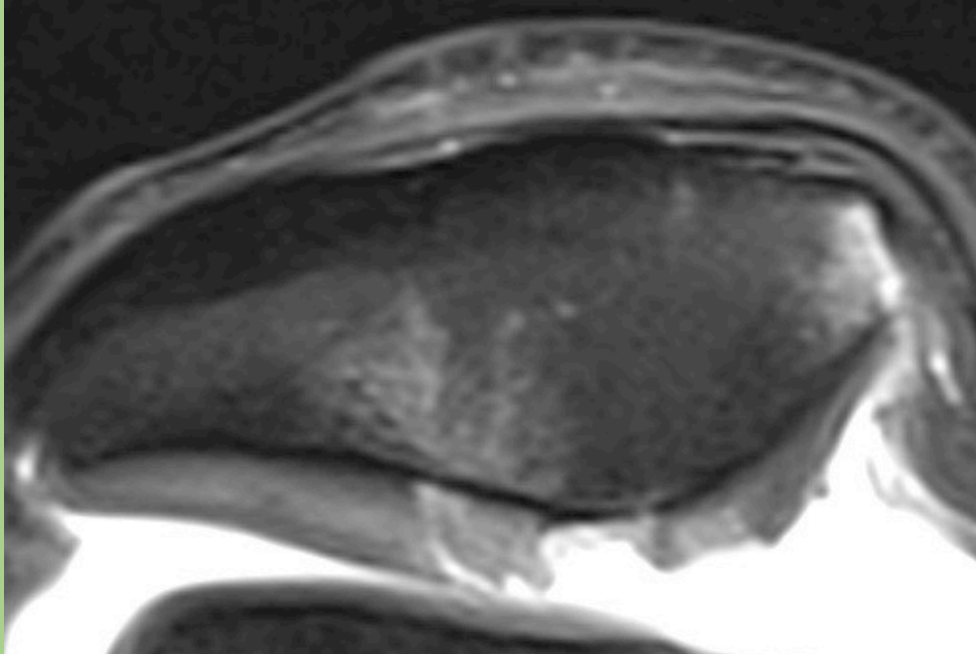
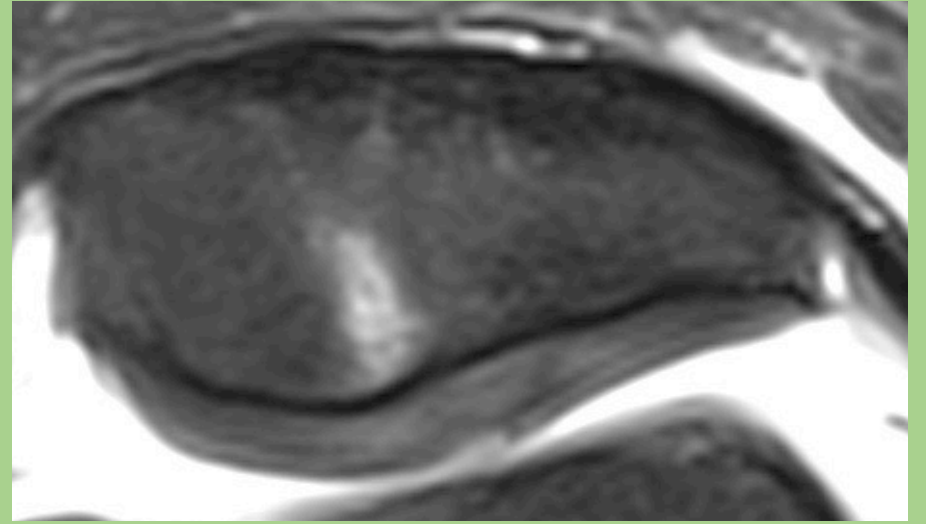
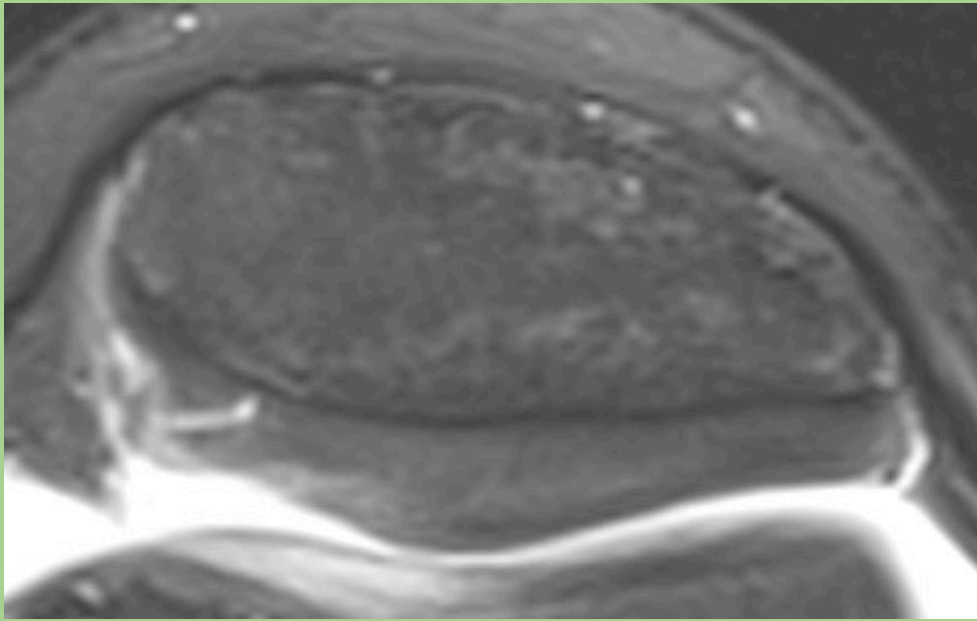


# Meniscal flounce vs. transligament



# Brosk och subkondrala benet







Tack!