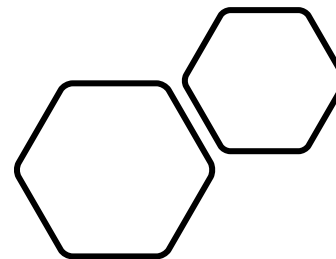


MR Axel



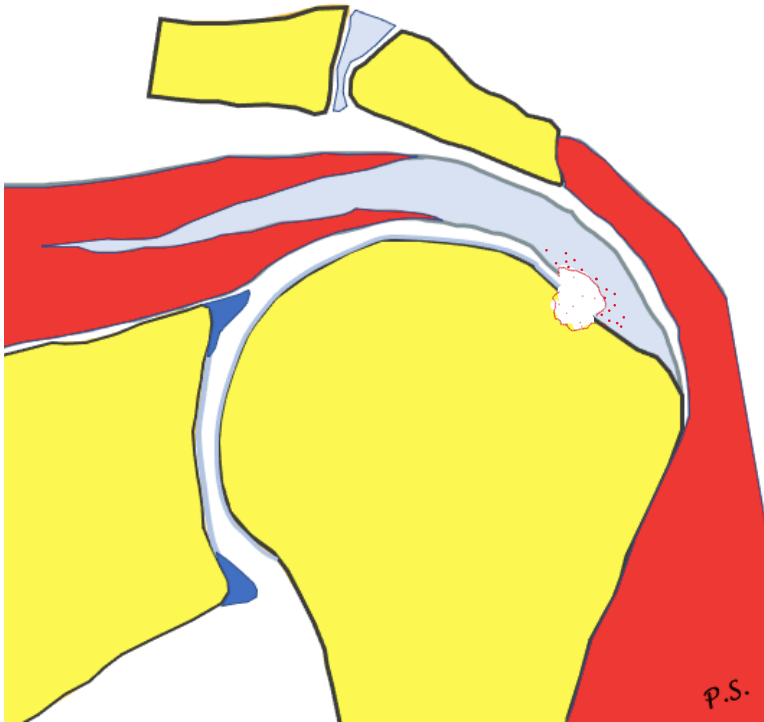
Pawel Szaro MD, Ph.D.,

Överläkare

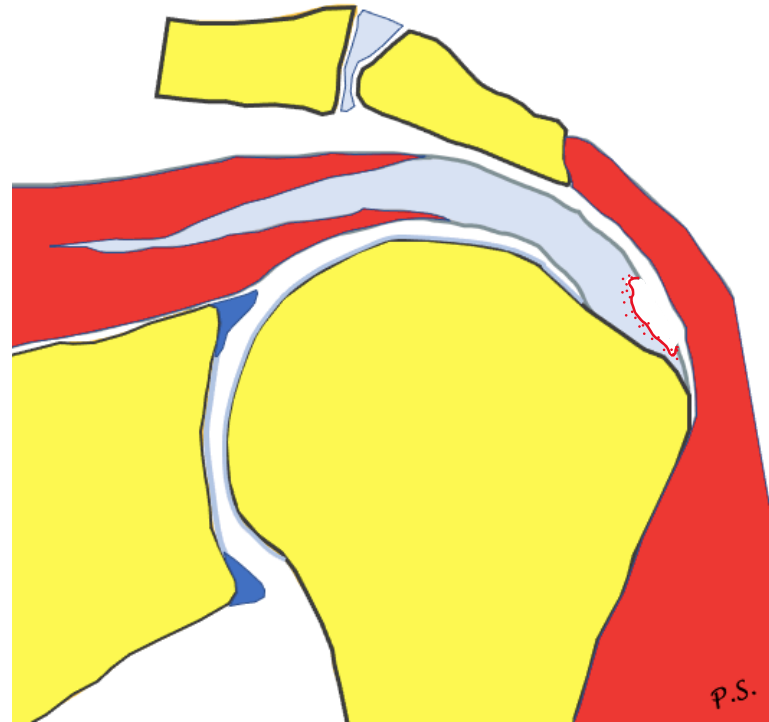
Sahlgrenska
Universitetssjukhuset
Mölndal

pawel.szaro@gu.se

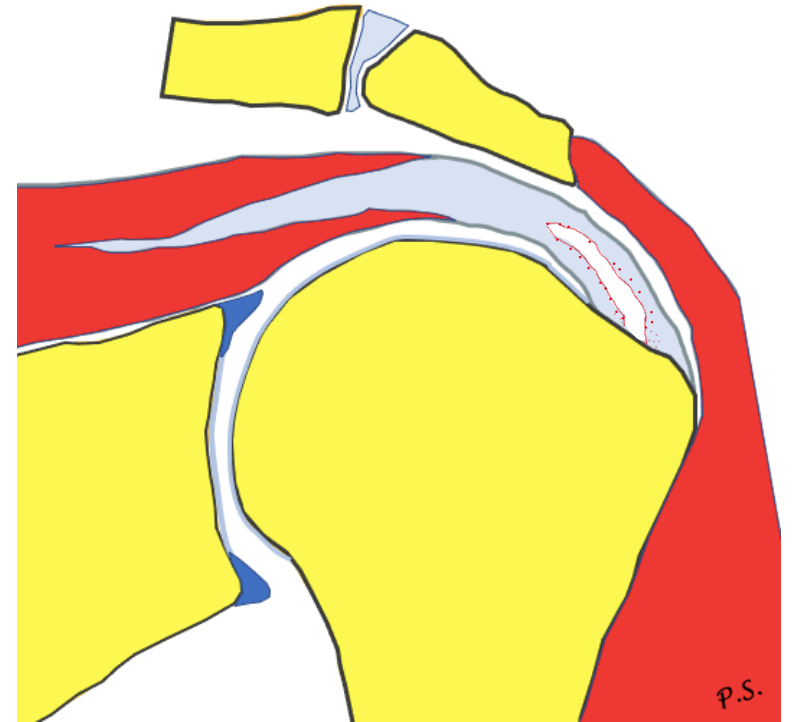
Rupture



articular side
rim rent

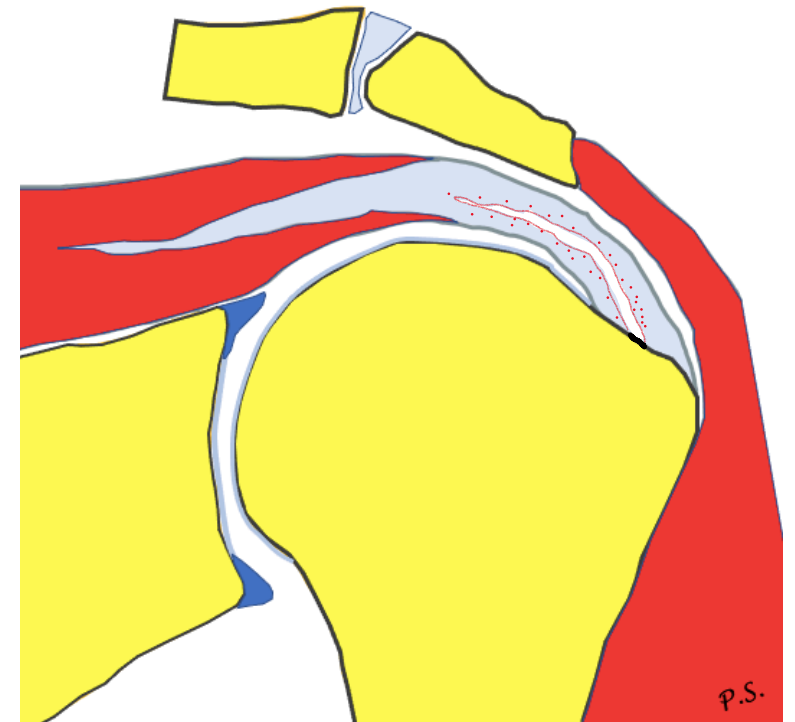
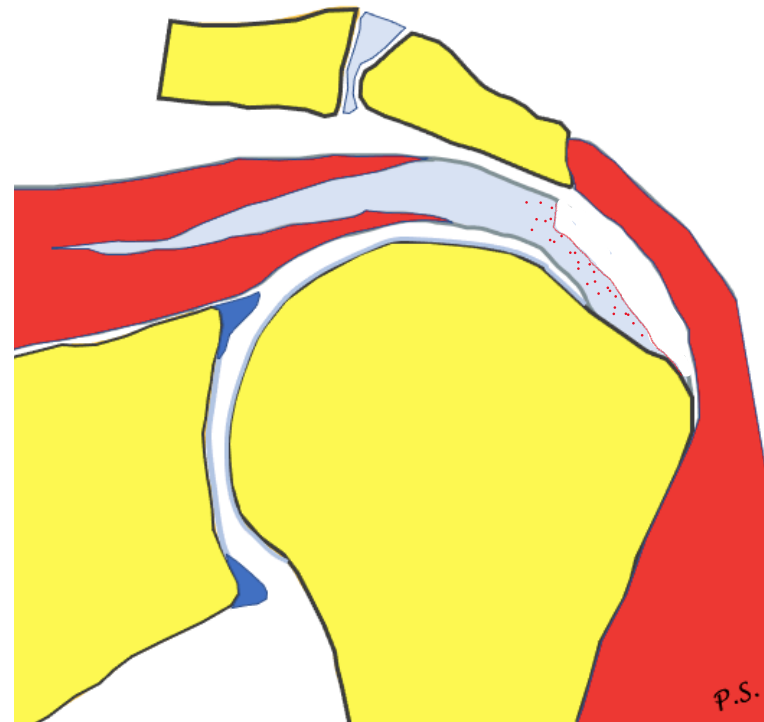
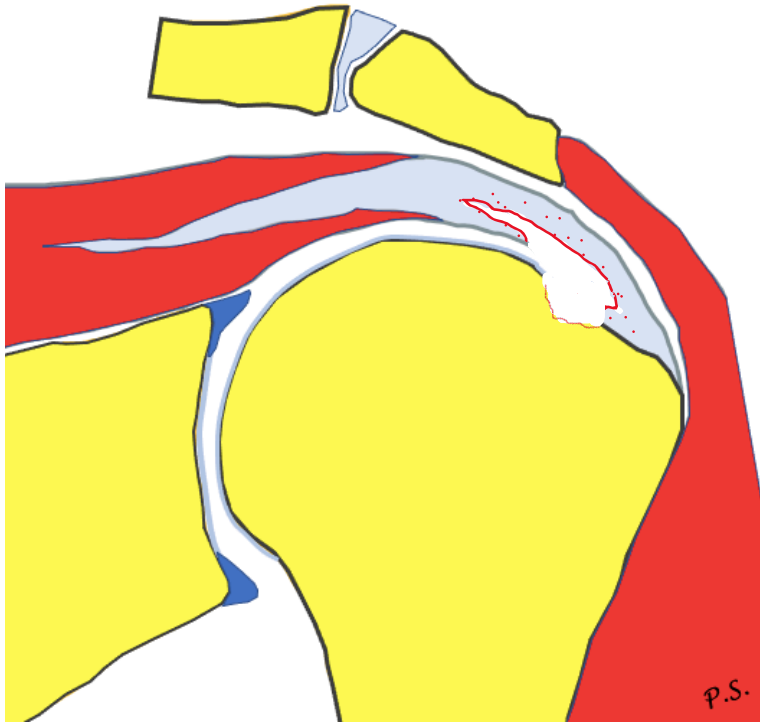


bursal side



intrasubstance

Rupture



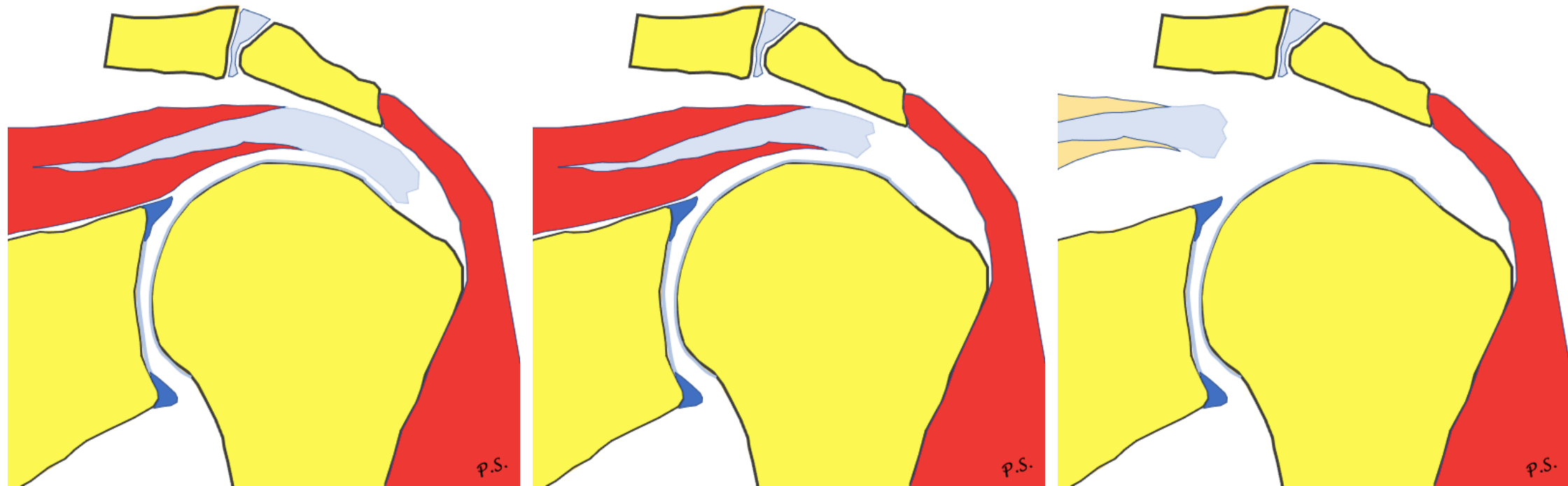
PASTA

partial articular supraspinatus
tendon avulsion

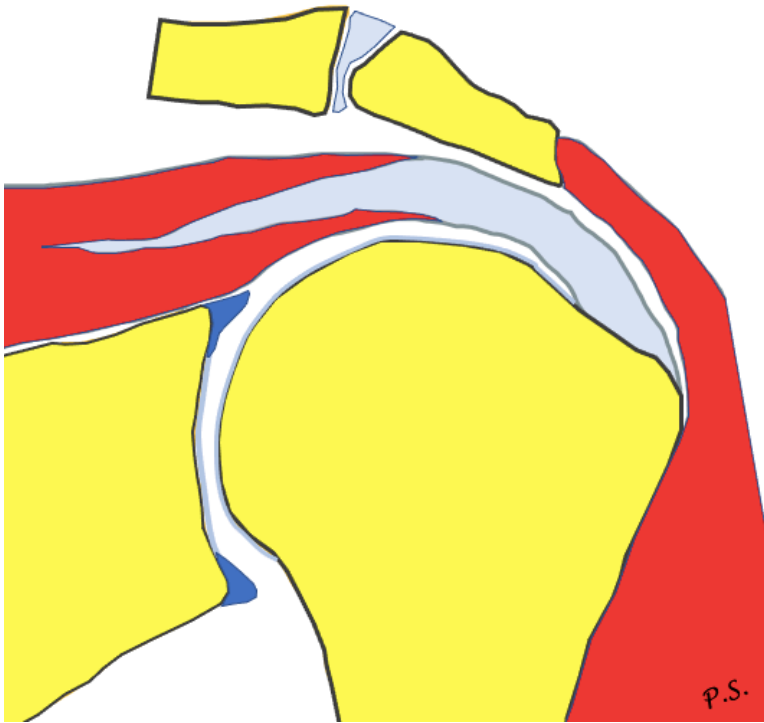
Reverse PASTA

PITA

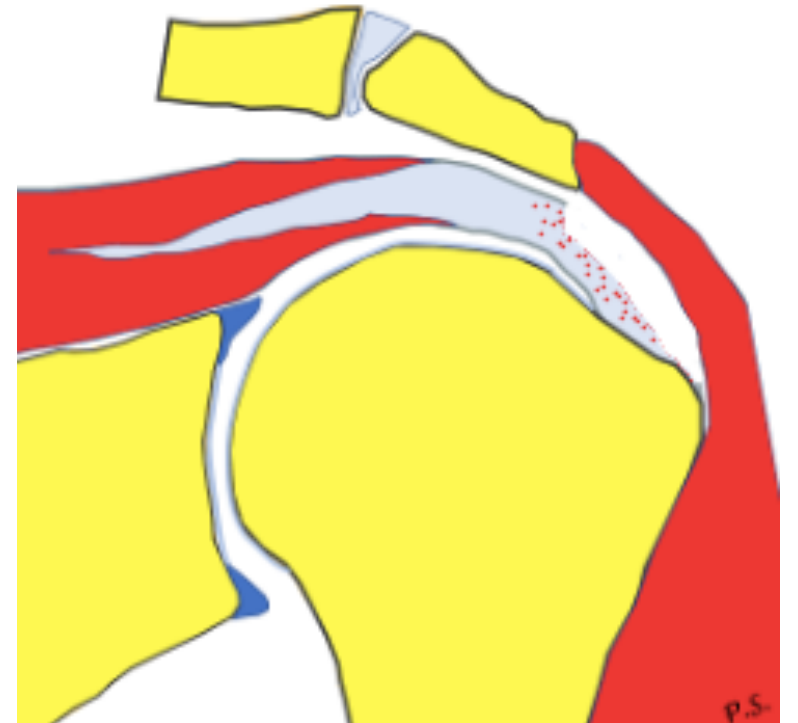
Retraction (Patte)



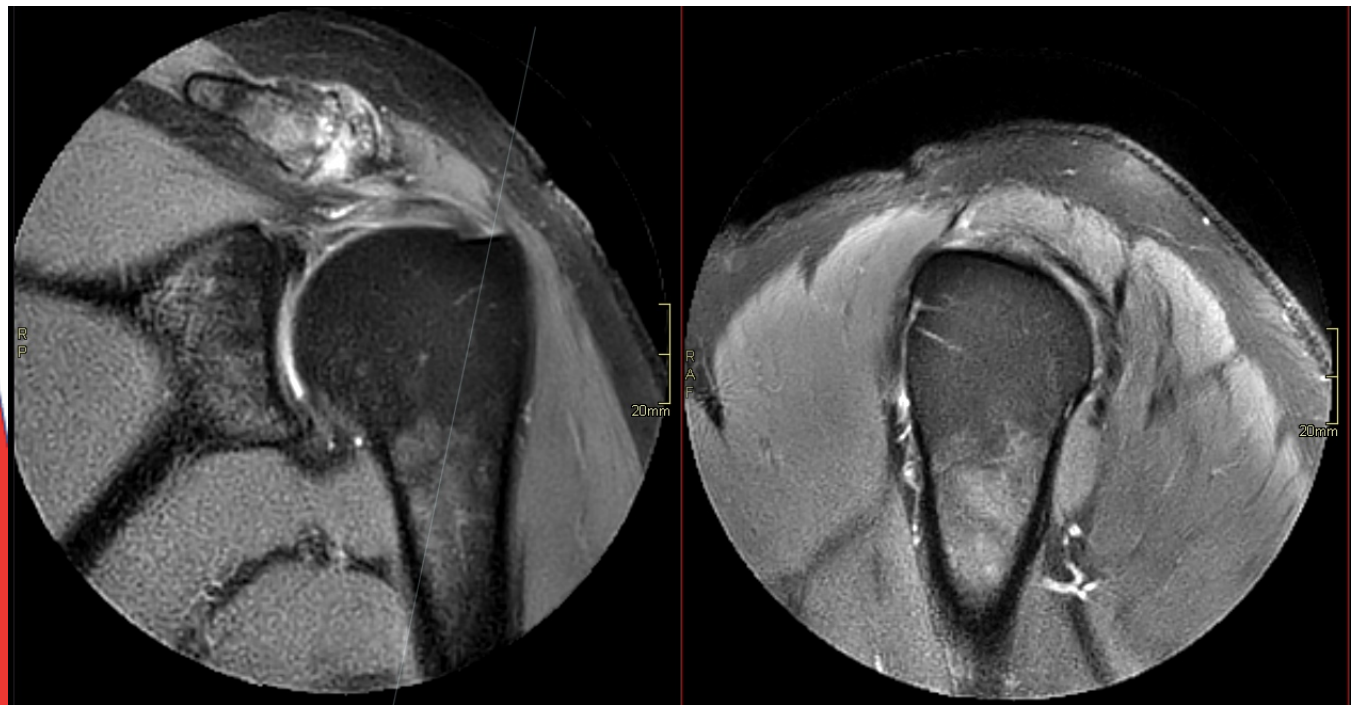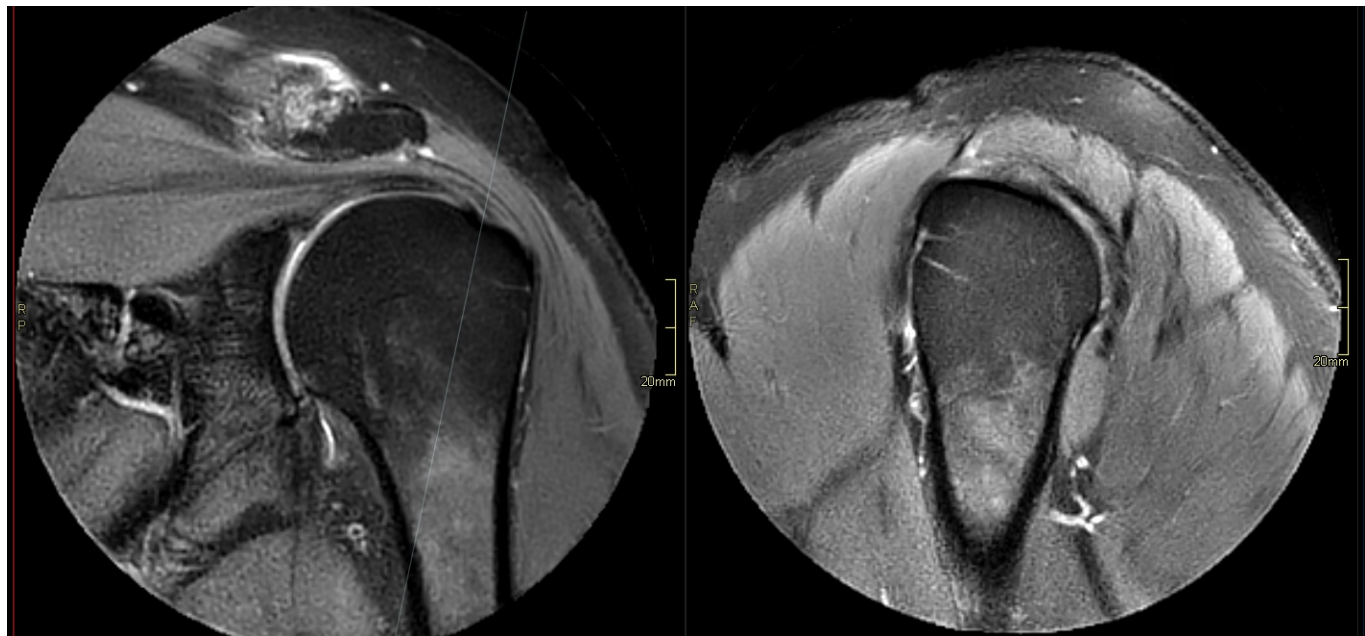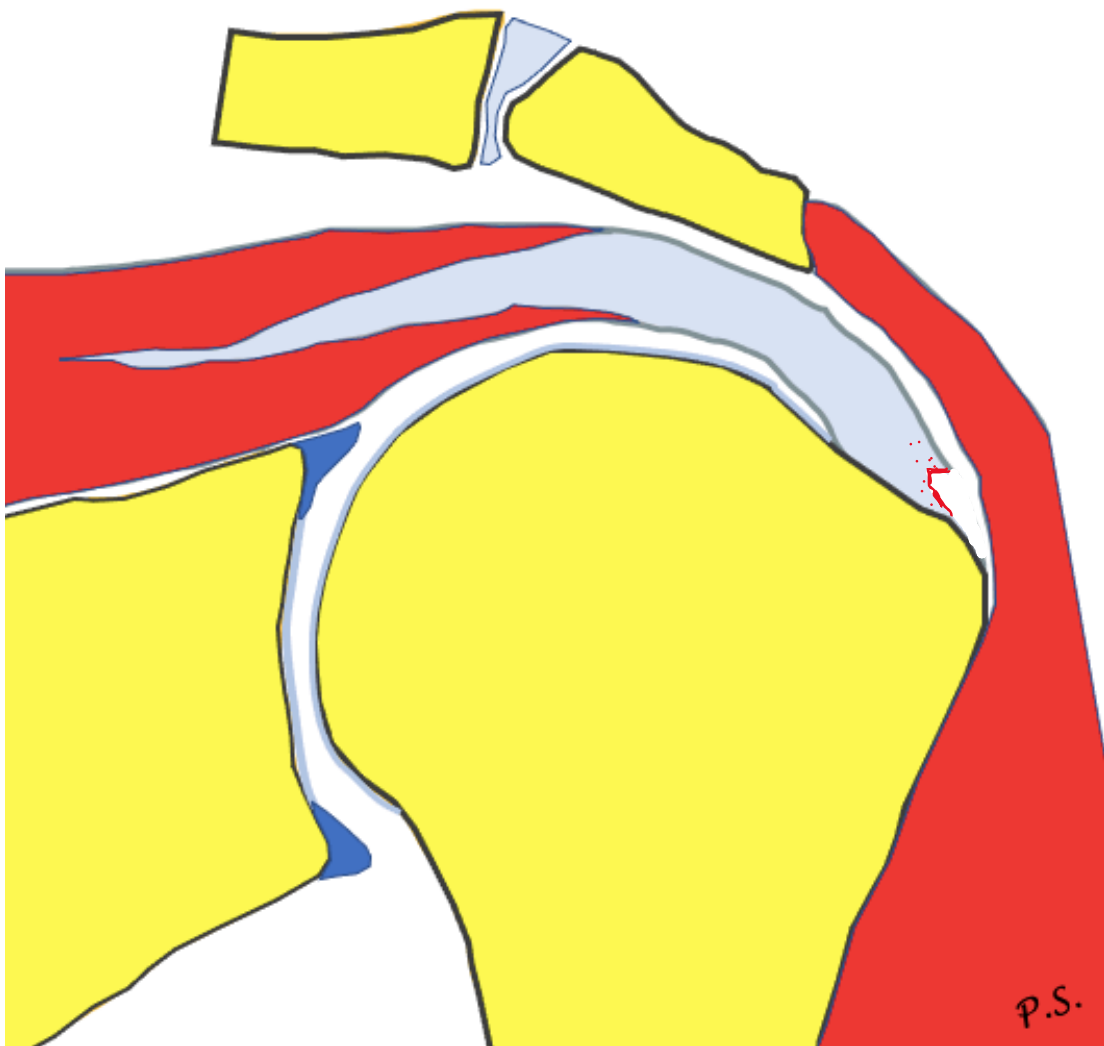
Grading



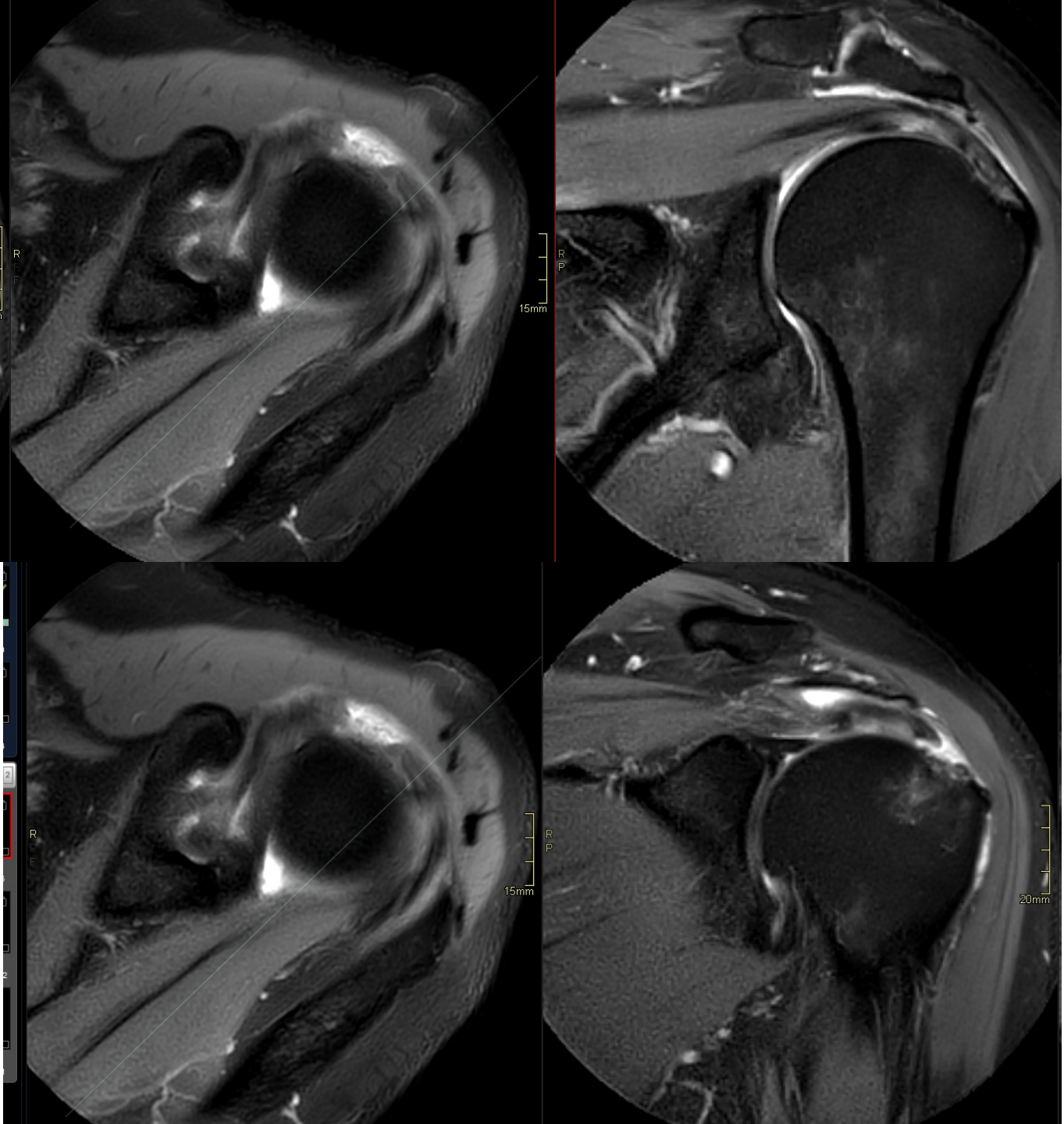
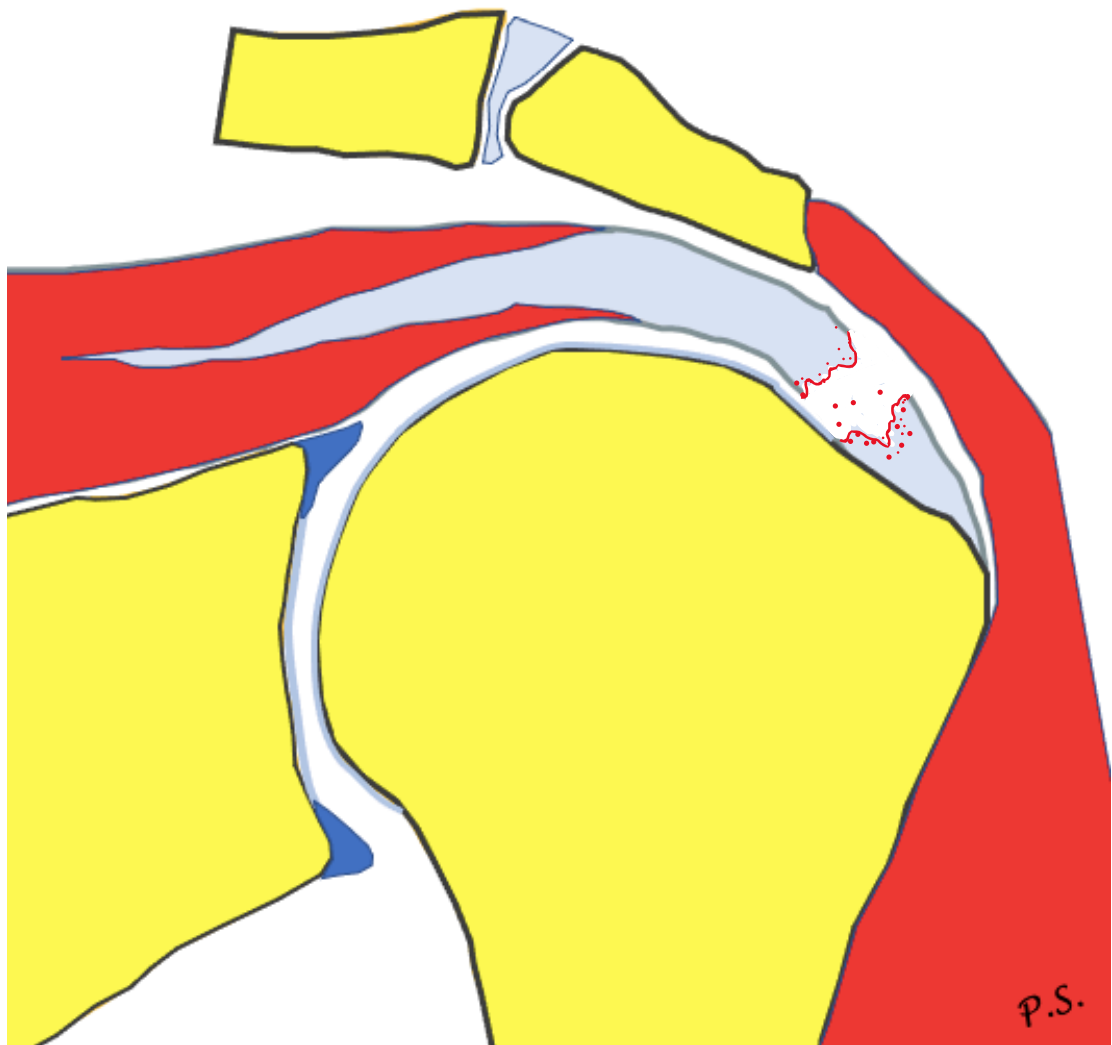
1. <3 mm
2. 3-6 mm
3. >6 mm




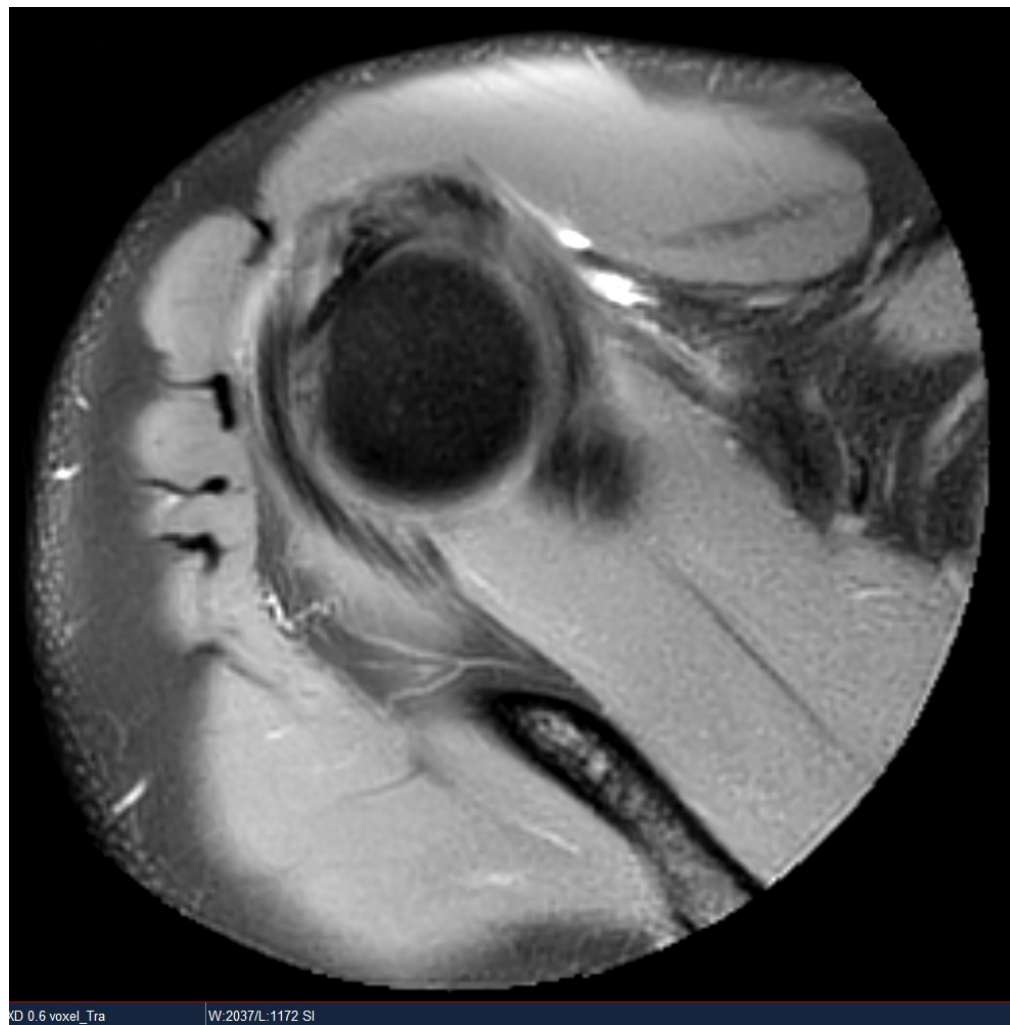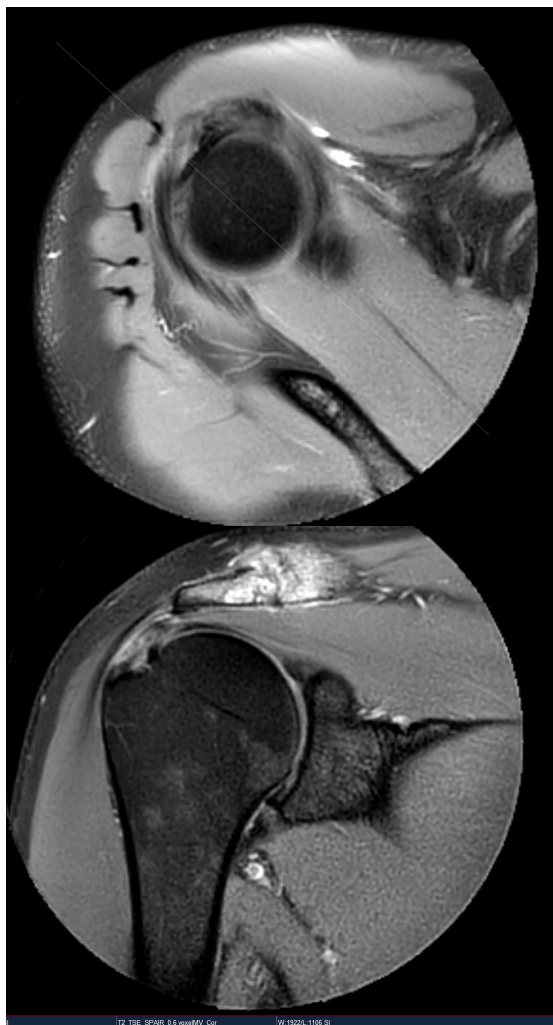
Rupture



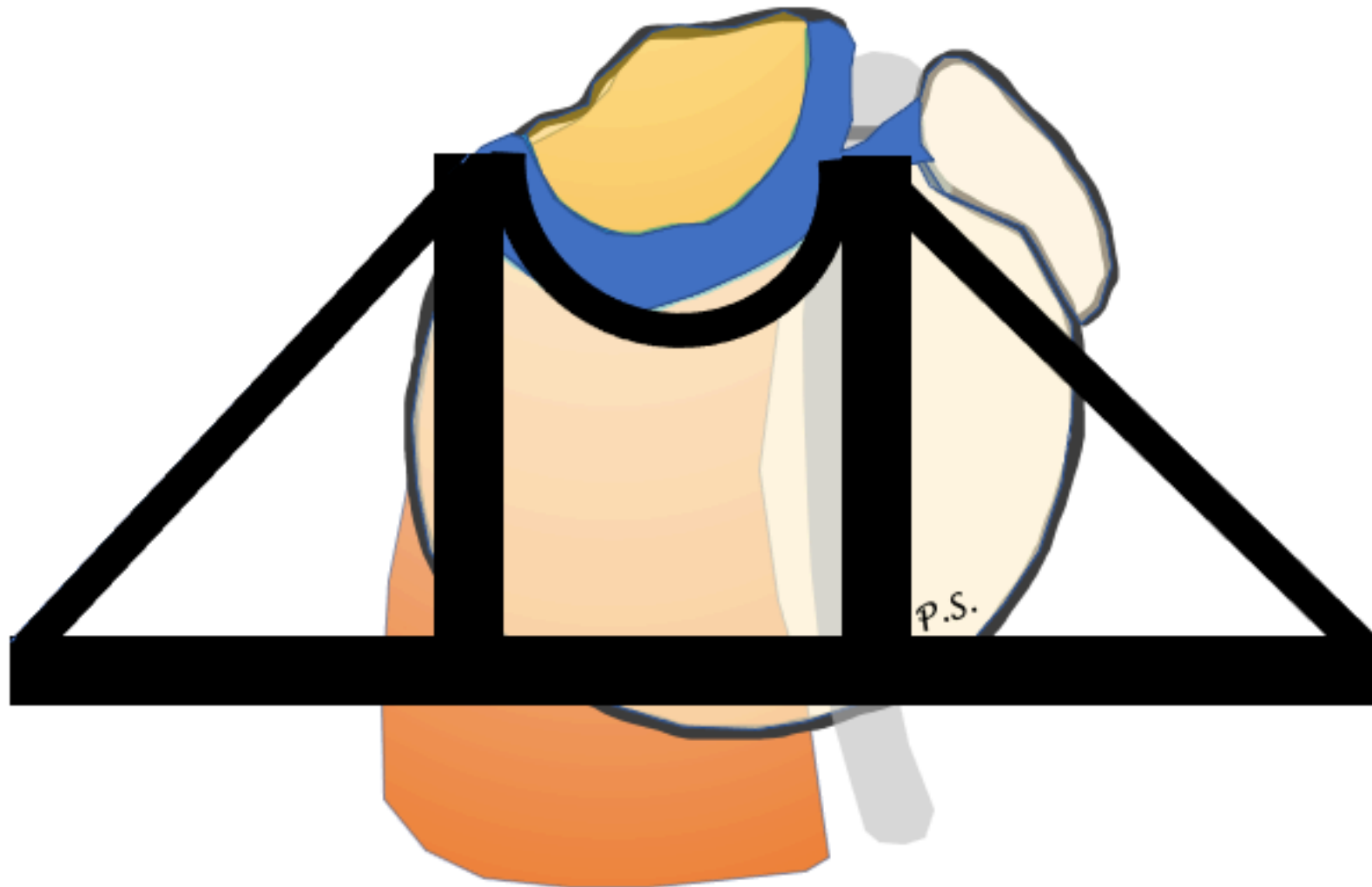Ruptur




Rotator cable




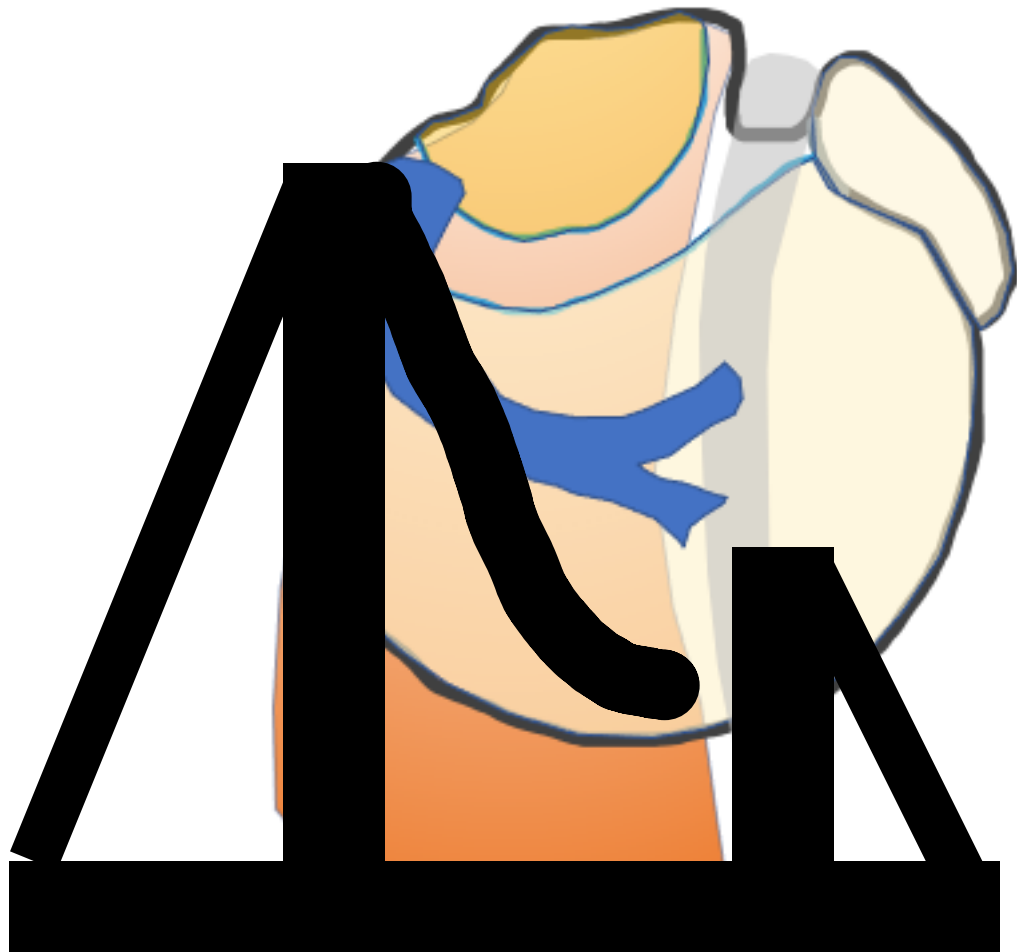
Biomechanical suspension-bridge model for a rotator cuff tear



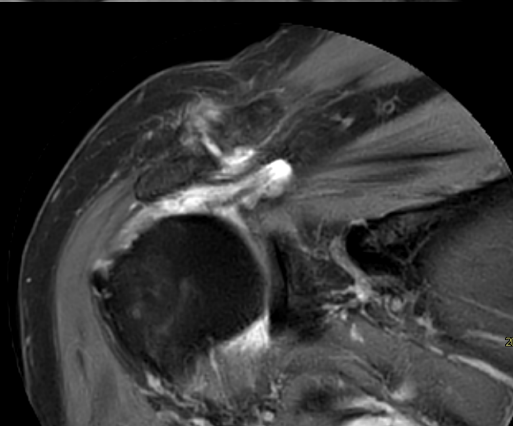
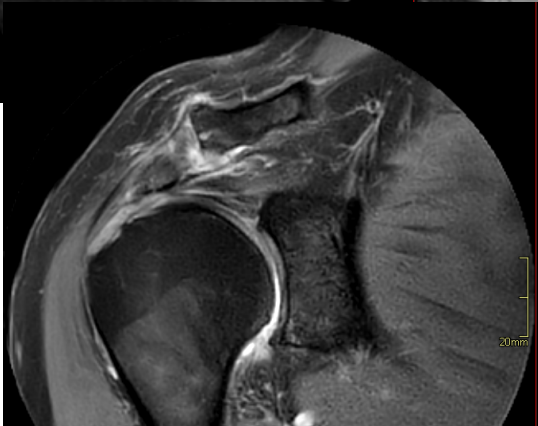
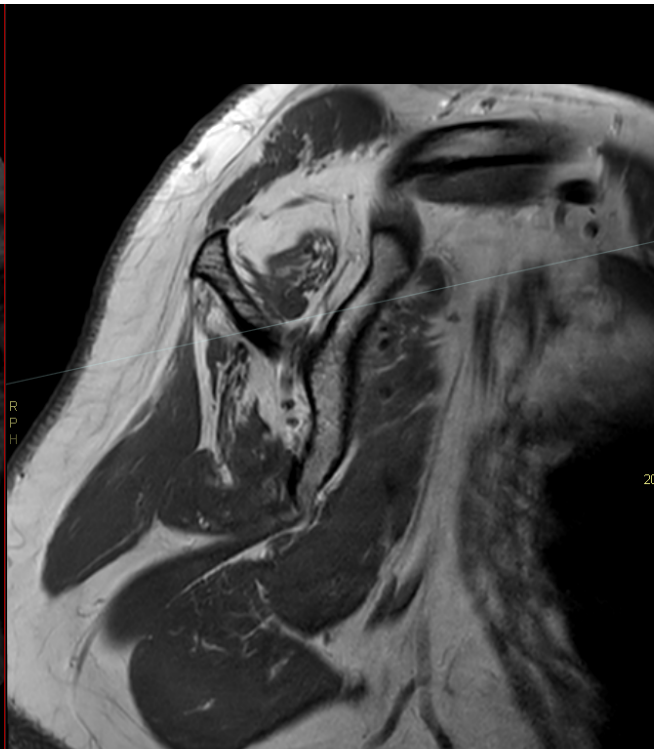
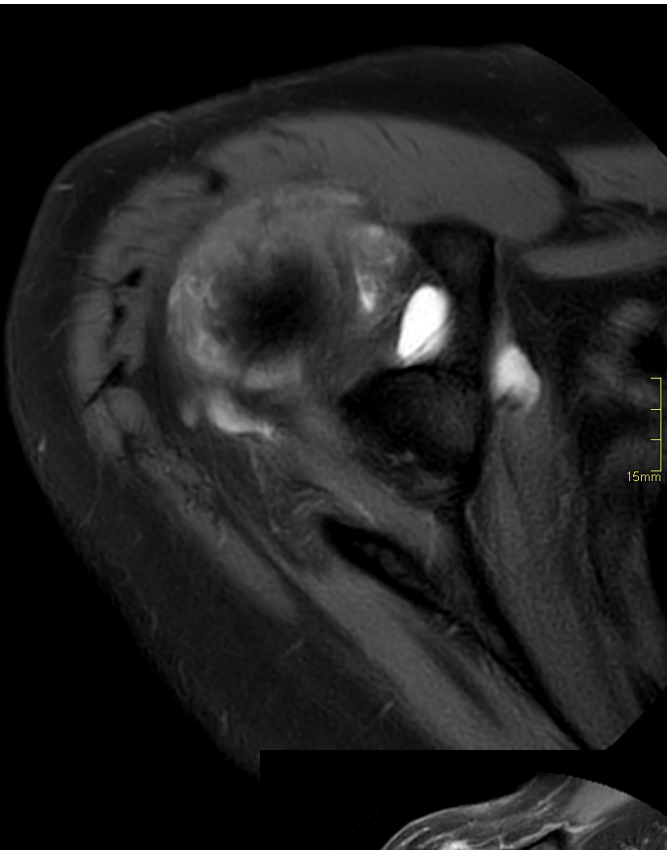
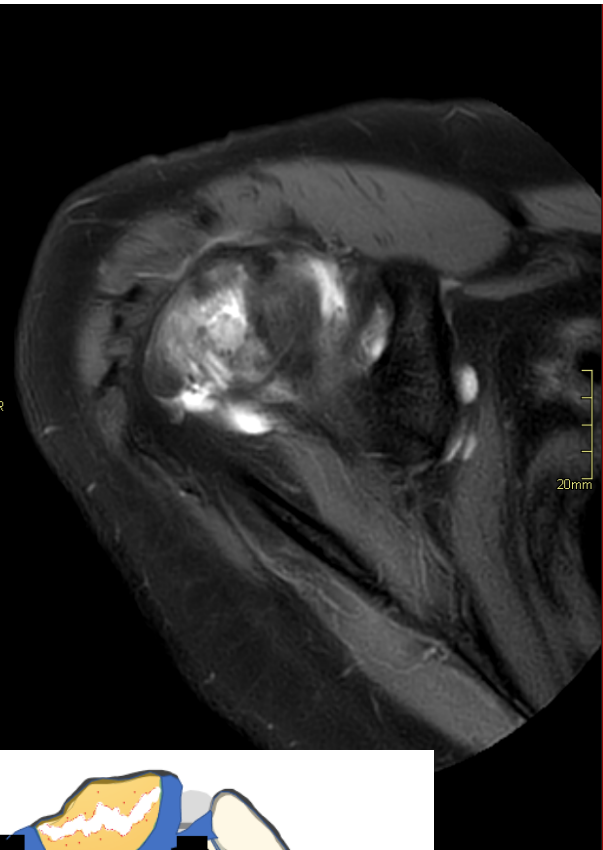
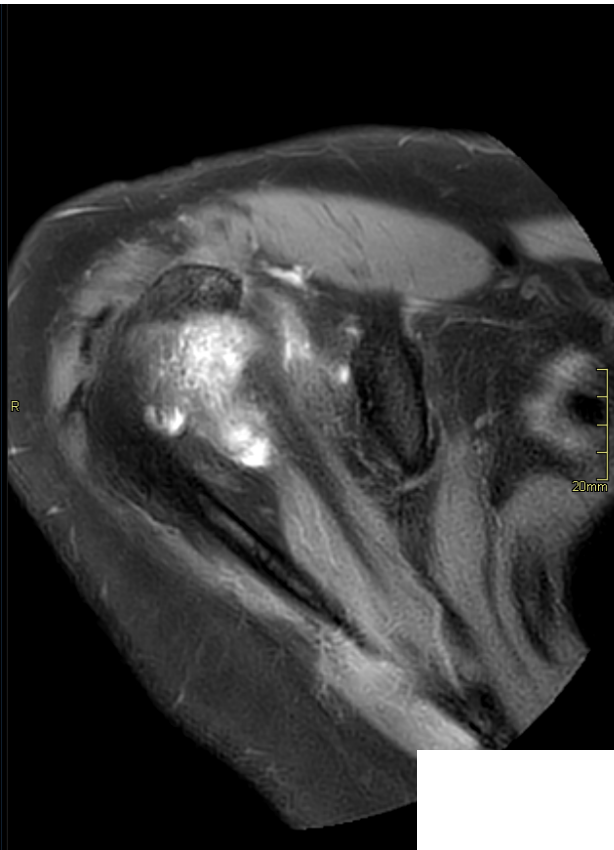
Biomechanical suspension-bridge model for a rotator cuff tear



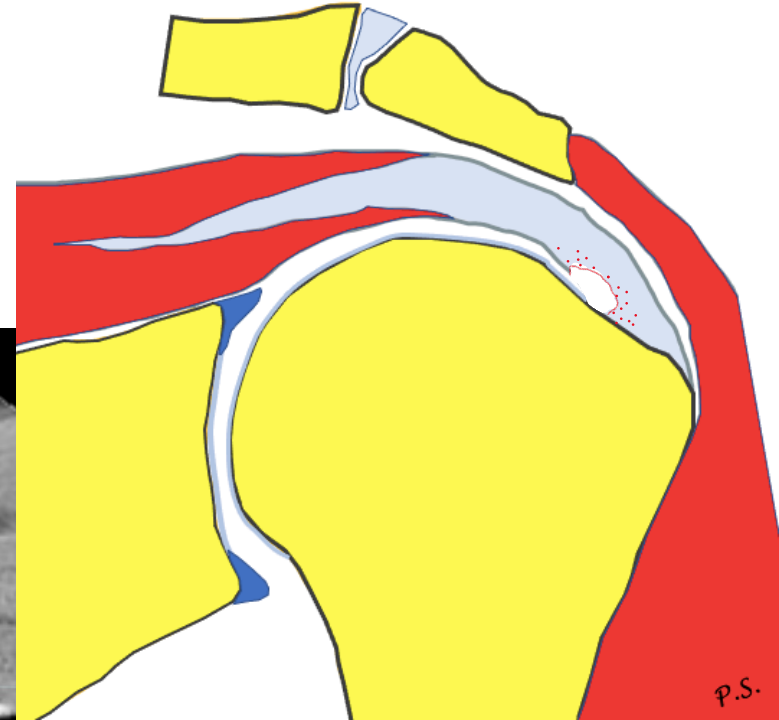
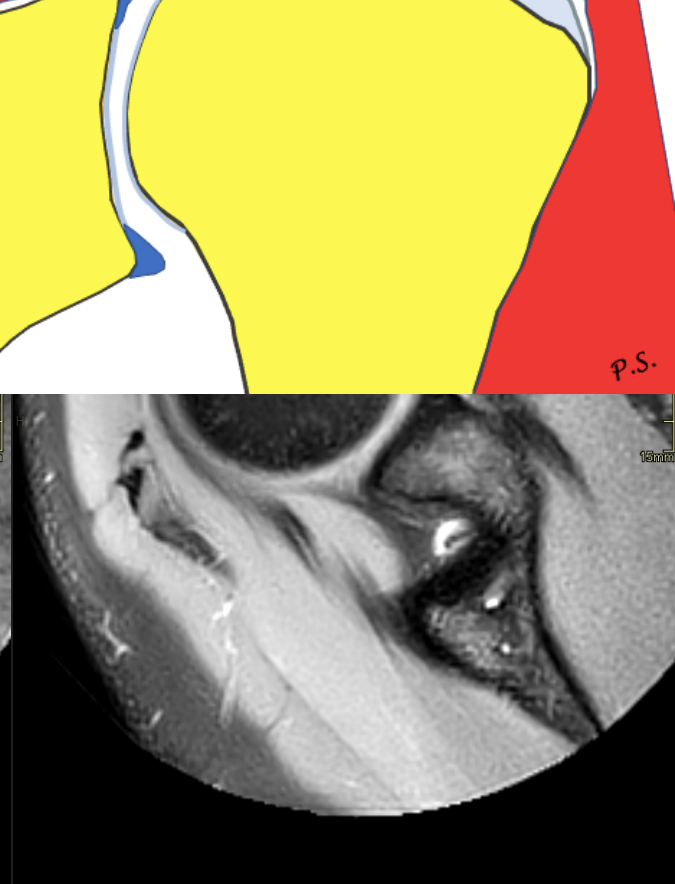
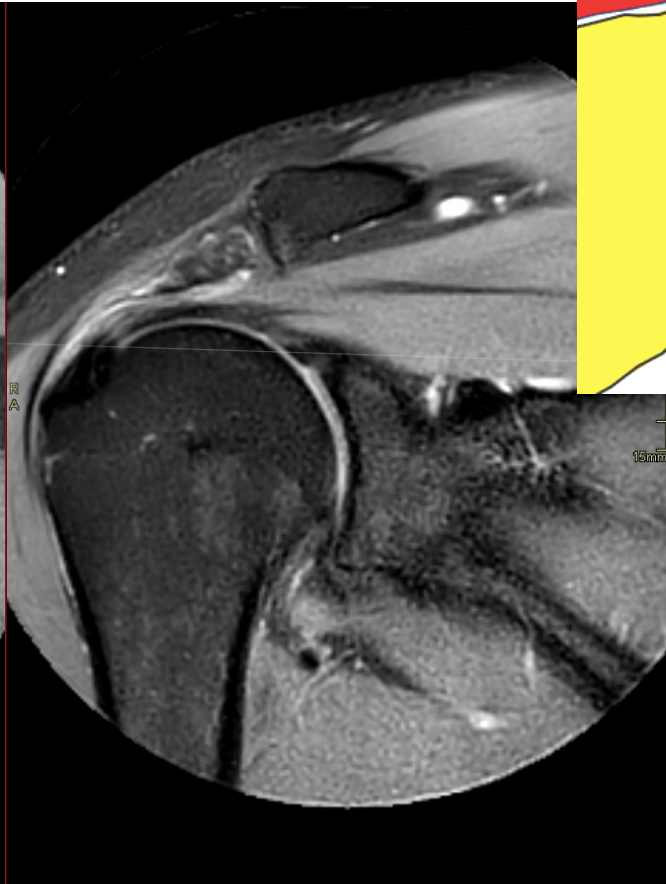
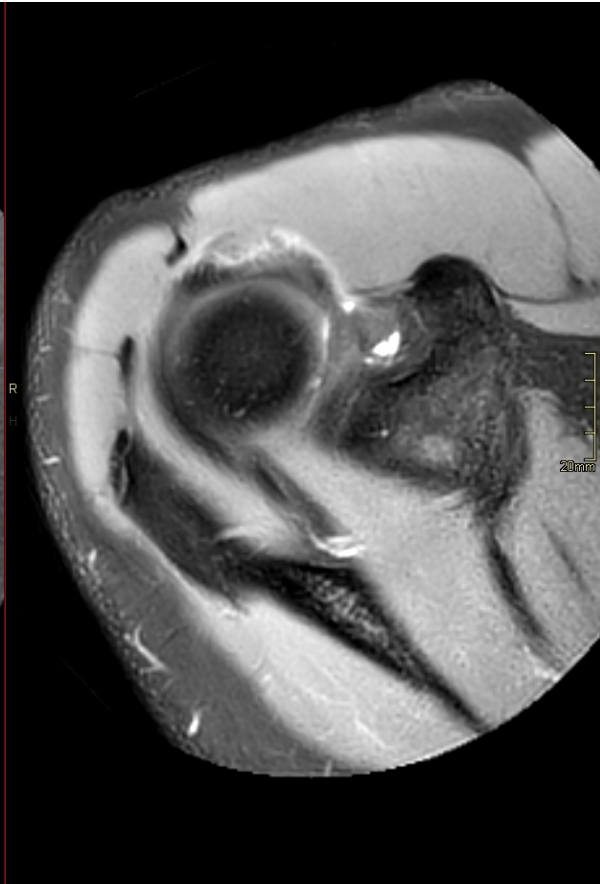
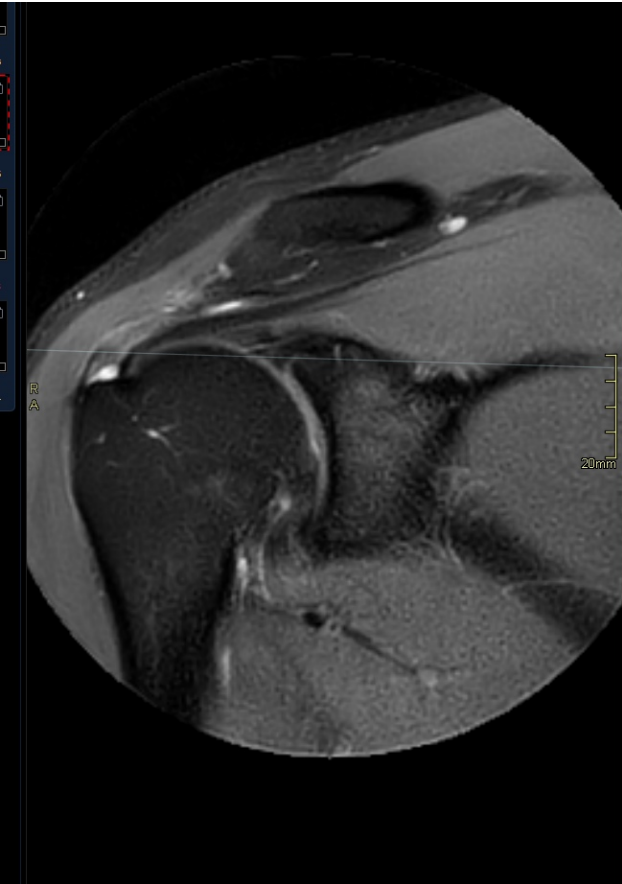
Biomechanical suspension-bridge model for a rotator cuff tear



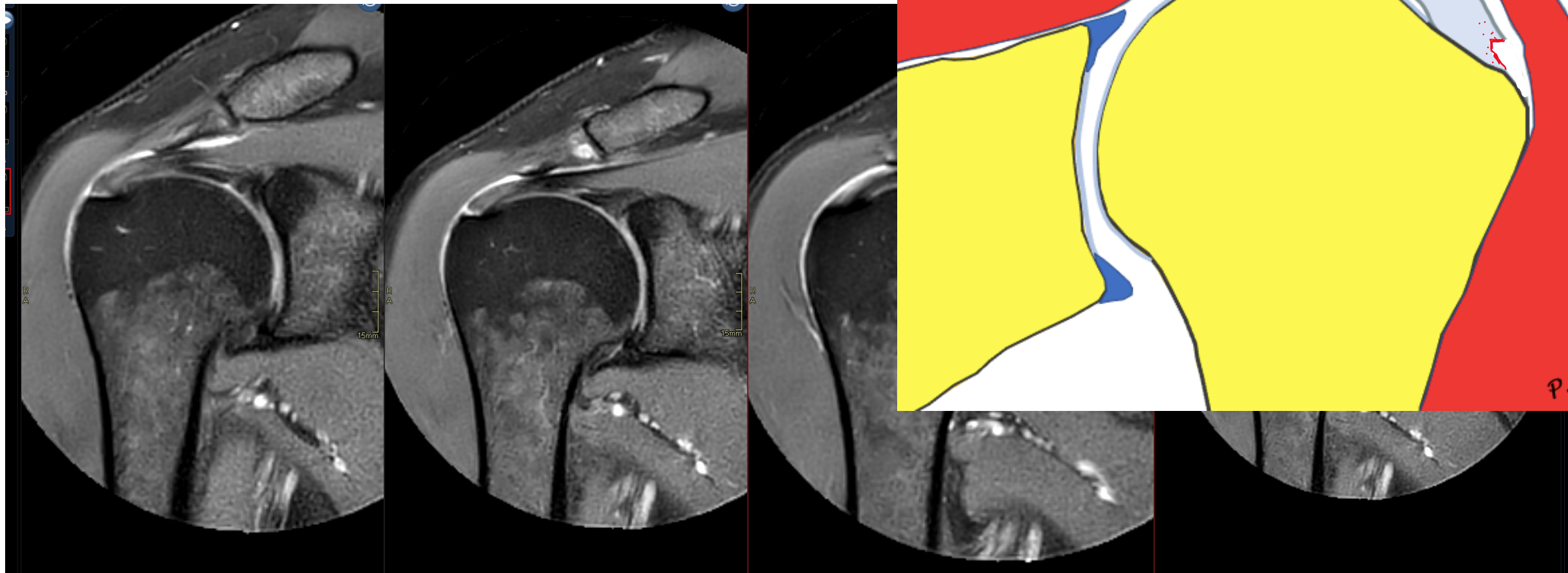
Kabel



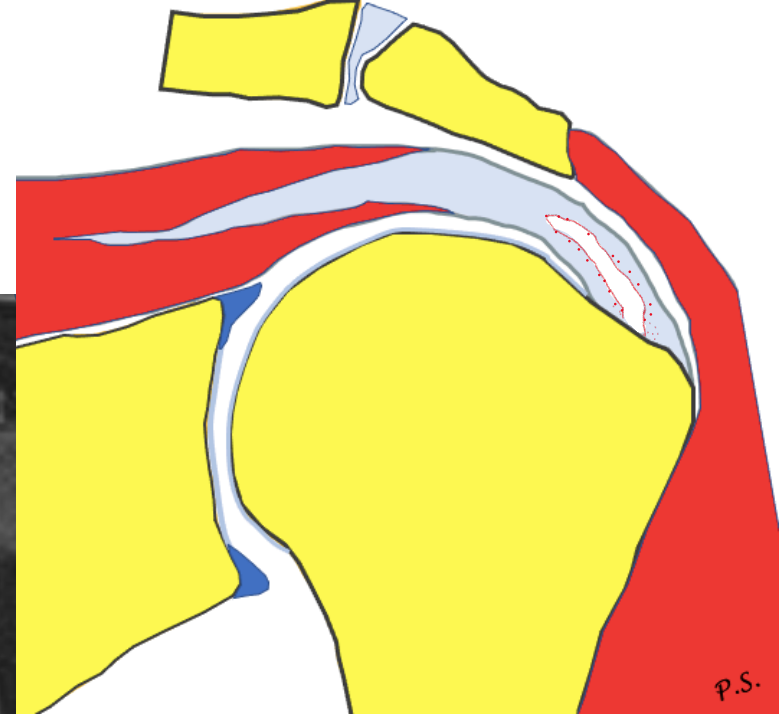

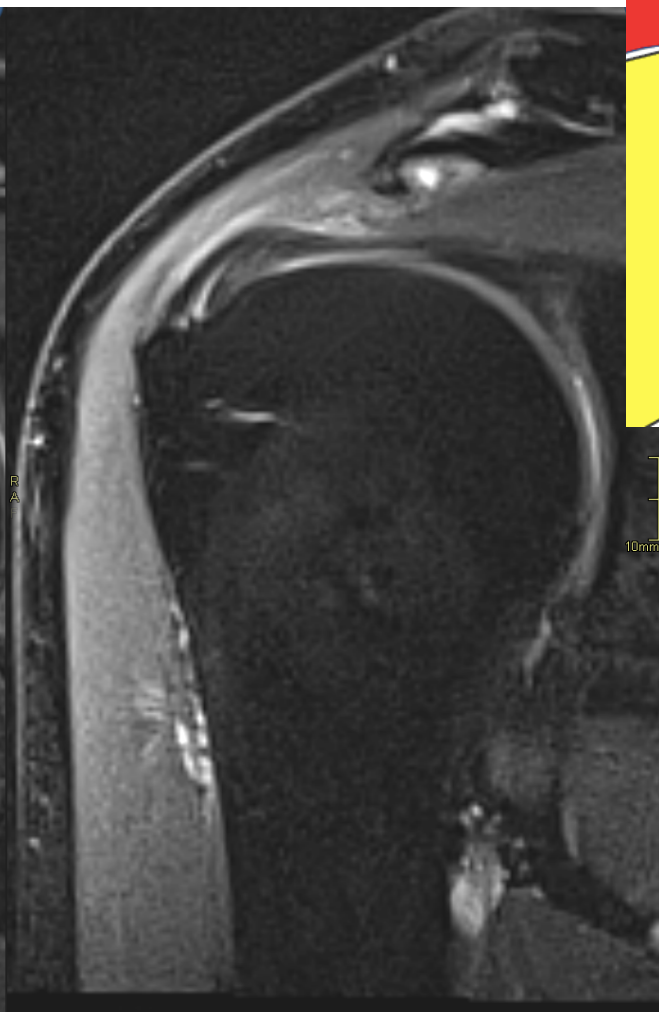
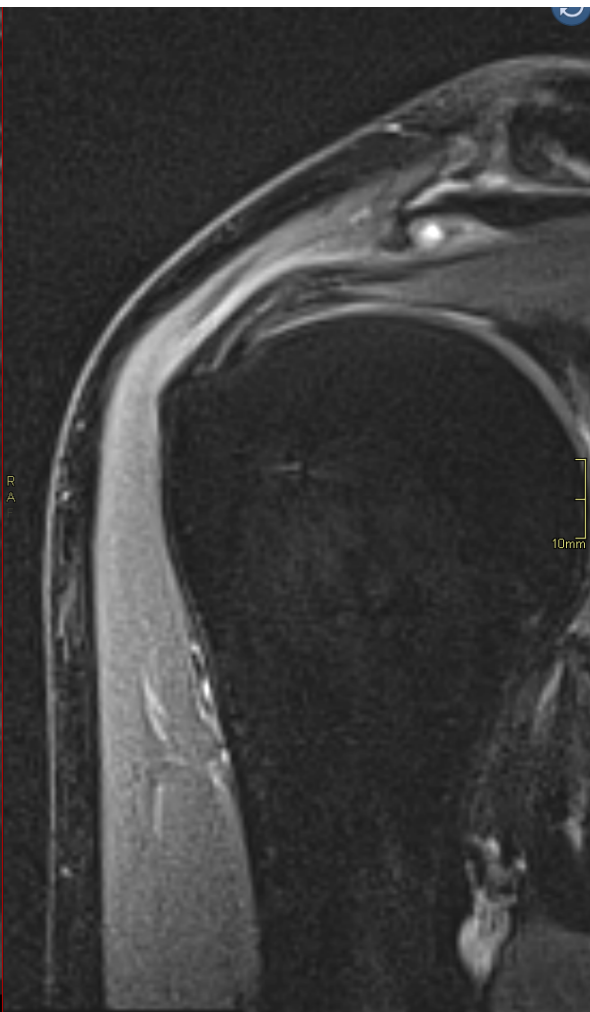
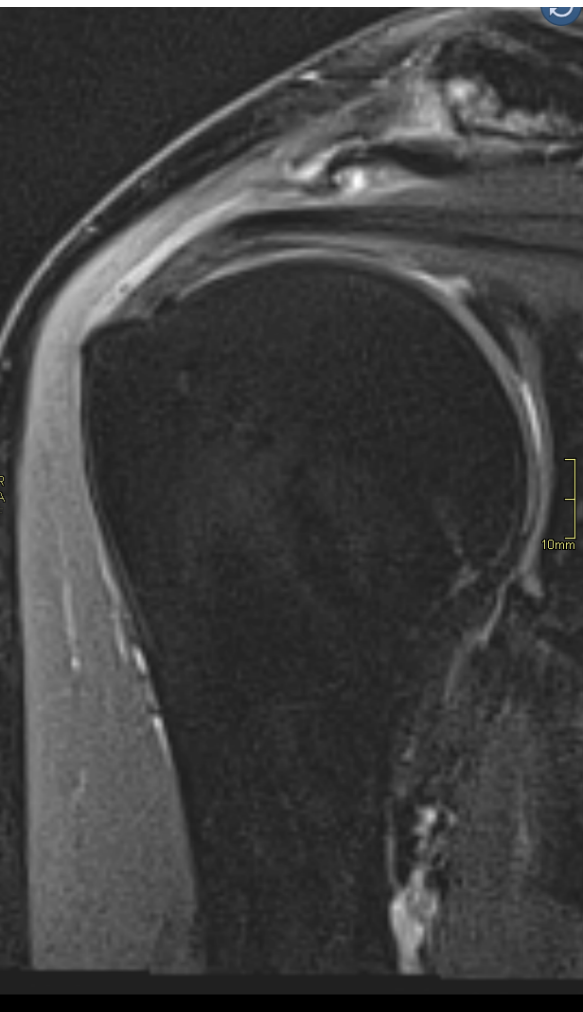
Rupture



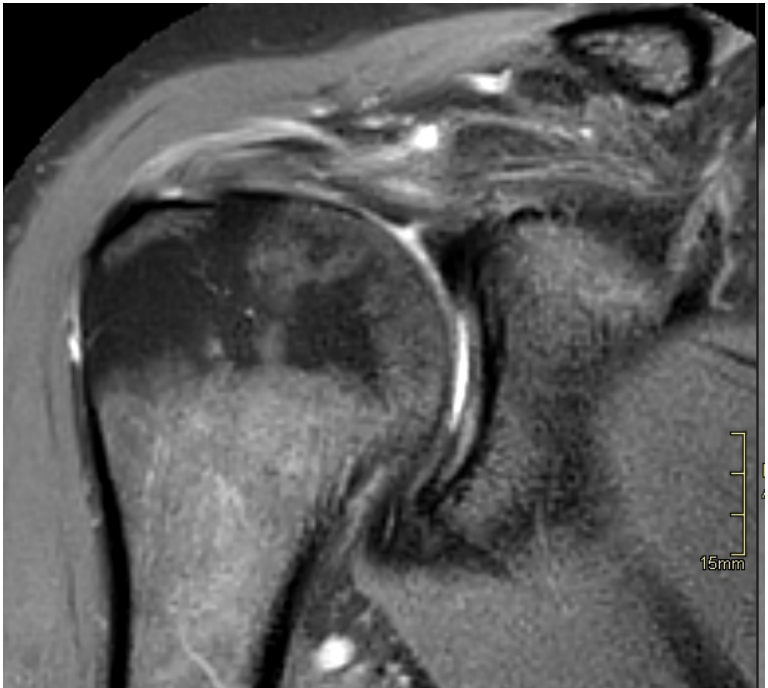
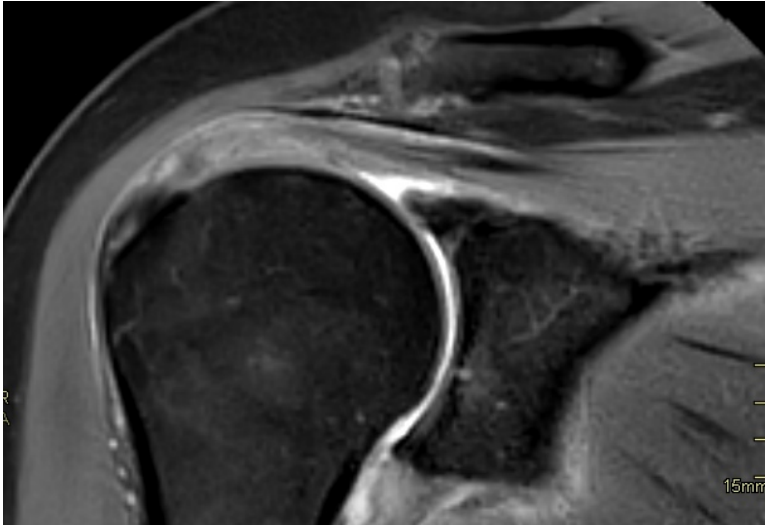
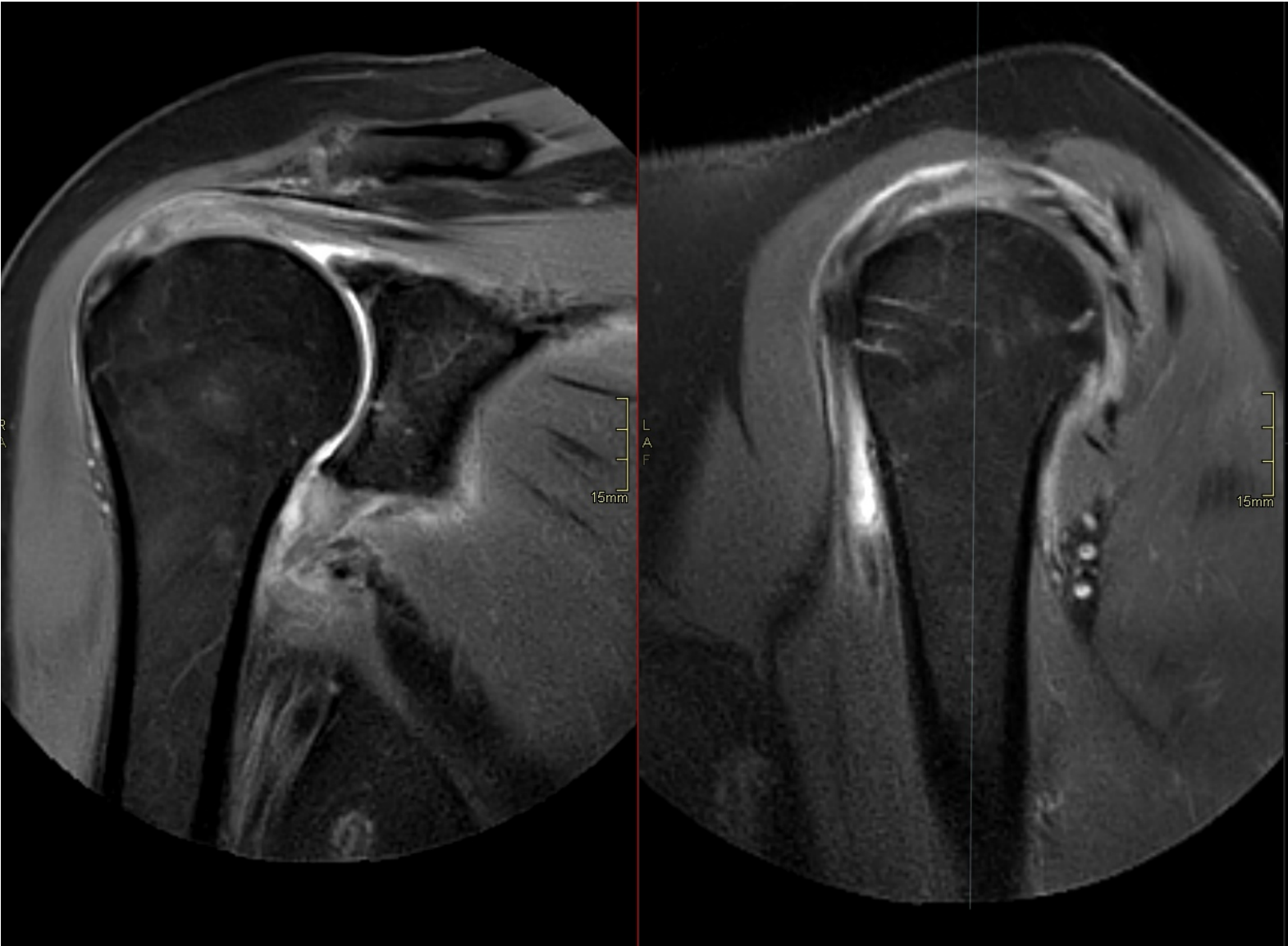
Rupture



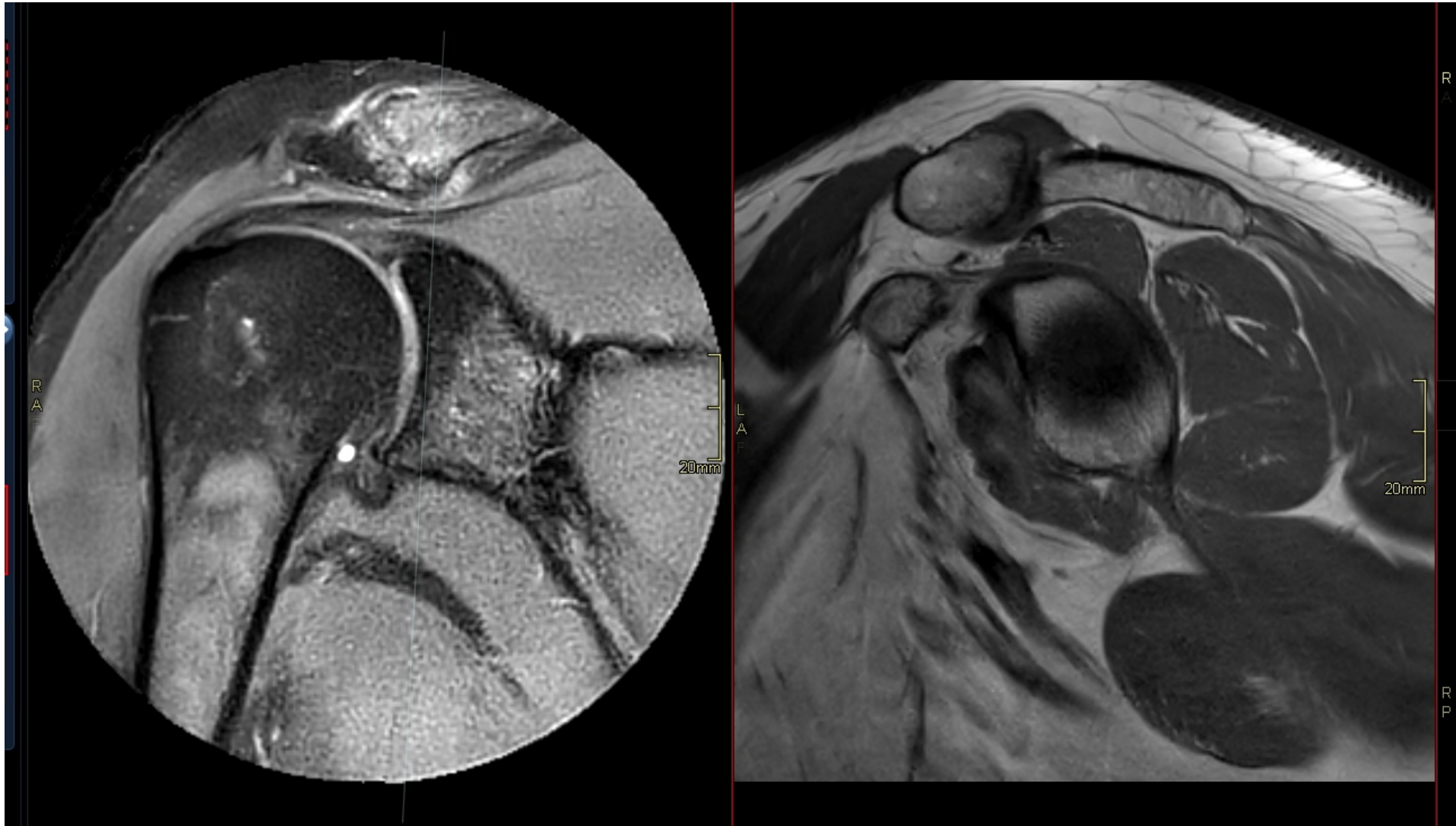
Rupture



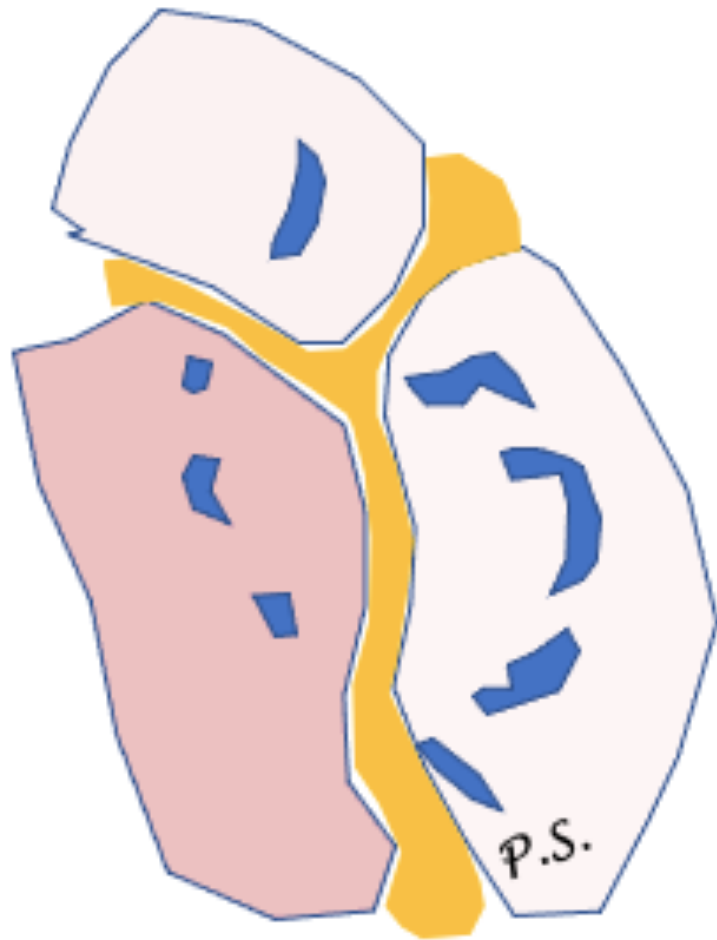
Tendinosis



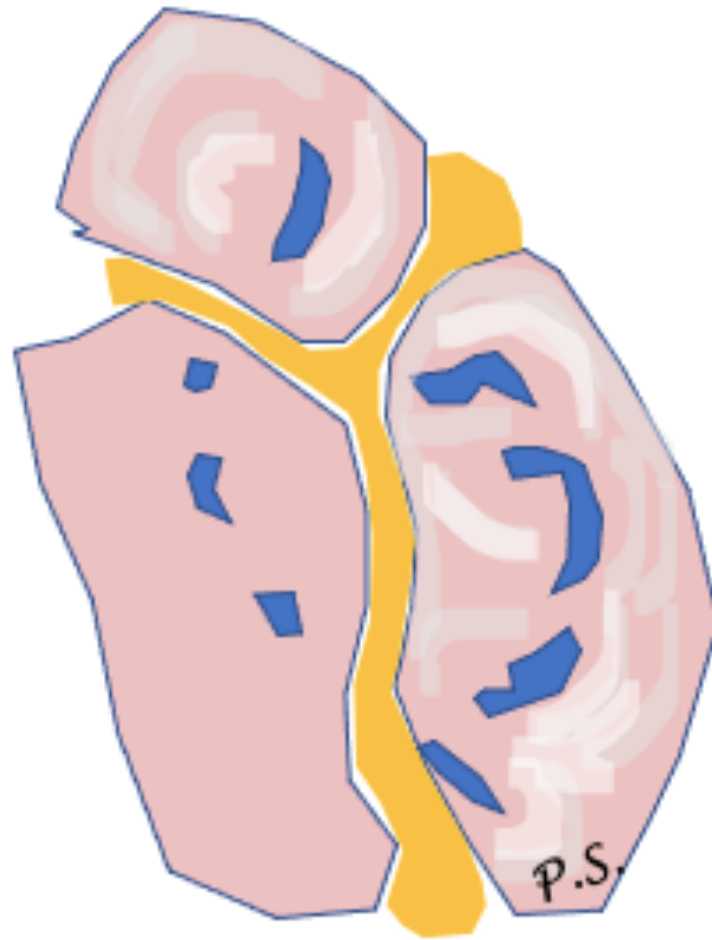
Impingement



Nerve

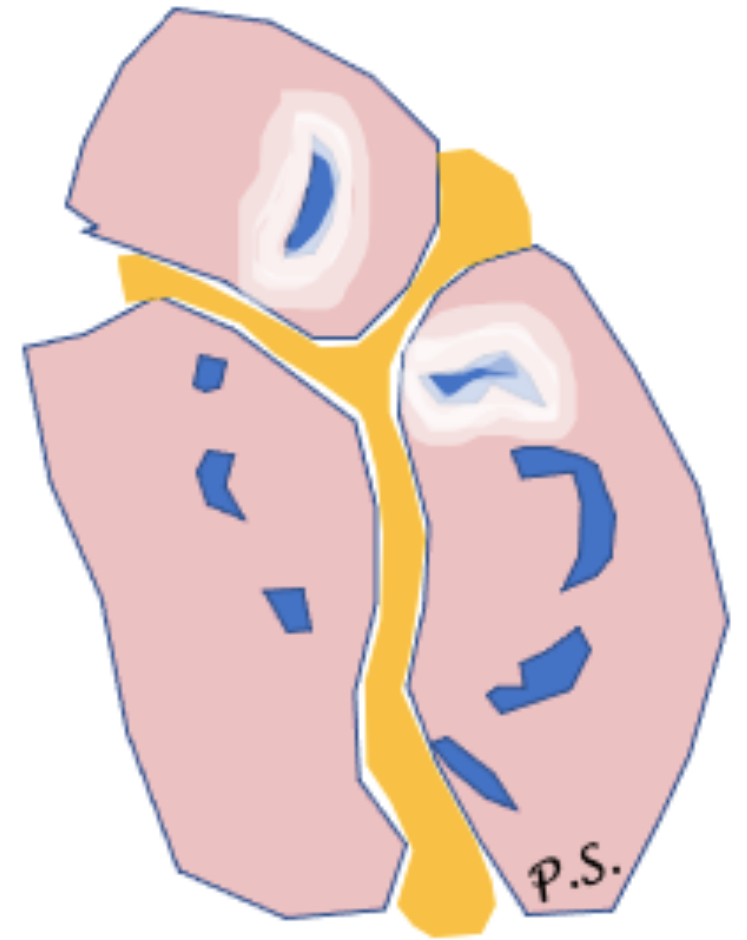


Nerve entrapment



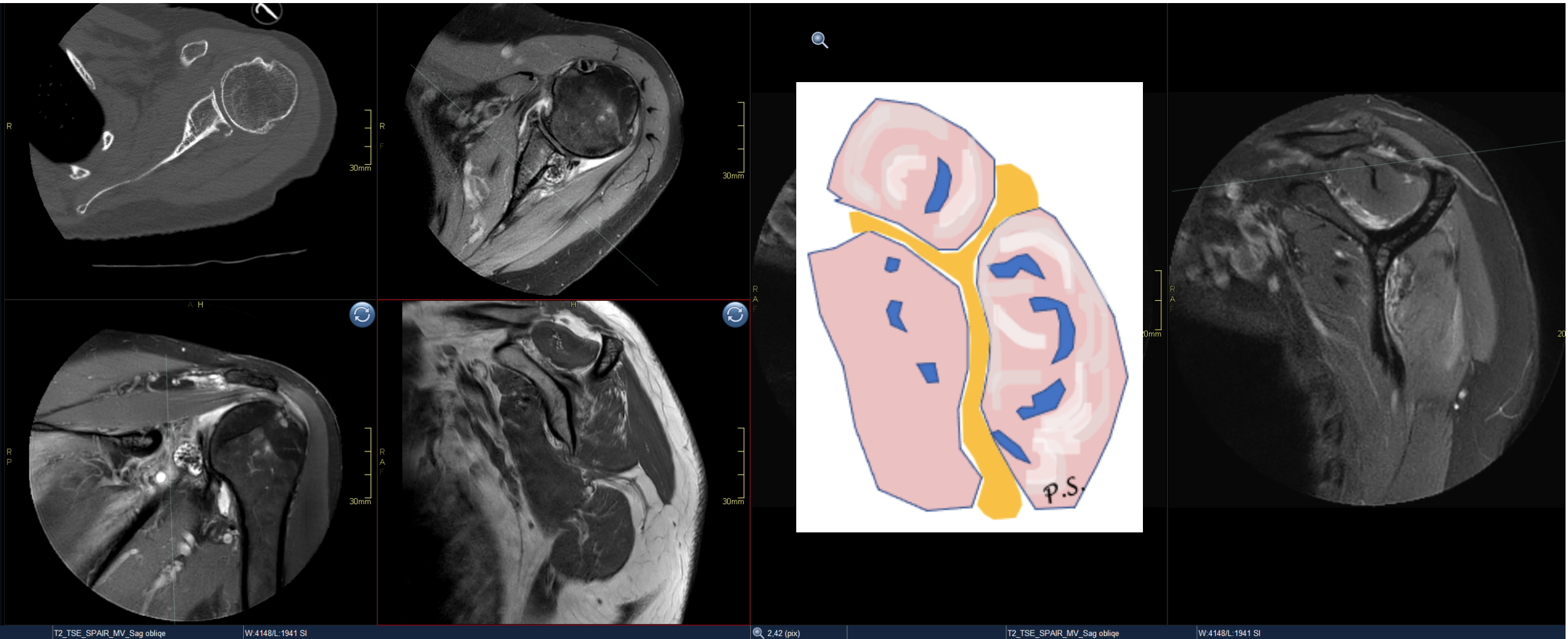
Parsonage-Turner syndrome
(neuritis)

Trauma

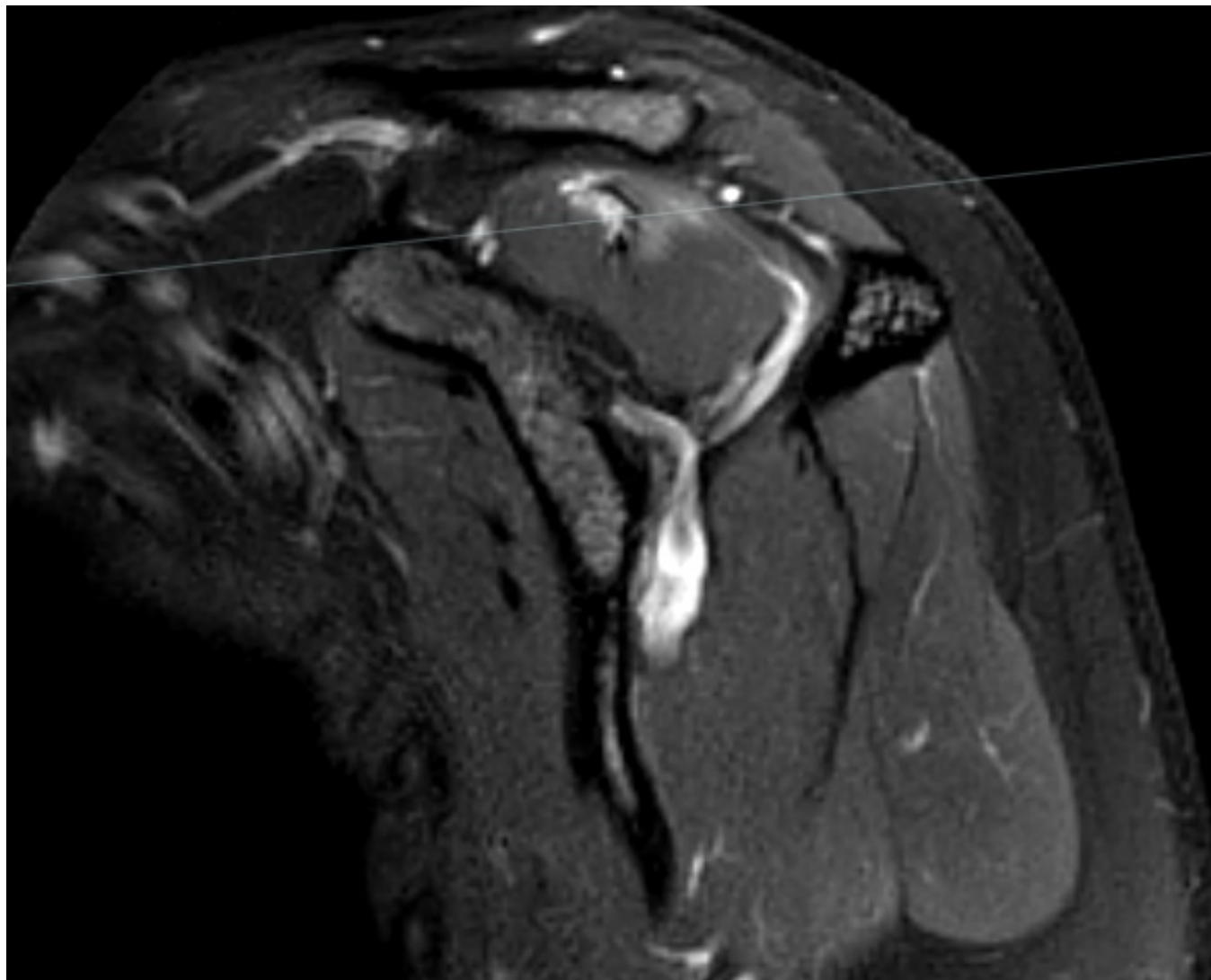
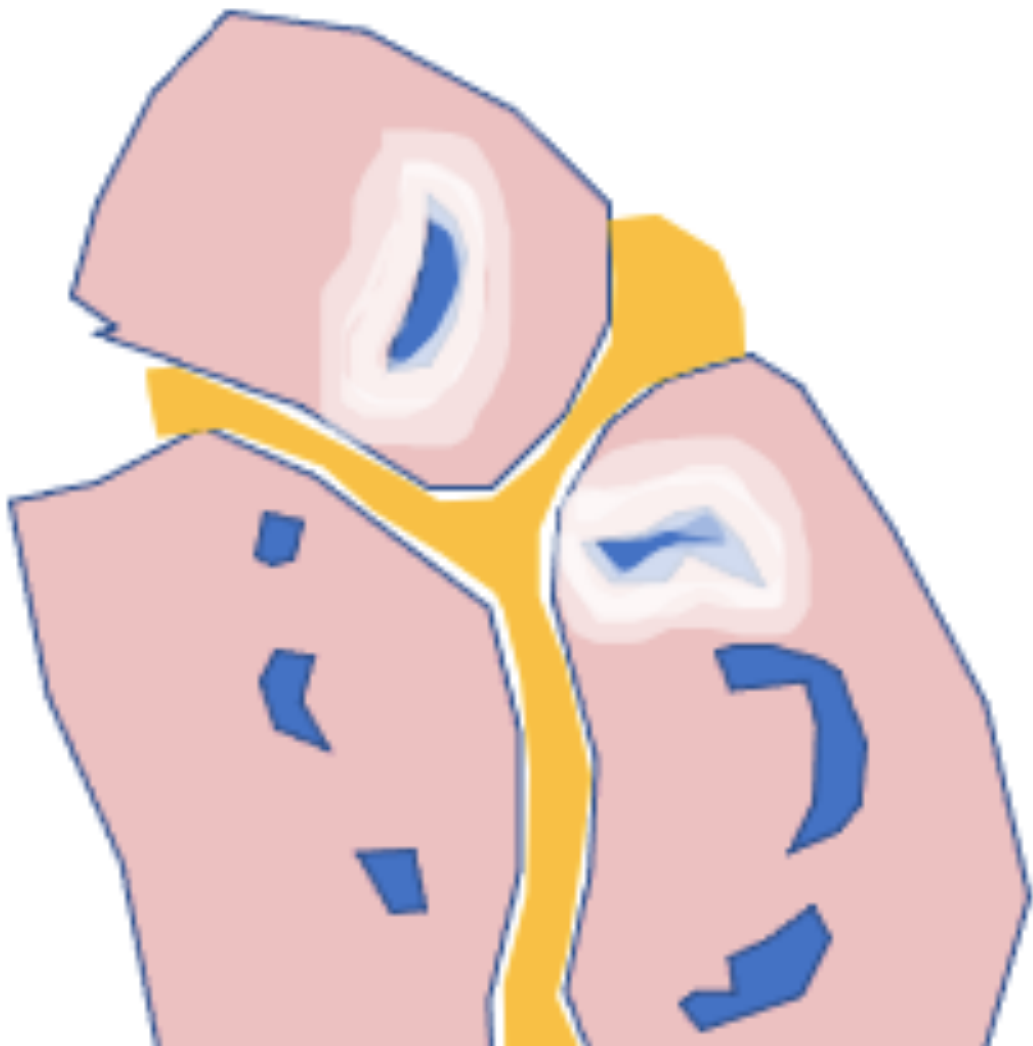


Trauma

Muscle

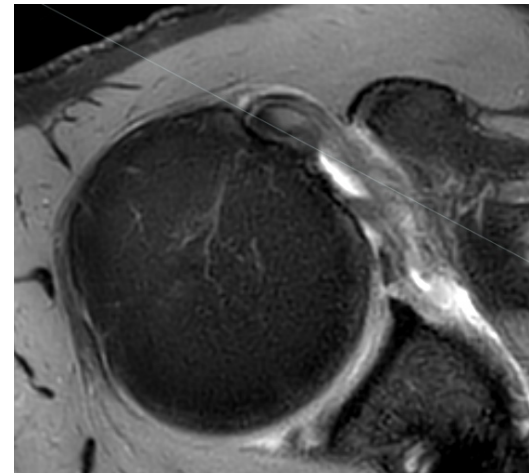
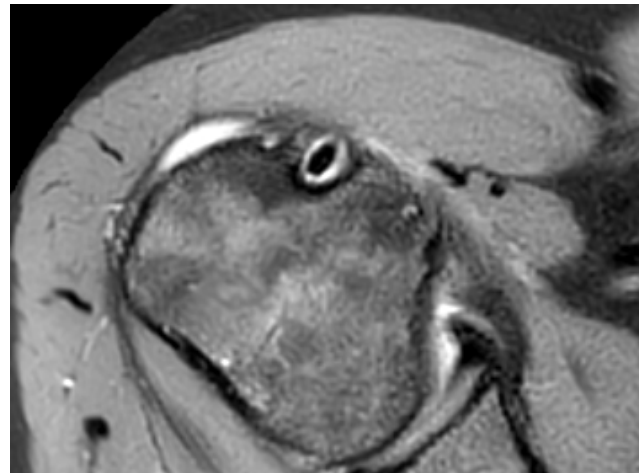
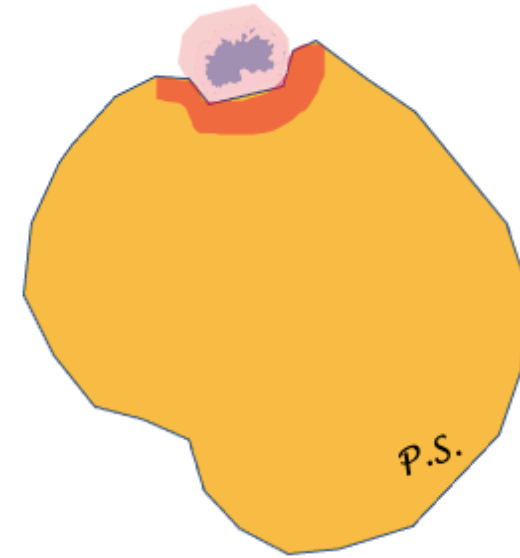
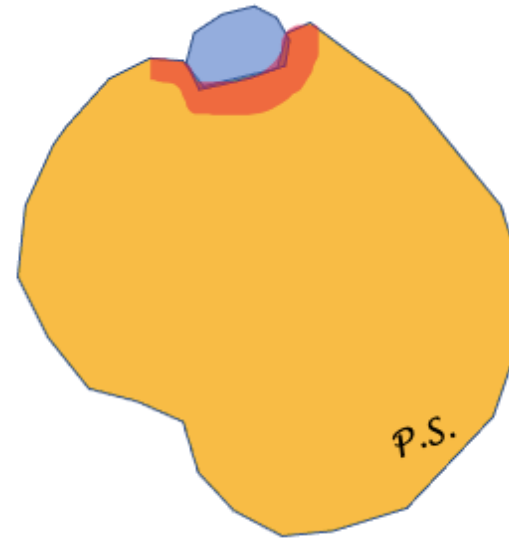
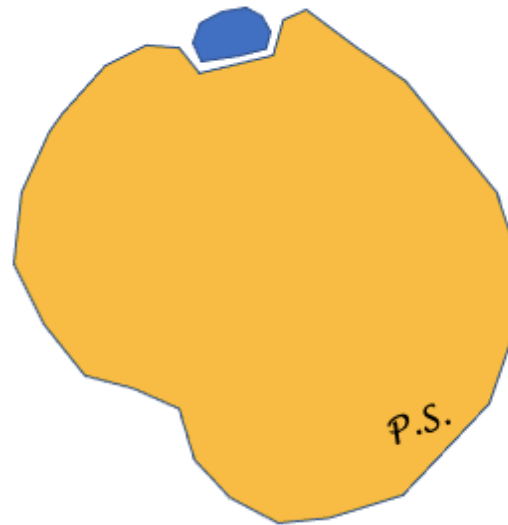


Muscle



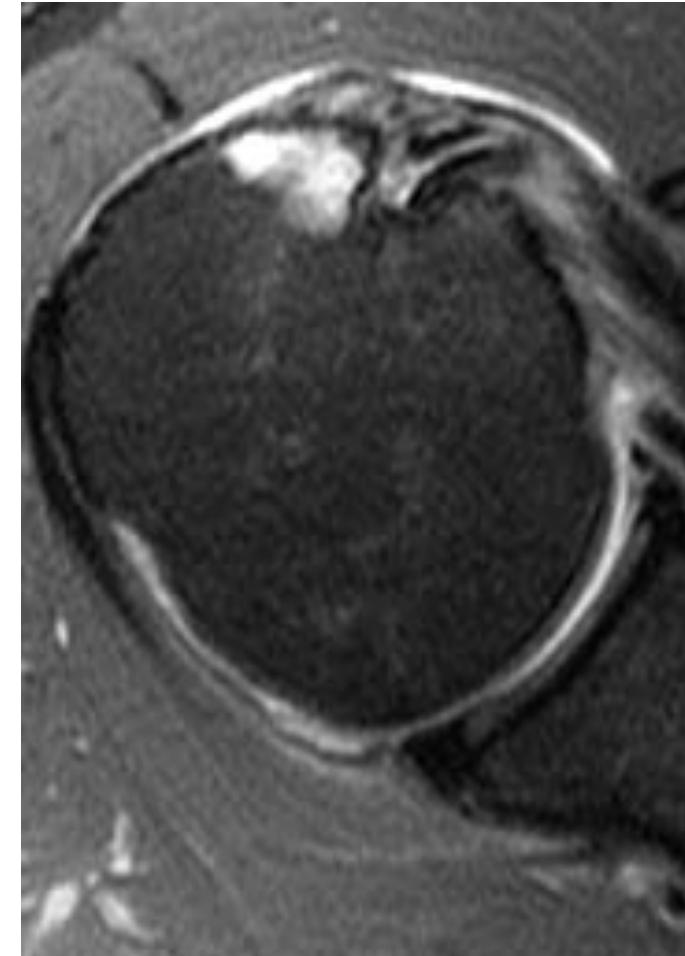
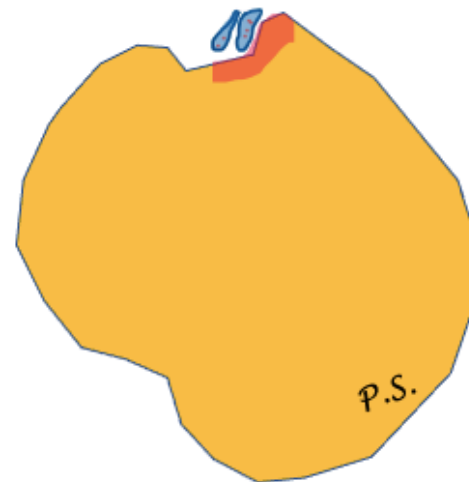
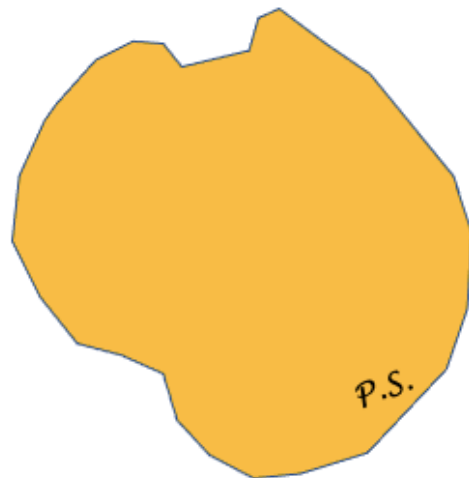
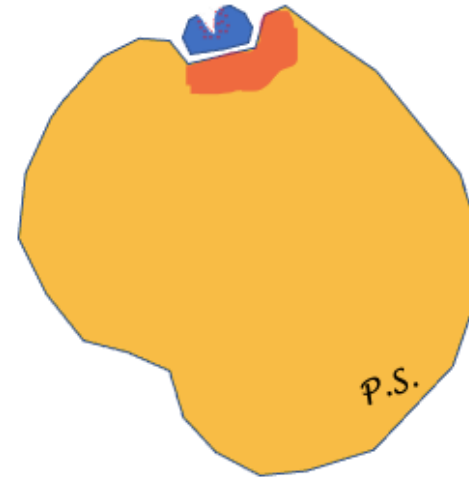
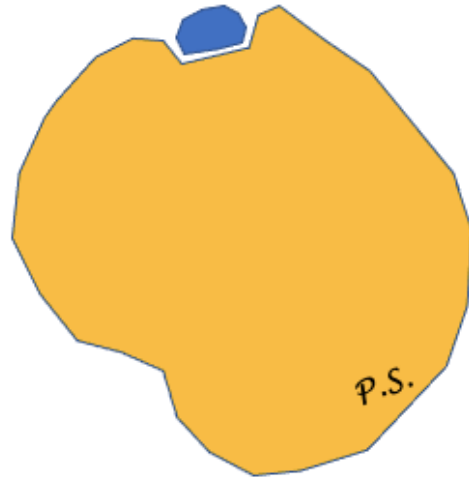
Long head of biceps

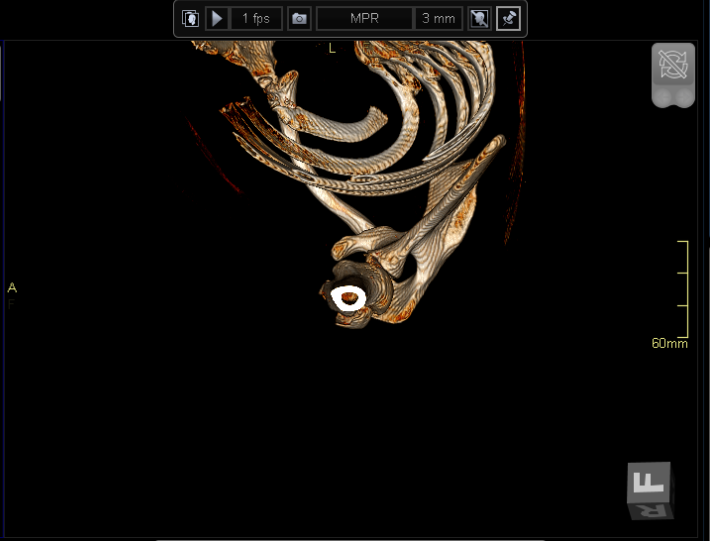
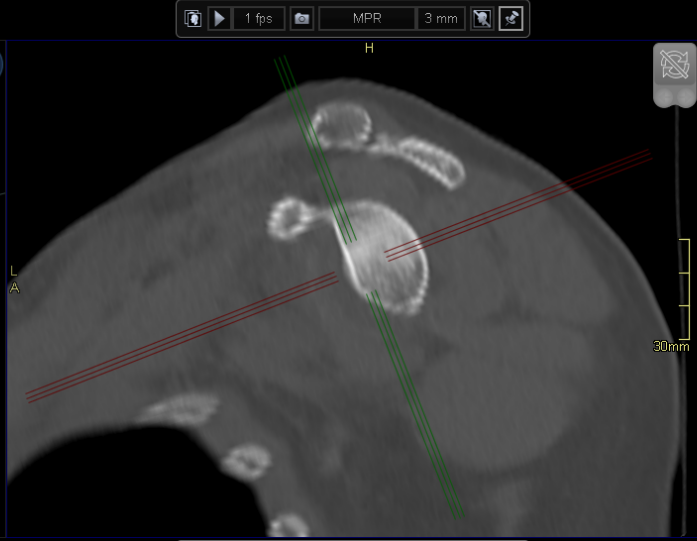
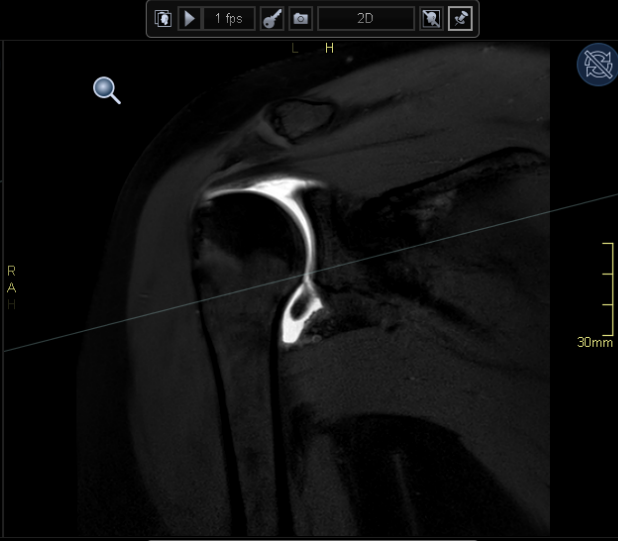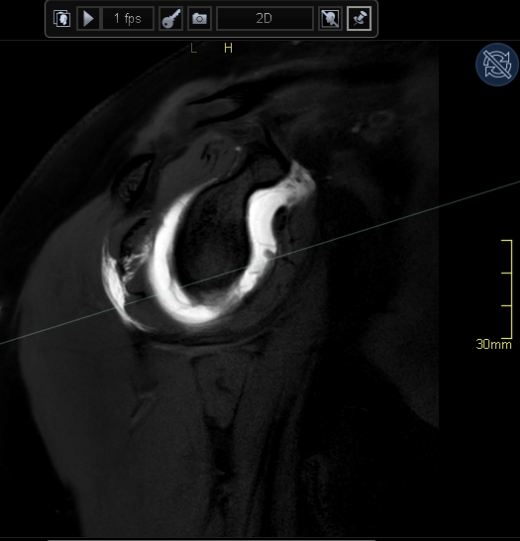
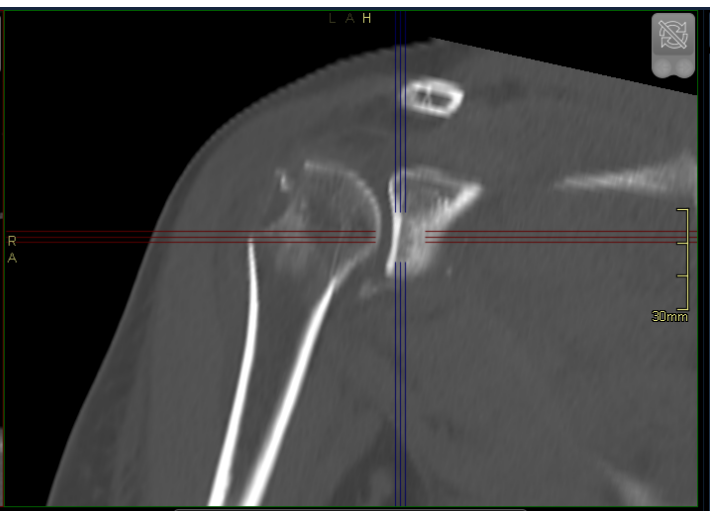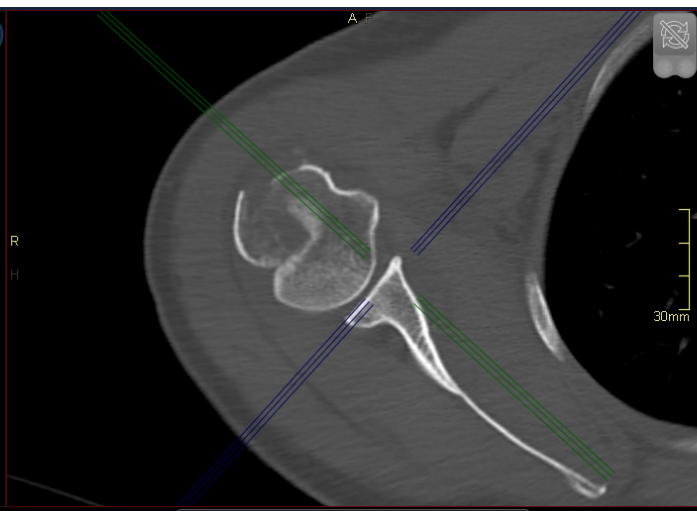
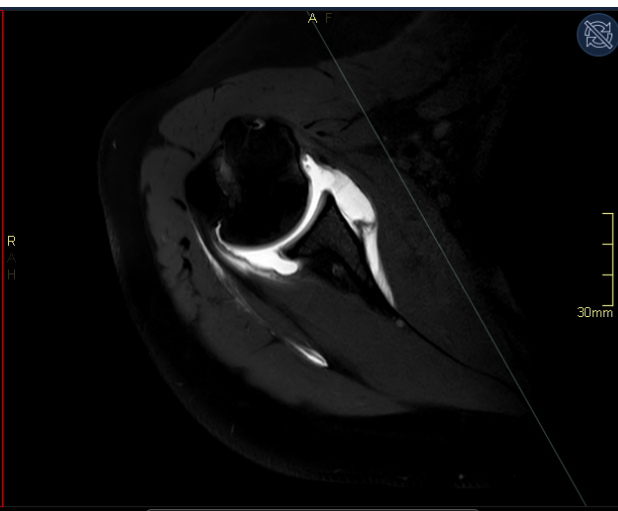
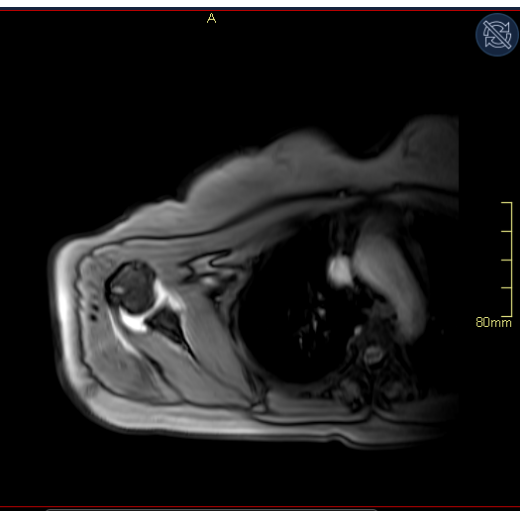
- Tendinopathy
 - Thickening
 - Thinning
- Discontinuity
- absence
- Instability



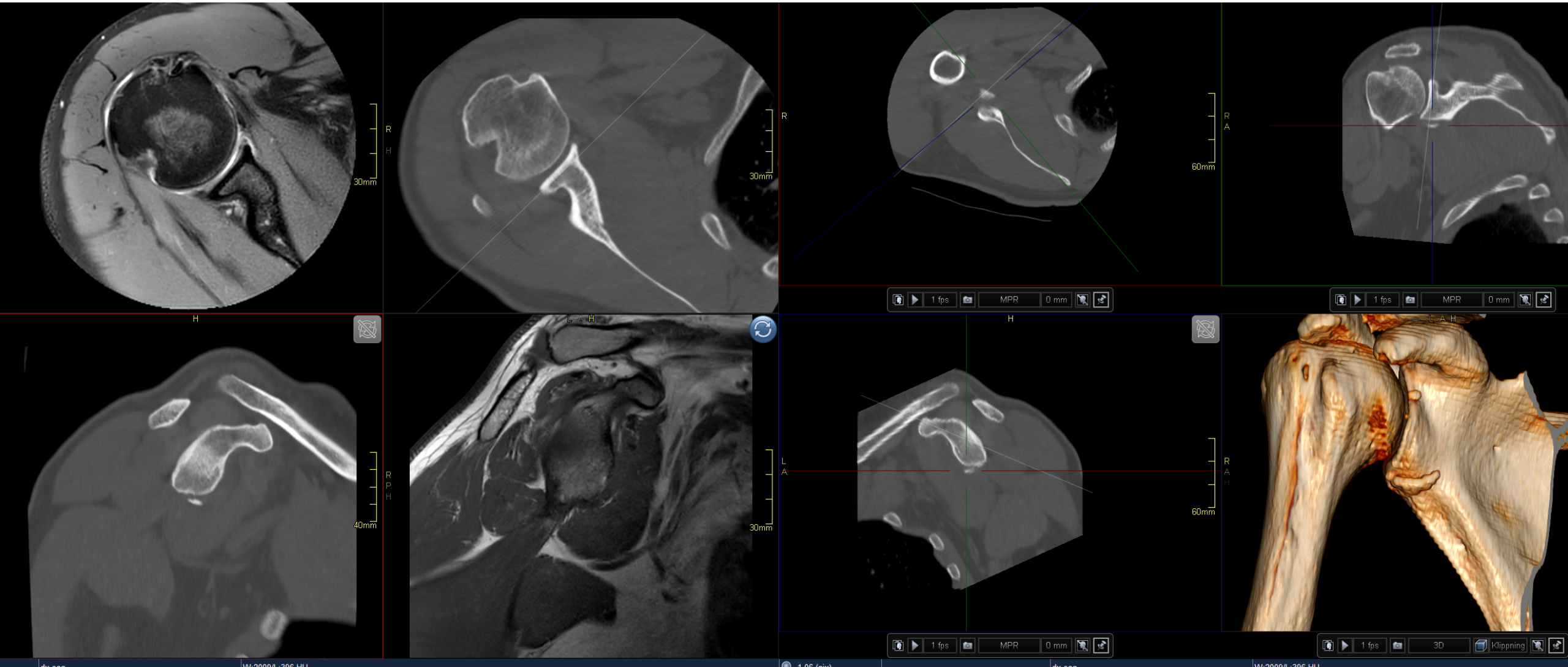
Long head of biceps

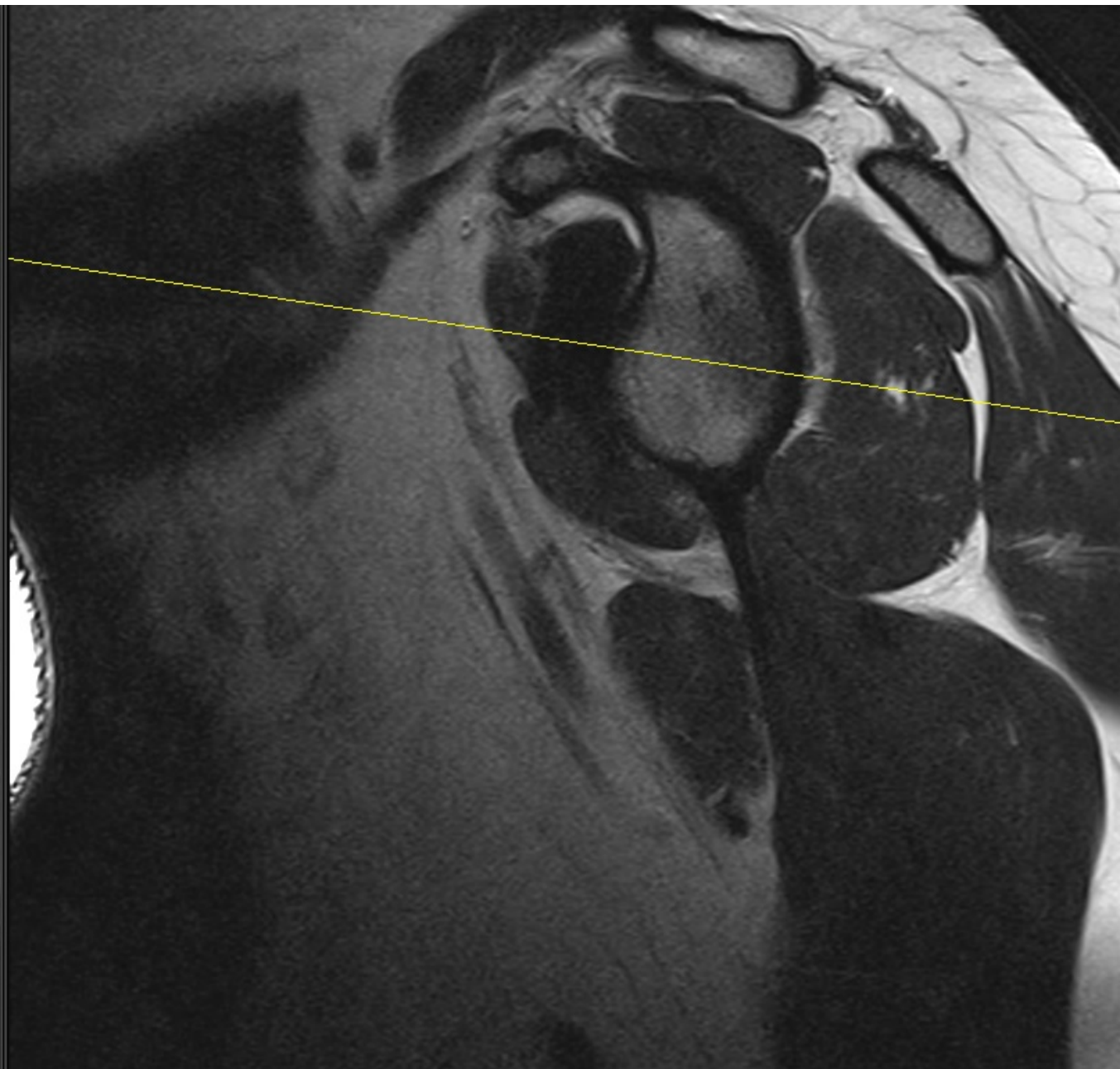
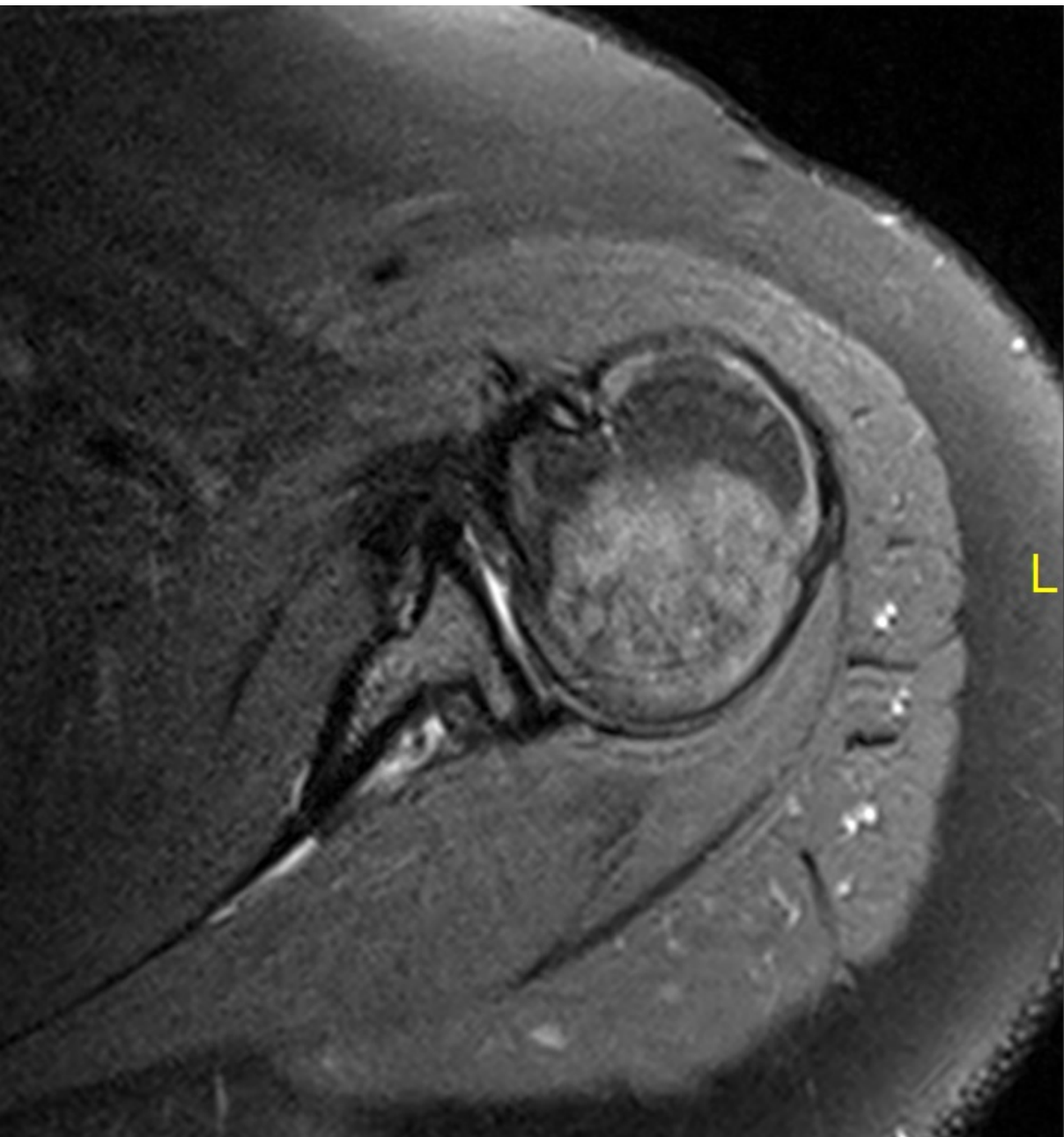
- Tendinopathy
 - Thickening
 - Thinning
- Discontinuity
- Split rupture
- Absence
- Instability





Anterior instability







Tack!

pawel.szaro@gu.se